

C A S E R E P O R T

Rehabilitation management of a triceps surae muscle injury in a young male with haemophilia A and high-titre inhibitors

Antonio Frizziero¹, Paolo Finotti², Cosimo Costantino¹, Samantha Pasca³, Ezio Zanon³

¹ Department of Medicine and Surgery, University of Parma, Parma, Italy; ² Department of Physical and Rehabilitation Medicine, University Hospital of Padua, Padua, Italy; ³ Hemophilia Center, University Hospital of Padua, Padua, Italy

Abstract. *Background:* Haemophilia A is a rare inherited hematologic disorder characterized by a deficit of coagulation factor VIII. It is associated with frequent episodes of musculoskeletal bleedings that occur mainly inside joints and secondly inside muscles. The majority of intramuscular hematomas respond well to conservative protocols, based on rehabilitation techniques and appropriate haemostatic coverage; surgery is limited to refractory cases. *Methods:* This manuscript describes the management of an intramuscular bleeding in a young patient with severe haemophilia A and high-titre inhibitors. A multidisciplinary approach directed by a physiatrist and combining surgical intervention, use of bypassing agents and rehabilitation treatment allowed to successfully manage this case, leading to a complete functional recovery. *Conclusions:* Given the lack of consensus on the treatment of intramuscular bleedings in haemophiliac patients, this case report provides an example of successful management for such conditions, which require a multidisciplinary approach in which the physiatrist plays a key role.

Key Words: haemophilia, intramuscular bleeding, management, rehabilitation.

Introduction

Haemophilia A is a rare inherited hematologic disorder characterized by a deficit of coagulation FVIII. Haemophiliac patients, especially those with a severe form of pathology, suffer from frequent episodes of bleedings. Hematomas are mostly internal and can present spontaneously or after minimal trauma.

Anti-FVIII antibodies develop in 20-30% of patients and make the management of bleedings more complicated, since drug effectiveness is lower in the presence of inhibitor (1).

Between 10 and 23% of musculoskeletal bleeding episodes occur inside muscles, with a high percentage of recurrences; triceps surae, iliopsoas and forearm muscles are the most common targets (2). If untreated,

muscle bleedings can cause complications such as nerve injury, compartment syndrome, myositis ossificans, pseudo-tumour, and even infection (3).

The diagnosis is based on history and clinical examination, usually supported by imaging (ultrasound and magnetic resonance) (4).

The majority of these lesions respond well to conservative and rehabilitation protocols and surgery is limited to a small percentage of patients with severe lesions that fail conservative approaches (5).

In absence of specific guidelines about diagnosis and treatment of muscle injuries in haemophiliac patients, this case report provides an example of successful management for such conditions, in which the physiatrist plays a key role.

Case Report

This manuscript describes the case of a 14-years-old male with severe haemophilia A (FVIII<1%) and high titre inhibitors, managed for an intramuscular bleeding that occurred following low-impact activities.

In absence of a family history for haemorrhagic diseases, diagnosis of haemophilia A was performed at the age of 9 months after an accidental fall causing a hematoma inside the iliopsoas muscle. At the age of 12 months, the child started a treatment with recombinant factor VIII concentrate (octocog-alpha, II generation). One year later, he developed high titre anti-bodies against FVIII. After inhibitors appearance, he presented several haemorrhagic events, both traumatic and spontaneous; therefore, a first immune tolerance induction (ITI) was started with the same recombinant factor VIII (rFVIII) previously used in prophylaxis. Unfortunately, the patient showed a partial response to treatment with an unsatisfactory reduction of the inhibitor titre. For this reason, the child was placed in prophylaxis with rFVIIa at dosage of 90 µg/kg/day for several months. In March 2013, an ITI-Rescue was started with moroctocog alfa at the initial dose of 100 IU/kg/day, subsequently reduced when the inhibitor titre started to decrease.

In July 2016, the subject experimented painless swelling in the right calf after a football friendly match. This episode was initially self-managed with rest, ice and clay wraps.

A few days later, he underwent to clinical and ultrasound examination at the Haemophilia Centre. He was prescribed laser therapy and ITI treatment with rFVIIa. Such approach determined a clinical improvement without complete remission of symptoms.

One month after the first episode, the patient developed marked swelling in the right calf again after a short walk in the mountains. For this reason, he was prescribed a new cycle of laser therapy in association with rFVIIa. Even in that case, there was only a partial clinical improvement.

Twenty days later, the boy experimented a third episode of swelling in the right calf during a walk, this time accompanied by pain. After ultrasound examination, the haematologist prescribed him rFVIIa and laser therapy again, with partial benefit.

Only more than two months after the first acute event, the patient finally arrived to physiatrist observation, without a precise diagnosis on his problem yet. At clinical evaluation, right calf appeared swollen and painful at superficial and deep palpation, without signs of peripheral vascular or nervous deficits. Ultrasound evaluation revealed massive swelling of probable blood origin with fibrous limbs at early stage in the contest of both medial and lateral gastrocnemii (Figure 1).

Therefore, he was recommended to wear an elastic device for 10 days, to put ice on the right calf three times a day (each one for 20 minutes), to use an anti-oedema ointment and to walk with two Canadian

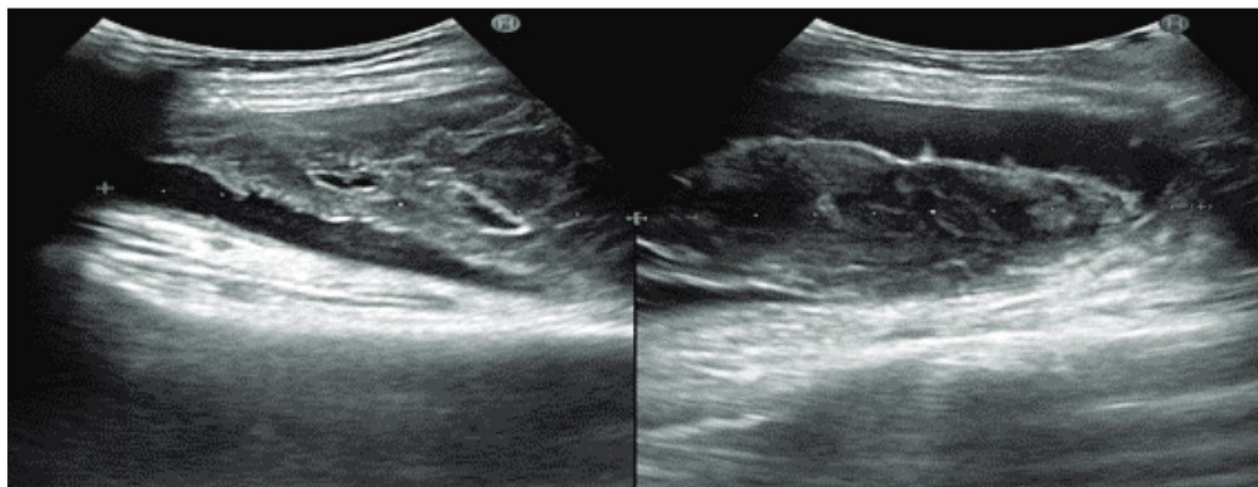


Figure 1: Ultrasound images showing massive swelling in the contest of both medial (*left*) and lateral (*right*) gastrocnemii.

crutches. Moreover, he was prescribed to perform right calf MRI, followed by an orthopaedic evaluation.

According to ISMuLT classification of muscle injuries (6), MRI showed a massive type 4 lesion of the right medial gastrocnemius and a type 3b lesion of the right lateral gastrocnemius. Under the coordination of the physiatrist figure, a multidisciplinary team (also composed of a haematologist and an orthopaedic surgeon expert in the management of musculoskeletal problems in haemophilic patients) discussed and managed the case. The collegial decision was to subject the patient to surgical evacuation of blood supply, followed by an early post-operative rehabilitation. Before surgery, the subject was educated to walk with crutches without weight loading on the right leg in the first post-operative period, waiting for the definition of a more detailed rehabilitative protocol.

Surgical evacuation was performed under haemostatic coverage with rFVIIa; 15 mg of product (200 µg/kg) was administered immediately before intervention, followed by 7 mg (90 µg/kg) three hours later. 15 mg of rFVIIa every 8 hours were then infused for two days. Once discharged, the patient was treated with 15 mg of rFVIIa every 12 hours, in association with FVIII. No thromboembolic complications or adverse events were reported during this treatment.

A few days after surgical intervention, the patient came back to rehabilitation department. At clinical evaluation, he exhibited swelling and oedema in the proximal third of the right calf. Right triceps surae muscle appeared contracted in the proximal region and partially shortened with foot in equine position and deficit of about 30° in ankle dorsiflexion. Moreover, right anterior tibial muscle was hypotonic and the patient referred paraesthesia in the posterior lateral area of the right foot and leg.

A rehabilitation protocol based on clinical evaluation was established. It included right ankle joint mobilizations (especially in dorsiflexion) for complete articular recovery, accompanied by bland stretching of the right triceps surae muscle below pain threshold. Active mobilization exercises for the right ankle were also allowed. Draining massage of right foot and leg

was performed avoiding for the first days the wounded area, where, instead, a disconnecting massage of the scar was performed. Anti-oedema pharmacologic treatment, right leg unloading, compressive device for right leg and contact US therapy in correspondence of the right calf completed the recommended post-operative treatment. Before any physiotherapy session, 90µg/kg of rFVIIa were administered. This treatment was effective in preventing bleedings during the whole physiotherapy pathway.

Two months after surgical intervention, the subject came back for physiatrist examination. Right calf appeared non-oedematous and non-painful at superficial and deep palpation. The superficial scar had deepened for a few millimetres and the movements of the right knee were allowed to the highest degrees, while the dorsiflexion of the right ankle was actively limited to the first degrees because of triceps surae retraction. At ultrasound evaluation (Figure 2), physiatrist observed a collection of likely serum-haematic content of a very small size compared to the previous control, bounded by thick fibrous tissue.

Basing on clinical and instrumental evaluation, the patient was recommended to continue with the previously established rehabilitative protocol, with the addition of massage therapy of the right calf, proprioceptive training and laser therapy in correspondence of the surgical wound.

One month and a half later, the clinical situation appeared very improved with good function and a complete recovery of the range of motion of the right ankle. Therefore, the patient was allowed to do sport like swimming, but avoiding any kind of articular overload and continuing the previously described rehabilitation program.

More than 7 months after surgical intervention, the patient showed no difficulties in walking or going on tips and heels with good tropism of right triceps surae muscle. Ultrasound examination only identified a massive fibrous scar in the context of the right medial gastrocnemius and in the contact area between medial and lateral gastrocnemius. The patient was recommended to perform hydrokinetic therapy and to continue avoiding overloads associated with running and jumping. However, he was allowed to swim and to ride a bike.

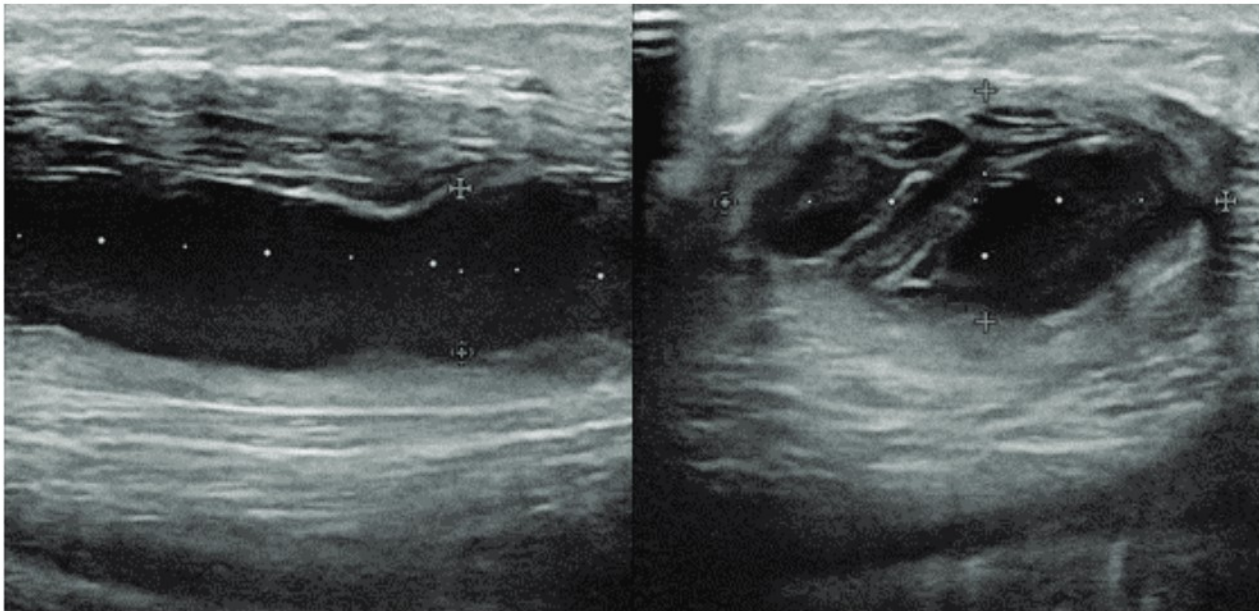


Figure 2. Two months after surgical intervention, ultrasound images showed a collection of likely serum hematic content of a very small size compared to the previous evaluation and bounded by thick fibrous tissue.

Discussion

Together with intra-articular ones, intra-muscular bleedings represent an important cause of disability in haemophiliac patients. Even in healthy subjects, the management of muscle injuries is often difficult; the complexity added by the haemophilic pathology helps to explain the poor literature data in this area, in particular regarding subjects with a severe form of haemophilia A and high titre inhibitor. Indeed, there is still no clear consensus about the management of muscle lesions in haemophiliac patients (2). For all patients prevention represents the best treatment, but once hematoma has verified, therapy must be based on rehabilitation techniques and haemostatic coverage through appropriate infusion of replacement clotting factor(7).

Due to this lack of literature, the case management presented in this manuscript was based on the previous works concerning the diagnosis and the treatment of muscle injuries not only in haemophiliac patients but also in healthy subjects.

In particular, I.S.Mu.L.T. classification and guidelines were used as a reference (6), appropriately adapting them to the specific patient and the characteristics of his pathology.

As recommended by many authors, clinical examination was supported by imaging, represented by US as first level tool, followed by MRI investigation (4). Since a severe structural lesion was identified, the multidisciplinary team considered surgical intervention necessary.

The physiatrist directed preoperative, operative and postoperative management, always interfacing with the haematologist in order to ensure an adequate haemostatic coverage during all the treatment phases. Indeed, this aspect is crucial to avoid complications and to perform an effective rehabilitative protocol in safe conditions.

After surgery, a precise rehabilitation program based on previous literature data was progressively defined. According to Sørensen et al., rehabilitation should be divided into different phases: control of bleeding (phase 1) through POLICE protocol; restoration of range of motion and strength (phase 2); functional rehabilitation and return to normal living activities (phase 3) and eventually recreational activities⁸. As reported by Beeton K et al., rehabilitative strategies include postural correction, progressive mobilization, stretching, muscular strengthening, proprioceptive exercises, physical therapies, hydrokinetic therapy and occupational therapy(9).

Basing on these literature data, in this case report a progressive rehabilitation program was defined and adapted to the clinical and instrumental features that were found at each medical check-up.

In the first post-operative phase, the control of bleeding, oedema and pain was obtained through cryotherapy, right leg unloading with crutches, compressive device for right leg, draining massage of right foot and leg and anti-oedema pharmacologic treatment. The recovery of ankle range of motion was performed through progressive passive and active joint mobilizations accompanied by stretching of the right triceps surae muscle. Subsequently, progressive exercises of muscle strengthening and proprioceptive training were added to the rehabilitative program, finally recommending the patient to perform hydrokinetic therapy and allowing him to do sport like swimming or riding a bike, but avoiding overloads associated with running and jumping.

Within the rehabilitation program, some physical therapies (contact ultrasound and laser therapy) were introduced as they have proven to be effective in reducing pain and promoting reparative processes and healing of the surgical wound (6).

Moreover, a maintenance program is fundamental to obtain a complete recovery and prevent recurrences. The achievement of these objectives has a very important impact not only for the individual quality of life but also for the costs supported by the national health system for hemophilic patients. Indeed, many of the specific drugs for these subjects are extremely expensive and an adequate rehabilitation management for both therapeutic and preventive purposes can reduce their use. In this case, hydrokinetic therapy was recommended as it proved to be a valuable tool for muscle strengthening, tissue elasticity recovery, oedema resorption and muscle relaxation (8). In order to avoid complications or recurrences, all Authors also agree in limiting the spectrum of sports activities allowed to hemophilic subjects. Indeed, while sport represents a fundamental instrument of integration and psychophysical well-being, on the other hand high impact activities should be avoided for the risk of articular and muscular overload. Although there is no common agreement on permitted and avoided recreational activities, sports like rugby or basketball are generally

discouraged, preferring activities such as swimming, yoga and biking instead (10).

Surely, this case report exhibits some limitations. The follow-up period is relatively short and the final recommendations about sport activity and hydrokinetic therapy were not assessed and followed over time. Moreover, this is a unique case, and the conclusions cannot be extended to all hemophilic subjects, given the great heterogeneity of the pathology and the different individual response to the proposed treatments.

Conclusions

Considering the lack of precise rehabilitative protocols for muscular lesions in haemophilic patients, this case report provides an example of successful management for such conditions, emphasizing the key role of the physiatrist in coordinating the treatment plan.

Surely, a prompt diagnosis, a multidisciplinary approach (including different figures such as haematologist, surgeon, physical therapist, etc.) and a timely specific rehabilitation protocol, combining patient education, pharmacological therapy, kinesiotherapy and physical therapies, can allow optimal results and prevent recurrences. However, future research is needed in order to improve current knowledge and define the most effective therapeutic approach.

Conflict of interest: Each Author declares that he or she has no commercial associations (e.g. consultancies, stock ownership, equity interest, patent/licensing arrangement etc.) that might pose a conflict of interest in connection with the submitted article.

References

1. Valentino LA, Hakobyan N, Enockson C, et al. Exploring the biological basis of haemophilic joint disease: experimental studies. *Haemophilia*. 2012 May;18(3):310-8
2. Beyer R, Ingerslev J, Sørensen B. Current practice in the management of muscle haematomas in patients with severe haemophilia. *Haemophilia*. 2010 Nov;16:926-31
3. De la Corte-Rodriguez H, Rodriguez-Merchan EC. Treatment of muscle haematomas in haemophiliacs with special emphasis on percutaneous drainage. *Blood Coagul Fibrinolysis*. 2014 Dec;25(8):787-94
4. Koh ES, McNally EG. Ultrasound of skeletal muscle injury. *Semin Musculoskelet Radiol*. 2007 Jun;11(2):162-73
5. Rodriguez-Merchan EC. Aspects of current management:

- orthopaedic surgery in haemophilia. *Haemophilia*. 2012 Jan;18(1):8-16
6. Maffulli N, Oliva F, Frizziero A, et al. ISMuLT Guidelines for muscle injuries. *Muscles Ligaments Tendons J*. 2014 Feb 24;3(4):241-9
7. Smith TO, Hunt NJ, Wood SJ. The physiotherapy management of muscle haematomas. *Phys Ther Sport*. 2006 Nov;7(4):201-9
8. Sørensen B, Benson GM, Bladen M, et al. Management of muscle haematomas in patients with severe haemophilia in an evidence-poor world. *Haemophilia*. 2012 Jul;18(4):598-606
9. Beeton K, Rodriguez-Merchan EC, Alltree J, Cornwall J. Rehabilitation of muscle dysfunction in hemophilia. *Rev. ed. World Federation of Hemophilia*. 2012. 12 p. (Treatment of Hemophilia; No. 24)
10. Gomis M, Querol F, Gallach JE, Gonzalez LM, Aznar JA. Exercise and sport in the treatment of haemophilic patients: a systematic review. *Haemophilia*. 2009 Jan;15(1):43-54

Arrived: 19 November 2020

Accepted: 19 November 2020

Correspondence:

Antonio Frizziero, MD, PhD

Department of Medicine and Surgery, University of Parma,

Via Gramsci 14, 43126, Parma, Italy;

Phone +39 3492202338;

Email: antonio.frizziero@unipr.it