UNIVERSITÀ DI PARMA
ARCHIVIO DELLA RICERCA

University of Parma Research Repository

The Geriatric Patient: The Ideal One for Chest Ultrasonography? A Review From the Chest Ultrasound in the Elderly Study Group (GRETA) of the Italian Society of Gerontology and Geriatrics (SIGG)

This is the peer reviewd version of the followng article:

Original
The Geriatric Patient: The Ideal One for Chest Ultrasonography? A Review From the Chest Ultrasound in the Elderly Study Group (GRETA) of the Italian Society of Gerontology and Geriatrics (SIGG) / Ticinesi, Andrea; Scarlata, Simone; Nouvenne, Antonio; Lauretani, Fulvio; Incalzi, Raffaele Antonelli; Ungar, Andrea. - In: JOURNAL OF THE AMERICAN MEDICAL DIRECTORS ASSOCIATION. - ISSN 1525-8610. - 21:4(2020), pp. 447-454. [10.1016/j.jamda.2019.06.018]

Availability:
This version is available at: 11381/2862393 since: 2022-01-07T17:32:24Z

Publisher:
Elsevier Inc.

Published
DOI:10.1016/j.jamda.2019.06.018

Terms of use:

Anyone can freely access the full text of works made available as "Open Access". Works made available

Publisher copyright

note finali coverpage

(Article begins on next page)

12 October 2024

Elsevier Editorial System(tm) for JAMDA
Manuscript Draft

Manuscript Number: JAMDA-D-19-00128R1

Title: The geriatric patient: the ideal one for chest ultrasound? A review from the Chest Ultrasound in the Elderly Study Group (GRETA) of the Italian Society of Gerontology and Geriatrics (SIGG)

Article Type: Special Article

Section/Category:

Keywords: lung ultrasound; point-of-care; respiratory diseases; diagnostic accuracy

Corresponding Author: Dr. Andrea Ticinesi, M.D., Ph.D.

Corresponding Author's Institution: University of Parma

First Author: Andrea Ticinesi, M.D., Ph.D.

Order of Authors: Andrea Ticinesi, M.D., Ph.D.; Simone Scarlata; Antonio Nouvenne; Fulvio Lauretani; Raffaele Antonelli Incalzi; Andrea Ungar

Manuscript Region of Origin: ITALY

Abstract: Objectives- To investigate on the current evidence on the use of point-of-care chest ultrasound in older patients and geriatric settings, and present the current state-of-art of chest ultrasound applications.
Design- Special article based on a literature review with narrative analyses, and expert clinical knowledge.
Setting and participants- All studies performed in a geriatric setting were included. Observational and intervention studies and meta-analyses including participants aged ≥70 were also considered, even if not specifically focused on a geriatric setting.
Measures- Data on participant characteristics, diagnostic accuracy of chest ultrasound and outcomes were collected for each considered study. Data were analyzed and discussed with a particular focus on the possible applications and advantages of chest ultrasound in geriatric medicine, underlining the possible areas of future research.
Results- We found only five studies on the diagnostic accuracy and prognostic relevance of chest ultrasonography in geriatrics. However, several studies performed in Emergency Departments, Intensive Care Units and internal medicine wards, included a large number of participants over 70 years old; they suggest that chest ultrasonography may represent a valid aid to the diagnostics of acute dyspnea, pneumonia, acute heart failure, pneumothorax, and pleural diseases, with an accuracy in some cases superior to standard X-rays, especially when mobility-limitation is present. Diaphragm ultrasound may also represent a valid tool to guide mechanical ventilation weaning in older patients with acute respiratory failure.
Conclusions and Implications- Chest ultrasound may represent a valid bedside diagnostic aid to the management of acute respiratory diseases in older patients. However, specific evidence is lacking for geriatric patients. Future research will need to focus on defining the reference

standards and the diagnostic accuracy for frail and multimorbid elderly patients, cost/efficacy and cost/effectiveness of the technique, its impact for clinical outcomes and role for follow-up in the post-acute care.

Letter
Click here to download Letter: Cover letter.docx

Parma, 16th May 2019

Dear Editor,

I am submitting to Your attention the revised version of the manuscript entitled "**The geriatric patient: the ideal one for chest ultrasound? A review from the Chest Ultrasound in the Elderly Study Group (GRETA) of the Italian Society of Gerontology and Geriatrics (SIGG)"** for consideration of publication in ***Journal of the American Medical Directors' Association*** as a Special Article (Manuscript Reference Number JAMDA-D-19-00128).

We have read with great interest the reviewers' comments, and are grateful for their important suggestions for improving the quality of the manuscript.

The present version has been consistently and thoroughly revised, in accordance with their comments, to provide a balanced and objective overview of the current literature state-of-the-art on thoracic ultrasound and its possible applications in geriatrics.

Namely, we have moved part of the basic concepts on how to perform thoracic ultrasound to Supplemental Material, discussing more deeply the issues of equipment type and cost, possible applications outside the hospital setting, and level of training needed to reach a sufficient competency. We have also introduced a new Table summarizing the key characteristics and results of chest ultrasound studies performed in patients aged in average 70 years or older, with grading and quality of evidence of each study. Finally, we have expanded the image set: a novel Figure was added to the main text, and a larger number has been provided in Supplemental Material.

We hope that the reviewers and you will consider positively our efforts to improve the quality of the manuscript.

Thank You for your kind attention in our work.

Best regards,

Andrea Ticinesi, M.D. Ph.D.
Dipartimento Medico-Geriatrico-Riabilitativo, Azienda Ospedaliero-Universitaria di Parma
Department of Medicine and Surgery, University of Parma
Via Antonio Gramsci 14, 43126, Parma, Italy
Tel +39 3471845191
Mail: aticinesi@ao.pr.it
ORCID ID: 0000-0001-9171-8592

RESPONSE TO REVIEWERS' COMMENTS

"The geriatric patient: the ideal one for chest ultrasound? A review from the Chest Ultrasound in the Elderly Study Group (GRETA) of the Italian Society of Gerontology and Geriatrics (SIGG)"

ANSWERS TO REVIEWER #1

"The topic is of potential interest but would need modification to appear more balanced, and less like an advertisement for ultrasound."

R: We thank the reviewer for the useful comments and suggestions. We agree that the previous version of the manuscript was too favorable to chest ultrasound implementation in geriatrics, underestimating critical issues. The novel version of the article has been completely and thoroughly revised, avoiding enthusiastic tones and providing a more balanced and objective view of current evidence.

"1. The data on how to do ultrasound should be reduced (eliminate lines 68-77 and Tables 1 and 2). Do, however, say more about the logistics of doing ultrasound with people who are ill, immobilized, and/or in nursing homes or homebound."

R: The paragraph on the ultrasonographic appearance of normal chest has been removed from the new version of the manuscript. Table 2 and Figure 1 (now Table S1 and Figure S1, respectively), providing the same information in a more schematic way, have been transferred to Supplemental Material. We instead left Table 1 in the main text, because we feel that the methodology of examination and its versatility is one of the major points supporting the assumption of the article's title (geriatric patients are the ideal ones for chest ultrasound). This point of view has been clarified also in the text (lines 68-70). Some comments on the logistics of performing ultrasound in immobilized patients, nursing home residents or homebound older subjects have also been added (lines 70-72), in accordance with the suggestion.

"2. Please add data on types of equipment (including cost and reliability/quality)"

R: A novel paragraph has been added, dealing with these topics (lines 73-80). We mainly concentrated on the comparison between standard portable equipment and pocket hand-held equipment, that make it possible to perform chest ultrasonography in virtually any clinical scenario. A recent study comparing standard and pocket ultrasound equipment in geriatric patients has also been mentioned (Fröhlich and colleagues, reference 8). We did not discuss the costs of ultrasound machines because this aspect was beyond the purposes of our article. However, we carefully assessed the cost-effectiveness issue. There is only one study in the scientific literature examining the impact of chest ultrasound on healthcare costs (Zieleskiewicz and colleagues, reference 57). Its results and possible implications for geriatric practice have been discussed in the section on the possible advantages of lung ultrasound in geriatrics (lines 265-268).

“3. Add information on how much training and experience is needed to achieve competency (again with data).”

R: We thank the reviewer for this important suggestion. In the novel version of the article, a paragraph discussing the level of training necessary to reach a sufficient agreement with examinations performed by experienced sonographers has been added (lines 99-104). The scientific literature supports the concept that chest ultrasound is easier and quicker to learn than abdominal ultrasound, at least to solve the most common diagnostic dilemmas.

“4. The paper should focus more on comprehensively reviewing and summarizing the data on the diagnostic accuracy of ultrasound. Additionally, the presentation of data appears selective and instead should identify and show data related to the areas where ultrasound has been shown to be less helpful.

One way to do this would be to create a detailed table that might have these headings (* = requires citation(s):

Diagnosis / ultrasound sign / gold standard / sensitivity * / specificity * / grade of evidence # / differential diagnosis

 # Grading evidence should use an accepted, published method.”

R: We agree with the reviewer that this is a critical point of our manuscript. As said in the article, the systematic literature search did not retrieve results that could be presented in a comprehensive and homogeneous way. Studies on chest ultrasonography were in fact conducted in a wide range of settings and clinical situations, but they hardly ever focused on geriatric patients. Thus, we decided to summarize evidence coming from studies conducted on adult patients (mean age <70 years old), and then focus the discussion on the few studies that enrolled a consistent proportion of older patients (i.e., studies where the mean age of participants was ≥70 years old). In the new version of the manuscript, the key characteristics of these studies have been presented also in a table (Table 3), providing a more balanced view of the areas where ultrasound proved less helpful (such as acute heart failure) and of the limitations of each study. Namely, we introduced grading and quality assessment of each study, following the same methodology as Barth and colleagues (reference 53). The methodology is presented also in Supplemental Material (Table S2 and S3).

“5. A larger set of figures on common diagnostic findings as an appendix would helpful.”

R: In the novel version of the manuscript, a novel figure has been added (Figure 2) to highlight other possible applications of chest ultrasound, and comparing ultrasound with CT images. Moreover, a larger set of figures on common clinical situations (pneumonia, pleural effusion, acute heart failure, atelectasis) has been presented in the Supplemental Material.

“6. With modification it might be best as a special article.”

R: We thank the reviewer for the precious advice, and hope to have improved the quality of the article.

ANSWERS TO REVIEWER #2

"This is an interesting paper and important topic, and one not largely covered in JAMDA; I especially appreciate its clinical relevance. I have only one overriding comment, and many minor comments related to grammar.

Overriding comment: This paper does not meet the bar of a systematic review, and is actually better identified as a special article. I suggest Line 4 indicate that this special article is based on a literature review with narrative analyses, and expert clinical knowledge."

R: We thank the reviewer for appreciation in our work. In the novel version, the article has been consistently revised to improve the quality of the presentation and provide a more balanced view of the possible applications of chest ultrasound in geriatrics. We have also tried to improve the systematic nature of the article introducing a new table (Table 3), where a synthetic overview of chest ultrasound studies, that were conducted in patients with a mean age over 70 years old, is presented. We however agree that the best definition of the article methodology is "literature review with narrative analysis", and have modified the abstract and the main text accordingly (lines 5-6 and 53-60).

"Line 2: Objectives: Add "and present the current state-of-art of chest ultrasound applications."
Please see recommendations for rounding numbers in the Guide for Authors
Line 35: Change "since" to "because"
Line 38: Change "several" to "a great deal of"
Line 42 and elsewhere: Everywhere in your manuscript, after you use the word "this," please be sure a noun follows so that readers are clear regarding your point.
Line 46: Change "also" to "even"
Objective (line 51-53): Omit "on" in "on the current evidence …" Also, you may need a noun after "geriatrics." And, please be more specific regarding what is meant regarding "identify areas of development of the technique."
Line 54: The literature search was "conducted," not "made." Please also briefly summarize the search in the text.
Line 56: "Which," not "whom."
Line 92-93: Please rephrase "while differential diagnosis may result difficult" because the point being made is unclear.
Line 103: Omit "a"
Line 111: Change "in" to "an"
Line 144: Please correct the awkward wording "allowed to reach"
Line 181: Please correct the awkward wording "allowing to spare the prescription of CTs."
Line 190: Please correct the awkward wording "for performing thoracentesis in safety…"
Line 233: Change "Actions" to "Action"
Line 236: Change "systems" to "system"

Line 248: Omit "by operators."
Line 252: Omit "may contribute to." Also, put the word "literature" after "state-of-the-art" (and note the addition of "the" in that phrase).
Line 261: Change the phrase to "state-of-the-art"
Line 292: Omit "an" before "implementation"
Line 293: Omit "the" in "on the reference standards in the elderly"
Line 294: Make "setting" plural
Table 1:
*** Probes: Change "to detect" to "detection of"**
*** Methodology: Change "Small movements of …are allowed to …" to "Allow small movements of …to assure …" Change "Measurement of diaphragm…" to "Measure diaphragm …"**
Table 3:
*** Do not use abbreviations (the table is short enough that abbreviations are not necessary)**
*** Close the parenthesis in the first box"**

R: We thank the reviewer for the accurate check, and apologize for grammatical and typo mistakes. In the novel version, the article has been completely and thoroughly revised in accordance with suggestions. The key information on the literature search strategy have also been added in the main text.

*Title Page (Containing author details)

The geriatric patient: the ideal one for chest ultrasound?

A review from the Chest Ultrasound in the Elderly Study Group (GRETA) of the Italian Society of Gerontology and Geriatrics (SIGG)

Andrea Ticinesi[a,b*], M.D., Ph.D.; Simone Scarlata[c], M.D.; Antonio Nouvenne[a,b], M.D., Ph.D.; Fulvio Lauretani[a,b], M.D., Ph.D.; Raffaele Antonelli Incalzi[c], M.D; Andrea Ungar[d], M.D., Ph.D.

On behalf of the GRETA (Gruppo di Ricerca sull'Ecografia Toracica nell'Anziano) Group of the Italian Society of Gerontology and Geriatrics (SIGG)

[a] Geriatric-Rehabilitation Department, Azienda Ospedaliero-Universitaria di Parma, Parma, Italy

[b] Department of Medicine and Surgery, University of Parma, Parma, Italy

[c] Unit of Geriatrics and Unit of Respiratory Pathophysiology and Thoracic Endoscopy, Campus Bio-Medico University and Teaching Hospital, Rome, Italy

[d] Geriatrics and Intensive Care Unit, Department of Experimental and Clinical Medicine, University of Florence and AOU Careggi, Florence, Italy

Running head: Chest ultrasound in geriatrics

***Corresponding author:** Dr. Andrea Ticinesi, M.D., Ph.D.

Geriatric-Rehabilitation Department, Azienda Ospedaliero-Universitaria di Parma and Department of Medicine and Surgery, University of Parma, Via Antonio Gramsci 14, 43126 Parma (Italy)

e-mail: aticinesi@ao.pr.it; andrea.ticinesi@gmail.com

Tel: +39 0521 703871 – Mobile: +39 3471845191 – Fax +39 0521 702383

Orcid ID: 0000-0001-9171-8592

Abstract word count: 295 - **Main text word count:** 3147

Article summary: The current applications of bedside chest ultrasound in the management of the geriatric patient are critically reviewed in this paper, highlighting that this technique may facilitate the diagnostic process and follow-up of older patients with cardio-respiratory illness.

*Manuscript
Click here to view linked References

ABSTRACT

Objectives- To investigate on the current evidence on the use of point-of-care chest ultrasound in older patients and geriatric settings, and present the current state-of-art of chest ultrasound applications.

Design- Special article based on a literature review with narrative analyses, and expert clinical knowledge.

Setting and participants- All studies performed in a geriatric setting were included. Observational and intervention studies and meta-analyses including participants aged ≥70 were also considered, even if not specifically focused on a geriatric setting.

Measures- Data on participant characteristics, diagnostic accuracy of chest ultrasound and outcomes were collected for each considered study. Data were analyzed and discussed with a particular focus on the possible applications and advantages of chest ultrasound in geriatric medicine, underlining the possible areas of future research.

Results- We found only five studies on the diagnostic accuracy and prognostic relevance of chest ultrasonography in geriatrics. However, several studies performed in Emergency Departments, Intensive Care Units and internal medicine wards, included a large number of participants over 70 years old; they suggest that chest ultrasonography may represent a valid aid to the diagnostics of acute dyspnea, pneumonia, acute heart failure, pneumothorax, and pleural diseases, with an accuracy in some cases superior to standard X-rays, especially when mobility-limitation is present. Diaphragm ultrasound may also represent a valid tool to guide mechanical ventilation weaning in older patients with acute respiratory failure.

Conclusions and Implications- Chest ultrasound may represent a valid bedside diagnostic aid to the management of acute respiratory diseases in older patients. However, specific evidence is lacking for geriatric patients. Future research will need to focus on defining the reference standards and the diagnostic accuracy for frail and multimorbid elderly patients, cost/efficacy and

cost/effectiveness of the technique, its impact for clinical outcomes and role for follow-up in the post-acute care.

Key words: lung ultrasound; point-of-care; respiratory diseases; diagnostic accuracy

INTRODUCTION

In modern medicine, point-of-care ultrasonography has become one of the most popular tools for assisting the diagnostic process in hospitalized patients, as a technologic complement to physical examination and laboratory biomarkers.[1] Although partly dependent on the skills of each operator, it is considered a safe and rapid imaging technique providing responses to several clinical questions directly at the bedside and at the moment of need.[1]

Chest ultrasound is perhaps one of the least expected applications of point-of-care ultrasonography, because respiratory structures, and particularly the lung parenchyma, cannot be directly explored by ultrasounds. In fact, lung parenchyma has a high acoustic impedance preventing the definition of anatomically faithful images.[1] However, ultrasonographic evaluation of the lung may provide a great deal of clinically relevant information in both health and disease, thanks to a simple and highly reproducible semeiotics.[1-3] This technique has entered clinical practice for the diagnosis of respiratory diseases in several settings, ranging from Emergency Departments (EDs) to Intensive Care Units (ICUs) to acute Internal Medicine and Pulmonology wards.[2,3]

Unfortunately, chest ultrasound is not so popular in Geriatric wards. Possible barriers for bedside implementation of this technique may include reduced availability of portable equipment, limited access to specific training courses, perception of ultrasound as a scarcely reproducible examination, especially in subjects with severe mobility-limitations and dementia.

OBJECTIVES AND METHODS

Our aim was to investigate the current evidence on the use of point-of-care chest ultrasound in older patients and geriatric wards, present its current applications and identify areas for future research in the geriatric setting.

A literature search was conducted on PubMed as of December 19th, 2018, using the search strategy reported in the Supplementary Material, that used “chest ultrasound”, “lung ultrasound”, “geriatric” and “older individuals” as the main key words.

The results of the search showed substantial lack of papers with a geriatric focus (16 manuscripts, of which only 5 reporting original data). Thus, we decided to present the current state-of-the-art of chest ultrasound applications in medical patients with a narrative approach, focusing on studies where participants with a mean age ≥70 years old were enrolled and highlighting the points of interest for older patients and applications for geriatric medicine.

CHEST ULTRASOUND METHODOLOGY AND RELATED ISSUES

The recommendations on the best way to perform a bedside chest ultrasound[1] are summarized in Table 1. There are no specific recommendations for geriatric patients in the scientific literature. The main critical issue in older individuals is severe mobility-disability, preventing the patient to maintain the sitting position for the time of the examination. However, some protocols include the possibility of performing ultrasound with the patient lying supine, or with the aid of a second operator, helping the patient to remain seated[4], so that the methodology of examination fits to the patient's motoric performance (Table 1). This versatility represents a consistent advantage of ultrasound, compared to X-ray. It also makes ultrasound an ideal diagnostic tool for low-resource or low-care-intensity settings, including nursing homes and home-based palliative care, because it can be delivered directly at the bedside preventing patient's distress for transfers.[5]

Modern ultrasound equipment is generally portable, making it possible to reach the patient bedside in hospital facilities. Smaller, hand-held pocket-size devices are however becoming increasingly popular, making it possible to perform ultrasound in any clinical scenario. The image quality of these devices is generally considered inferior than standard portable ultrasound, but recent studies report good levels of diagnostic accuracy in ED patients[6] and subjects with interstitial lung disease.[7] Pocket-size ultrasound was compared with standard ultrasound in geriatric patients in only one study.[8] Although not focused only on chest examination, it demonstrated that pocket-size ultrasound performed the same as standard equipment in presence of a pre-test clinical suspicion.[8]

The ultrasonographic appearance of a normal chest is well described in the literature[1-3,9-10], and is summarized in the Supplemental Material (Table S1, Figure S1). In the most common pathological respiratory conditions of elderly patients, such as pneumonia, pleural effusion, pulmonary edema and interstitial lung disease, specific alterations appear on chest ultrasound images, mainly in the form of artifacts[1,10] (Table 2; Figure 1; see also Supplemental Material Figures S2-S9 for a wider set of images). Chest ultrasound can also provide reliable diagnostic signs also for less common conditions, including pneumothorax, lung abscess, lung cancer and pleural mesothelioma (Table 2;

Figure 2; Supplemental Material Figure S10). Although these signs do not always correspond to precise anatomical alterations, they are associated with well-known patho-physiological alterations typical of each disease (Table 2).[1,10]

To make a correct diagnosis, chest ultrasonography requires in many cases an integration of imaging with clinical data. For example, B lines, the main sign associated with "wet lungs" typical of acute heart failure, can be detected also in areas surrounding an isolated alveolar consolidation, such as those seen in pneumonia[11]. In case of thoracic trauma, B lines and consolidation patterns may coexist and indicate a lung contusion. The differential diagnosis of isolated lung consolidations may also be particularly challenging, since they can be associated with pneumonia, cancer, pulmonary embolism or atelectasis. The characterization of consolidations is generally easier when they are positioned in subpleural regions, while deeper lesions are more difficult to detect.[12]

Apart from these critical issues, the achievement of technical competency in lung ultrasound is generally easier and quicker than abdominal ultrasound. Different studies have shown that novice sonographers have a fair to excellent agreement with experienced sonographers in making basic diagnoses after training courses lasting no more than few days.[13-15] Moreover, the inter-operator agreement in ultrasound image obtainment and interpretation is high (≥90%) when the examination is repeated on the same patient by sonographers with different level of experience.[4]

APPLICATIONS OF CHEST ULTRASOUND IN DIFFERENT CLINICAL SITUATIONS

Acute dyspnea and acute respiratory failure

Chest ultrasound has been particularly studied in management of acute dyspnea in the ED, where it can be performed even in the absence of a specific diagnostic question.[16] It has been implemented also in ICUs, for detecting the causes of acute respiratory failure and monitoring the evolution of respiratory conditions.[17]

According to a recent meta-analysis including studies with a high number of older patients, chest ultrasound has very good diagnostic performance in the detection of the most common causes of acute dyspnea in the ED.[16] The pooled Areas Under the Receiver Operating Characteristics (AUROCs) curves were 0.948 for pneumonia, 0.914 for acute heart failure and 0.906 for COPD exacerbations.[16]

In the largest of these studies, chest ultrasound was able to differentiate cardiac vs noncardiac causes of dyspnea with a significantly higher accuracy (sensitivity 97%, specificity 97.4%) than chest X-ray or clinical-anamnestic workup in 1,005 patients with a mean age of 77.[18]

In a group of 130 older patients aged in average 81 years old admitted with acute dyspnea in an internal medicine ward, the diagnostic performance was slightly lower than that reported in other studies (sensitivity 93.8%, specificity 86.1%), though remaining excellent and non-inferior than X-ray.[19] In an ED setting, the diagnostic accuracy of chest ultrasound for differentiating cardiogenic causes of dyspnea in 236 patients with a mean age of 80 was lower than expected (sensitivity 57.7%, specificity 87.9%)[20], indicating that older age may have some negative impact on chest ultrasound diagnostic performance.

Despite these limitations, the implementation of chest ultrasound in the ED implies faster treatment and disposition. In the only randomized trial published to date, 320 patients presenting to the ED with acute dyspnea (mean age 73) received point-of-care ultrasonography vs usual care.[21] Four hours after ED admission, the number of patients with a correct presumptive diagnosis was

significantly higher in the ultrasound group, implying quicker symptom relief and disposition in appropriate care settings.[21]

In critical patients admitted to ICUs, chest ultrasound is a very useful technique also for monitoring fluid repletion in acute circulatory failure, assessing Acute Respiratory Distress Syndrome (ARDS), investigating pneumonia as a possible cause of fever and assisting physicians during invasive maneuvers.[22] Lung ultrasound outperformed chest X-ray in detecting the cause of acute respiratory failure[23] and differentiating cardiogenic acute pulmonary edema from other diseases, including ARDS, in patients under 70 years old.[24] In the only study specifically focused on a geriatric ICU population (51 patients aged from 73 to 91), lung ultrasound was able to recognize the presence of ARDS with a fairly good accuracy (AUROCs 0.783 and 0.902 at the first and third day of stay, respectively), and the diagnostic performance significantly improved when lung ultrasonography was performed in combination with echocardiography (AUROCs 0.924 and 0.956, respectively).[25]

Interestingly, simplified protocols of chest ultrasound assessment (such as the BLUE and FALLS protocols) have been developed in the ICU setting, to overcome the limitations implied by limited patient mobility.[26] Although these limitations are shared also by many geriatric patients outside the ICU, no studies have evaluated the diagnostic performance of these protocols in a geriatric setting.

Pneumonia

In a recent literature meta-analysis, the diagnostic performance of lung ultrasound for detection of pneumonia in ED was optimal (pooled AUROC 0.97).[27] The presence of parenchymal consolidations with dynamic air bronchogram or focal interstitial syndrome at lung ultrasound in patients with compatible clinical signs and symptoms was diagnostic of pneumonia in almost all cases, with very few false negative examinations. In this context, ultrasound exhibits a high concordance with CT[28], and a lower concordance with X-ray findings.[29]

These considerations apply also to patients admitted to medical wards. Two meta-analyses of the existing studies performed in this setting identified a summary AUROC of 0.99 for the diagnosis of

pneumonia,[30,31] while another more recent meta-analysis showed a summary AUROC of 0.90, with ultrasound outperforming X-ray (summary AUROC 0.59).[32] The diagnostic capacity of ultrasound is reduced only in case of deep lesions not involving subpleural plans (8% of pneumonic consolidations detected by CT), as suggested by two studies performed in groups of 342 and 362 adult (mean age <65) internal medicine patients, respectively.[33,34] Once the diagnosis is established, ultrasound may also represent a useful tool for monitoring the resolution of pneumonic infiltrations at follow-up.[33]

Very few investigations have assessed the diagnostic performance of ultrasonography for pneumonia in geriatric patients. In a group of 169 older patients (mean age 83) hospitalized for acute respiratory symptoms, the diagnostic accuracy for pneumonia of ultrasound was significantly higher than that of X-ray (0.90 vs 0.67), and the difference was particularly pronounced in those subjects with frailty and severe mobility-disability.[4]

Acute heart failure

The diagnostic performance of lung ultrasound in detecting acute heart failure has been well demonstrated in ED and ICU settings as superior to that of X-ray, particularly when echocardiography is also performed.[18]

In internal medicine wards, bedside ultrasound can be very useful for monitoring treatment response and modulating diuretic therapy.[35,36] B-lines are in fact expression of extravascular lung water and their number is related to the severity of congestion[37]. Residual B-lines at discharge predict hospital readmission and mortality.[35] During hospital stay, a close ultrasonographic follow-up, with daily or alternate day assessment, can help to adjust diuretic dosage and speed up the discharge time.[36]

Moreover, bedside lung ultrasound can be used to estimate the volemic state and the possible presence of fluid overload. The addition of inferior vena cava ultrasonography can be particularly useful in this context.[36]

Unfortunately, the application of repeated lung ultrasound monitoring in geriatric acute heart failure patients has not been specifically addressed by the existing literature to date. However, lung ultrasound has proven useful in assessing lung congestion in older patients with end-stage renal disease undergoing dialysis[38].

Pneumothorax

In a recent meta-analysis of the literature, lung ultrasound has proven as significantly more sensitive than chest X-ray for the detection of pneumothorax (78.6% vs 39.8%), with similar specificity.[39] The diagnostic accuracy is particularly high for small lesions, that cannot generally be detected by standard X-rays, and would generally require a CT examination for prompt diagnosis.[40] Ultrasound can also help to stage the pneumothorax severity, identifying the percentage of lung collapse or the distance between lung parenchyma and visceral pleura.[41] However, all the existing studies were focused on the detection of traumatic or iatrogenic pneumothorax in critical care, and none was specifically focused on older individuals.

Pleural diseases

The detection and monitoring of pleural effusion is probably the oldest and simplest application of chest ultrasound. Its diagnostic accuracy is very high, especially for mild effusions that cannot be easily detected with X-rays.[42] Additionally, ultrasound is an excellent guide for thoracentesis procedures, limiting the risk of iatrogenic pneumothorax.[42]

Ultrasound can also help to estimate the severity of a pleural effusion. Besides the simple count of intercostal spaces where the effusion can be visualized, more precise methods of assessment have been proposed. The ultrasonographic measurement of the distance from visceral pleura to chest wall, the distance from lung base to apex of diaphragm cupola and the height of the effusion allows the calculation of fluid volume using validated equations.[43] The maximal distance between visceral and parietal pleura can be also used as a proxy of fluid volume.[44] The estimations of fluid volume

obtained using these methods were significantly correlated with the volume obtained by thoracentesis drainage.[45]

Chest ultrasound also exhibited a higher accuracy than X-ray for the detection of complicated effusions, pleural adhesions and exudative effusions.[42,45] Moreover, it exhibited an optimal diagnostic performance also for the detection of parapneumonic effusions, since it can be very helpful also for identifying the parenchymal consolidations.[46]

Unfortunately, none of the existing studies on the ultrasonographic assessment of pleural effusions was specifically focused on older patients.

Recent research has also demonstrated that chest ultrasonography is an excellent tool for the detection of asbestos-related pleural plaques and other small non-malignant lesions, visualized as focal pleural line thickenings.[47,48] The diagnostic accuracy in this field may be even superior to that of CT,[47] and ultrasound may also be useful for the follow-up of lesions detected with CT.[48]

Pulmonary embolism

A meta-analysis showed that chest ultrasound exhibits a good diagnostic accuracy (sensitivity 87%, specificity 81.8%) for pulmonary embolism, though inferior to that of contrast-enhanced CT.[49] Thus, chest ultrasound in pulmonary embolism may represent only a complementary diagnostic test, and not a routine procedure. However, in patients with a clearly positive lung ultrasound examination, the prescription of contrast-enhanced CT could be avoided, reducing costs and radiation exposure, and with definite advantages in subjects with chronic kidney disease.[50]

Diaphragm dysfunction assessment

The assessment of diaphragmatic motion with M-Mode chest ultrasound is a highly reproducible technique that can be easily applied in clinical practice.[51] In a group of elderly (age ≥80) patients admitted with acute respiratory failure to a Chinese ICU and subdued to at least 48 hours of

mechanical ventilation, the M-mode ultrasound-diagnosed diaphragmatic dysfunction was significantly associated with ventilation weaning failure and poor outcomes.[52]

Alternatively, diaphragmatic dysfunction can be assessed with B-mode ultrasound, measuring changes in diaphragm thickness during tidal volume (ΔTdi). In mechanically ventilated patients, this parameter was significantly associated with a longer ICU stay and increased risk of hospital death.[53] In a group of elderly patients (mean age 78) undergoing noninvasive mechanical ventilation (NIV) for acute COPD exacerbation, ΔTdi <20% was the best single clinical parameter to predict NIV failure and adverse outcomes.[54]

GERIATRIC CHEST ULTRASOUND: A CALL FOR ACTION

Overview of results

The results of chest ultrasound studies performed either in a geriatric setting or in a population with mean age ≥70 years old are summarized in Table 3, with their evidence grade and quality ranking, determined according to the methods already used by Barth and colleagues (see also Supplemental Material).[55] Altogether, these studies support the implementation of bedside chest ultrasound in geriatric wards, but their number and quality is too scarce to formulate specific recommendations. Studies focused on older patients and geriatric settings are thus urgently needed.

The possible advantages of chest ultrasound in geriatrics

A number of circumstances indicate that the geriatric patient may represent the ideal recipient of chest ultrasound implementation programs. First, the aging respiratory system is characterized by some peculiarities that make X-rays and, to a lesser extent, CT more difficult to perform and less accurate to interpret even when a respiratory disease is absent.[56] The age-related modifications of lower airways, increases in interstitial connective tissue and reduction of parenchymal vascularization may in fact contribute to define the so-called "dirty chest".[56-58] Ultrasound is influenced by all these phenomena as well, but its diagnostic performance is maintained thanks to its defined semeiotics and the clinical interpretation of signs.

Second, mobility-limitations or reduced capacity to follow instructions due to cognitive impairment represent additional issues in older patients, limiting the quality of chest X-ray or CT scans and reducing their diagnostic accuracy.[59] Ultrasound is only marginally influenced by these factors, exhibiting good performance also in the sickest and in those with severe disability.[4]

Finally, ultrasound is cheaper and safer than traditional imaging examinations, and its routine use optimizes follow-up of critical patients, reducing the number of X-rays and, possibly, CTs, with

lower costs and radiation exposure.[60] This advantage is particularly useful in geriatric patients, who have often a high level of clinical complexity requiring several diagnostic resources.

Areas of development

Although ultrasound images are less influenced by age-related changes in anatomy and physiology of the respiratory system than X-ray, its normal reference standards in healthy older persons are still unclear, and should be carefully studied.

Aging can also affect diaphragmatic structure and function independently of the presence of respiratory diseases. Thus, normative data on this aspect are needed, in order to clarify the usefulness of diaphragmatic ultrasound in clinical practice.

Besides the evaluation of diagnostic accuracy in different clinical situations and settings, other critical points deserving future investigations in older patients may include:

- The effects of multimorbidity, and particulary cardio-respiratory multimorbidity,[61] on ultrasonographic findings in patients with acute respiratory symptoms;
- The diagnostic advantages of combining chest ultrasound with point-of-care echocardiography in the evaluation of acute dyspnea;
- The usefulness of simplified protocols of ultrasonographic evaluations, such as the FALLS and BLUE protocols;[26]
- The role of chest ultrasound in the detection of diaphragm sarcopenia, either isolated or in the context of systemic sarcopenia;
- The cost/efficacy and cost/effectiveness of chest ultrasonography;
- The role of chest ultrasound in the post-acute and long-term follow-up of older patients with cardio-respiratory diseases.

Moreover, the effects of chest ultrasound implementation in clinical practice on patient-related outcomes should be particularly investigated. In this field, education of geriatricians and residents

in geriatrics on point-of-care ultrasound principles could help to improve the quality of care and contribute to improve outcomes.

CONCLUSIONS AND IMPLICATIONS

Chest ultrasound is an easy, accurate and versatile diagnostic tool for the management of acute respiratory symptoms and conditions in many clinical settings, including acute-care hospital wards, nursing homes and community services. However, very few studies have explored this diagnostic technique specifically in a geriatric environment. Even if no evidence-based recommendations on the use of bedside chest ultrasound can be specifically made for geriatric patients, implementation of this technique in geriatric research and practice is desirable, considering the large amount of evidence in younger patients and in different clinical settings.

ACKNOWLEDGEMENTS

Conflict of interest

The authors have nothing to disclose.

Funding

There is no external funding to report for this study.

REFERENCES

1. Volpicelli G, Elbarbary M, Blavais M, et al. International evidence-based recommendations for point-of-care lung ultrasound. Intensive Care Med 2012;35:577-591.
2. Koenig SJ, Narasimhan M, Mayo PH. Thoracic ultrasonography for the pulmonary specialist. Chest 2011;140(5):1332-1341.
3. Zanforlin A, Giannuzzi R, Nardini S, et al. The role of chest ultrasonography in the management of respiratory diseases: document I. Multidiscip Respir Med 2013;8:54.
4. Ticinesi A, Lauretani F, Nouvenne A, et al. Lung ultrasound and chest X-ray for detecting pneumonia in an acute geriatric ward. Medicine 2016;95:27(e4153).
5. Dhamija E, Thulkar S, Bhatnagar S. Utility and potential of bedside ultrasound in palliative care. Indian J Palliat Care 2015;21(2):132-136.
6. Sforza A, Mancusi C, Carlino MV, et al. Diagnostic performance of multi-organ ultrasound with pocket-sized device in the management of acute dyspnea. Cardiovasc Ultrasound 2017;15(1):16.
7. Cogliati C, Antivalle M, Torzillo D, et al. Standard and pocket-size lung ultrasound devices can detect interstitial lung disease in rheumatoid arthritis patients. Rheumatology 2014;53(8):1497-1503.
8. Fröhlich E, Beller K, Muller R, et al. Point of care ultrasound in geriatric patients: prospective evaluation of a portable handheld ultrasound device. Ultraschall Med 2019;in press Apr 26. Doi:10.1055/a-0889-8070.
9. Scarlata S, Mancini D, Laudisio A, et al. Reproducibility and clinical correlates of supine diaphragmatic motion measured by M-mode ultrasonography in healthy volunteers. Respiration 2018;96(3):259-266.
10. Wallbridge P, Steinfort D, Tay TR, et al. Diagnostic chest ultrasound for acute respiratory failure. Resp Med 2018;141:26-36.

11. Dietrich CF, Mathis G, Blavais M, et al. Lung B-line artifacts and their use. J Thorac Dis 2016;8(6):1356-1365.
12. Reissig A, Gramegna A, Aliberti S. The role of lung ultrasound in the diagnosis and follow-up of community-acquired pneumonia. Eur J Intern Med 2012;23:391-397.
13. Mozzini C, Fratta Pasini AM, Garbin U, et al. Lung ultrasound in internal medicine: training and clinical practice. Crit Ultrasound J 2016;8:10.
14. Begot E, Grumann A, Duvoid T, et al. Ultrasonographic identification and semiquantitative assessment of unloculated pleural effusions in critically ill patients by residents after a focused training. Intensive Care Med 2014;40:1475-1480.
15. Andersen GN, Viset A, Mjølstad OC, et al. Feasibility and accuracy of point-of-care pocket-size ultrasonography performed by medical students. BMC Med Educ 2014;14:156.
16. Staub LJ, Mazzali Biscaro RR, Kaszubowski E, et al. Lung ultrasound for the emergency diagnosis of pneumonia, acute heart failure, and exacerbations of chronic obstructive pulmonary disease/asthma in adults: a systematic review and meta-analysis. J Emerg Med 2018; ahead of print Oct 9. Doi: 10.1016/j.jemermed.2018.09.009.
17. Ashton-Cleary DT. Is thoracic ultrasound a viable alternative to conventional imaging in a critical care setting? Br J Anesthesia 2013;111(2):152-160.
18. Pivetta E, Goffi A, Lupia E, et al. Lung ultrasound-implemented diagnosis of acute decompensated heart failure in the ED. A SIMEU multicenter study. Chest 2015;148(1):202-210.
19. Perrone T, Maggi A, Sgarlata C, et al. Lung ultrasound in internal medicine: a bedside help to increase accuracy in the diagnosis of dyspnea. Eur J Intern Med 2017;46:61-65.
20. Sartini S, Frizzi J, Borselli M, et al. Which method is best for an early accurate diagnosis of acute heart failure? Comparison between lung ultrasound, chest X-ray and NT pro-BNP performance: a prospective study. Intern Emerg Med 2017;12:861-869.

21. Laursen CB, Sloth E, Lassen AT, et al. Point-of-care ultrasonography in patients admitted with respiratory symptoms: a single-blind, randomized controlled trial. Lancet Respir Med 2014;2(8):638-646.
22. Lichtenstein D, van Hooland S, Elbers P, et al. Ten good reasons to practice ultrasound in the critical care. Anaesthesiol Intensive Ther 2014;46(5):323-335.
23. Xirouchaki N, Magkanas E, Vaporidi K, et al. Lung ultrasound in critically ill patients: comparison with bedside chest radiography. Intensive Care Med 2011;37:1488-1493.
24. Sekiguchi H, Schenck LA, Horie R, et al. Critical care ultrasonography differentiates ARDS, pulmonary edema, and other causes in the early course of acute hypoxemic respiratory failure. Chest 2015;148(4):912-918.
25. Huang D, Ma H, Xiao Z, et al. Diagnostic value of cardiopulmonary ultrasound in elderly patients with acute respiratory distress syndrome. BMC Pulm Med 2018;18(1):136.
26. Lichtenstein DA. BLUE-protocol and FALLS protocol: two applications of lung ultrasound in the critically ill. Chest 2015;147(6):1659-1670.
27. Orso D, Guglielmo N, Copetti R. Lung ultrasound in diagnosing pneumonia in the emergency department: a systematic review and meta-analysis. Eur J Emerg Med 2018;25(5):312-321.
28. Nazerian P, Volpicelli G, Vanni S, et al. Accuracy of lung ultrasound for the diagnosis of consolidations when compared to chest computed tomography. Am J Emerg Med 2015;33:620-625.
29. Self WH, Courtney DM, McNaughton CD, et al. High discordance of chest X-ray and computed tomography for detection of pulmonary opacities in ED patients: implications for diagnosing pneumonia. Am J Emerg Med 2013;31:401-405.
30. Chavez MA, Shams N, Ellington LE, et al. Lung ultrasound for the diagnosis of pneumonia in adults: a systematic review and meta-analysis. Respir Res 2014;15:50.

31. Hu QJ, Shen YC, Jia LQ, et al. Diagnostic performance of lung ultrasound in the diagnosis of pneumonia: a bivariate meta-analysis. Int J Clin Exp Med 2014;7(1):115-121.
32. Ye X, Xiao H, Chen B, et al. Accuracy of lung ultrasonography versus chest radiography for the diagnosis of adult community-acquired pneumonia: review of the literature and meta-analysis. PLoS One 2014;10(6):e0130066.
33. Reissig A, Copetti R, Mathis G, et al. Lung ultrasound in the diagnosis and follow-up of community-acquired pneumonia: a prospective, multicenter, diagnostic accuracy study. Chest 2012;142(4):965-972.
34. Sperandeo M, Carnevale V, Muscarella S, et al. Clinical application of transthoracic ultrasonography in inpatients with pneumonia. Eur J Clin Invest 2011;41(1):1-7.
35. Cogliati C, Casazza G, Ceriani E, et al. Lung ultrasound and short-term prognosis in heart failure patients. Int J Cardiol 2016;218:104-108.
36. Mozzini C, Di Dio Perna M, Pesce G, et al. Lung ultrasound in internal medicine efficiently drives the management of patients with heart failure and speeds up the discharge time. Intern Emerg Med 2018;13(1):27-33.
37. Picano E, Pellikka PA. Ultrasound of extravascular lung water: a new standard for pulmonary congestion. Eur Heart J 2016;37:2097-2104.
38. Zoccali C, Tripepi R, Torino C, et al. Lung congestion as a risk factor in end-stage renal disease. Blood Purif 2013;36:184-191.
39. Alrajab S, Youssef AM, Akkus NI, et al. Pleural ultrasonography versus chest radiography for the diagnosis of pneumothorax: review of the literature and meta-analysis. Crit Care 2013;17:R208.
40. Lichtenstein DA, Mezière G, Lascols N, et al. Ultrasound diagnosis of occult pneumothorax. Crit Care Med 2005;33(6):1231-1238.
41. Volpicelli G, Boero E, Sverzellati N, et al. Semi-quantification of pneumothorax volume by lung ultrasound. Intensive Care Med 2014;40:1460-1467.

42. Hooper C, Lee YCG, Maskell N. Investigation of a unilateral pleural effusion in adults: British Thoracic Society pleural disease guideline 2010. Thorax 2010;65(Suppl 2):ii4-ii17.
43. Hassan M, Rizk R, Essam H, et al. Validation of equations for pleural effusion volume estimation by ultrasonography. J Ultrasound 2017;20:267-271.
44. Balik M, Plasil P, Waldauf P, et al. Ultrasound estimation of volume of pleural fluid in mechanically ventilated patients. Intensive Care Med 2006;32:318-321.
45. Remérand F, Dellamonica J, Mao Z, et al. Multiplane ultrasound approach to quantify pleural effusion at the bedside. Intensive Care Med 2010;36:656-664.
46. Svigals PZ, Chopra A, Ravenel JG, et al. The accuracy of pleural ultrasonography in diagnosing complicated parapneumonic pleural effusions. Thorax 2017;72(1):94-95.
47. Scarlata S, Finamore P, Giannunzio G, et al. Chest ultrasonography in health surveillance of asbestos related pleural disease. Lung Cancer 2017;111:139-142.
48. Smargiassi A, Pasciuto G, Pedicelli I, et al. Chest ultrasonography in health surveillance of asbestos-related lung diseases. Toxicol Ind Health 2017;33(6):537-546.
49. Squizzato A, Rancan E, Dentali F, et al. Diagnostic accuracy of lung ultrasound for pulmonary embolism: a systematic review and meta-analysis. J Thromb Hemost 2013;11:1269-1278.
50. Koenig S, Chandra S, Alaverdian A, et al. Ultrasound assessment of pulmonary embolism in patients receiving CT pulmonary angiography. Chest 2014;145(4):818-823.
51. Scarlata S, Mancini D, Laudisio A, et al. Reproducibility of diaphragmatic thickness measured by M-mode ultrasonography in healthy volunteers. Respir Physiol Neurobiol 2019;260:58-62.
52. Huang D, Ma H, Zhong W, et al. Using M-mode ultrasonography to assess diaphragm dysfunction and predict the success of mechanical ventilation weaning in elderly patients. J Thorac Dis 2017;9(9):3177-3186.

53. Dubè BP, Dres M, Mayaux J, et al. Ultrasound evaluation of diaphragm function in mechanically ventilated patients: comparison to phrenic stimulation and prognostic implications. Thorax 2017;72:811-818.
54. Marchioni A, Castaniere I, Tonelli R, et al. Ultrasound-assessed diaphragmatic impairment is a predictor of outcomes in patients with acute exacerbation of chronic obstructive pulmonary disease undergoing noninvasive ventilation. Crit Care 2018;22:109.
55. Barth BE, Waligora G, Gaddis GM. Rapid systematic review: age-adjusted D-dimer for ruling out pulmonary embolism. J Emerg Med 2018;55(4):586-592.
56. Occhipinti M, Larici AR, Bonomo L, et al. Aging airways: between normal and disease. A multidimensional diagnostic approach by combining clinical, functional, and imaging data. Aging Dis 2017;8(4):471-485.
57. Bonomo L, Larici AR, Maggi F, et al. Aging and the respiratory system. Radiol Clin N Am 2008;46:685-702.
58. Copley SJ, Wells AU, Hawtin KE, et al. Lung morphology in the elderly: comparative CT study of subjects over 75 years old versus those under 55 years old. Radiology 2009;251:566-573.
59. Basi SK, Marrie TJ, Huang JQ, et al. Patients admitted to hospital with suspected pneumonia and normal chest radiographs: epidemiology, microbiology, and outcomes. Am J Med 2004;117:305-311.
60. Zieleskiewicz L, Cornesse A, Hammad E, et al. Implementation of lung ultrasound in polyvalent intensive care unit: impact on irradiation and medical cost. Anaesth Crit Care Pain Med 2015;34:41-44.
61. Vizioli L, Forti P, Bartoli E, et al. Accuracy of lung ultrasound in patients with acute dyspnea: the influence of age, multimorbidity and cognitive and motor impairment. Ultrasound Med Biol 2017;43(9):1846-1852.

TABLE 1

Summary of the main recommendations, retrieved by the scientific literature and international consensus, on how the bedside chest ultrasound should be performed.

ISSUE	RECOMMENDATIONS
Patient position	- Sitting on the bed side (ideal position) - Maintained in the sitting position by a second operator (for those with severe mobility-disability) - Lying supine on the bed (only for bedridden patients) - Supine position is ideal for diaphragm assessment
Use of probes	- Use both convex 3.5-5 MHz and linear 4-8 mHz probes - Convex probes assure a panoramic view, allow detection of gross lesions and focus on deeper plans - Linear probes assure a careful examination of surface structures (ling-pleura interface, small pleural and subpleural lesions) at the expense of a reduced penetration of ultrasounds into deeper anatomical plans
Ultrasound modality	- Examination of pleura and lungs should be performed in B-mode - M-mode can be useful for a study of the diaphragm
Methodology of examination	- Split each hemithorax into an antero-lateral (from parasternal to posterior axillary lines) and a posterior sector (from posterior axillary to paravertebral lines), and divide each sector into a superior and inferior half - Investigate systematically the four areas of each hemithorax - Put the probe in each intercostal space, perpendicularly, obliquely and in parallel to the course of the ribs - In bedridden patients, limit investigation to the antero-lateral sectors - Allow small movements of rotation and tilting of the probes to assure an optimal visualization of structures - Measure diaphragm thickness, excursion in forced respiration, variation of thickness between end inspiration and expiration

TABLE 2

Overview of the main ultrasonographic signs that can be detected when examining the chest and their correlation with respiratory diseases.

ULTRASOUND SIGN	MOST PROBABLE DIAGNOSIS	DIFFERENTIAL DIAGNOSIS
Hypoechoic space between chest wall and lung (possibly with quadrilater or sinusoid shape, “quad sign” and “sinusoid sign”)	Pleural effusion	Pleural thickening Pleural cancer Intraparenchymal cysts
Absent pleural line sliding	Pneumothorax	Acute Respiratory Distress Syndrome Local fibrosis
Dynamic air bronchogram within a parenchymal hyperechoic consolidation	Pneumonia	Atelectasis Pulmonary infarction Pulmonary contusion Cancer
Increased parenchymal echogenicity with loss of pleural line and hypoechoic vascular structures	Pneumonia	Atelectasis Pulmonary infarction Pulmonary contusion Cancer
Peripheral wedge-shaped consolidation	Pulmonary embolism	Pneumonia Cancer
Static air bronchogram within a parenchymal hyperechoic consolidation	Atelectasis	Pulmonary infarction Pulmonary contusion Cancer
Increased B-lines with a widespread distribution	Cardiogenic pulmonary edema	Acute Respiratory Distress Syndrome Pneumonia Interstitial lung disease
B-lines with focal distribution (focal interstitial syndrome)	Pneumonia	Pulmonary infarction Pulmonary contusion Acute heart failure
Reduced diaphragm thickness and thickening ratio / reduced excursion	Diaphragm dysfunction	Neuromuscular disease Chronic Obstructive Pulmonary Disease Severe focal lung disease (pneumonia, cancer, atelectasis)

TABLE 3

Summary of the results of the main studies on chest ultrasound in which a population with a mean age ≥70 years old was enrolled. Grading and quality of evidence is also provided using the method proposed by Barth et al.[53]

First author, journal, year, [ref]	Setting and design	Number of patients	Mean age	Main outcome	Gold standard	Sensitivity	Specificity	Grade of evidence	Quality of evidence	Key finding
Pivetta, Chest, 2015, [18]	7 EDs, observational	1005	77	Cardiogenic vs other dyspnea	Blind review of medical record	0.97	0.97	C	Adequate	Ultrasound can improve the diagnostic accuracy of acute dyspnea in the ED
Perrone, Eur J Intern Med, 2017, [19]	IM ward, observational	150	81	Cardiogenic vs other dyspnea	Discharge diagnosis	0.94	0.86	C	Poor	Bedside ultrasound improves the diagnostic workup of dyspnea in wards
Sartini, Intern Emerg Med, 2017, [20]	ED, observational	236	80	Cardiogenic vs other dyspnea	Expert review of medical records	0.58	0.88	C	Poor	To diagnose acute heart failure, ultrasound should be integrated with clinical information
Laursen, Lancet Respir Med, 2014, [21]	ED, prospective parallel-group trial	320	73	Assignment to the right treatment for dyspnea	Masked audit on clinical records	NA	NA	B	Good	Ultrasound allows quicker and more appropriate treatment of dyspnea, and faster disposition from ED
Ticinesi, Medicine, 2016, [4]	IM/geriatric ward, observational	169	83	Pneumonia vs other respiratory conditions	Blind review of medical record	0.92	0.94	C	Adequate	Ultrasound has higher diagnostic accuracy for pneumonia than X-ray, especially in frail patients
Huang, BMC Pulm Med, 2018, [25]	ICU, prospective	51	82	ARDS vs no ARDS	Chest CT	0.88	0.89	C	Adequate	Lung ultrasound was consistent with CT findings in the diagnosis of ARDS
Cogliati, Int J Cardiol, 2016, [35]	IM ward, prospective	150	81	Prediction of adverse events in AHF	Echo-cardiography	NA	NA	C	Adequate	Persistence of ultrasound signs of acute heart failure is associated with mortality
Mozzini, Intern Emerg Med, 2018, [36]	IM ward, prospective parallel-group trial	120	84	Prediction of LOS and therapeutic adjustments	Echo-cardiography	NA	NA	C	Adequate	Lung ultrasound reduced LOS and predicted therapeutic variations in AHF

				in AHF						
Huang, J Thorac Dis, 2017, [50]	ICU, prospective	40	84	Mechanical ventilator weaning in ARF	NA	NA	NA	C	Poor	Diaphragmatic dysfunction, assessed by M-mode ultrasound, predict mechanical ventilator weaning failure
Marchioni, Crit Care, 2018, [52]	ICU, prospective	75	78	NIV weaning in AECOPD	NA	NA	NA	C	Adequate	Change in diaphragm thickness predict NIV weaning failure and mortality

ED=Emergency Department; IM=Internal Medicine; NA=Not Assessed; ICU=Intensive Care Unit; ARDS=Acute Respiratory Distress Syndrome; CT=Computed Tomography; AHF=Acute Heart Failure; ARF=Acute Respiratory Failure; NIV=Non-Invasive Ventilation; AECOPD=Acute Exacerbation of Chronic Obstructive Pulmonary Disease

FIGURE 1

Principal pathologic findings at chest ultrasound using a convex probe. **A:** hyperechoic, consolidated lung parenchima (dotted line). The hyperechoic spots are consistent with an air bronchogram (continued line circle); **B:** Free flowing non septated, anechoic, pleural effusion (dotted line). The compressed lung parenchima is not ventilated and, consequently, athelectasic, clearly detectable and hypoechoic (continued line); **C:** Complex, loculated pleural effusion (dotted line) surrounding a partially collapsed lower lobe (continued line); **D:** Ultrasonographic B lines, long wide bands of hyperechoic artifact likened to the beam of a flashlight (dotted line).

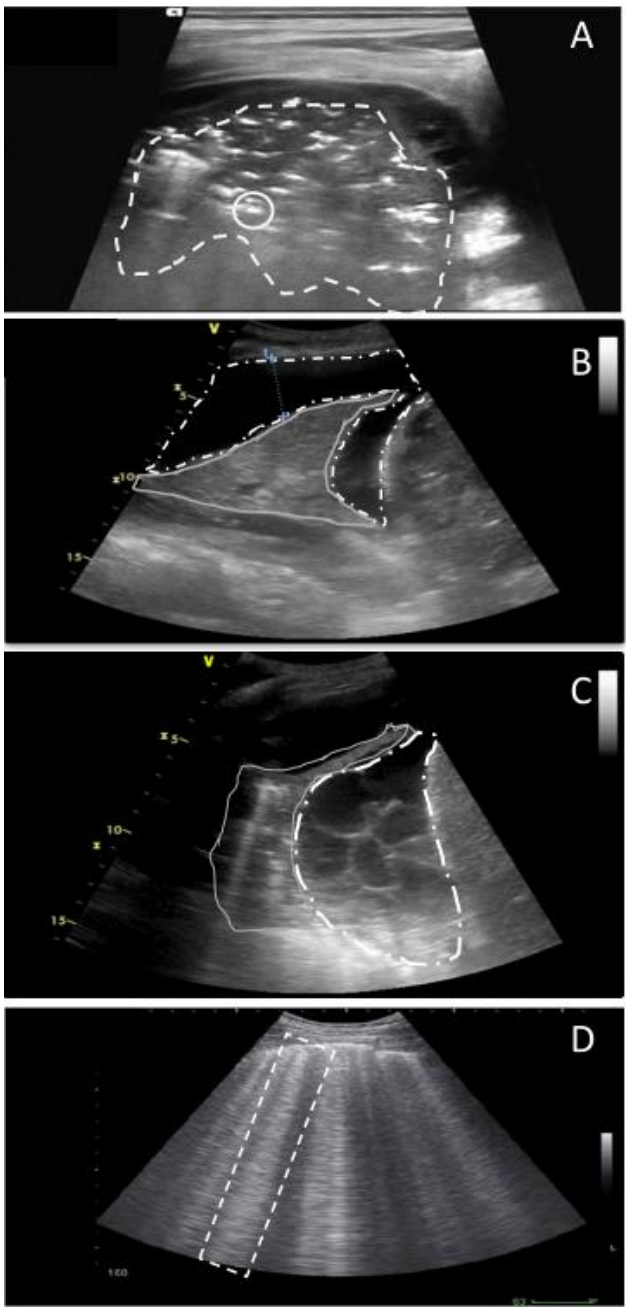

FIGURE 2

Panel 1. Ultrasound diagnosis of Pneumothorax (linear probe). In panel 1.a, the M-mode image demonstrates a linear, laminar pattern in the tissue superficial to the pleural line and a granular or "sandy" appearance deep to the pleural line, suggesting the absence of pneumothorax (seashore sign). In panel 1.b, the M-mode image shows a linear, laminar pattern in the pleural interface, and a similar linear pattern deep to the pleural line (stratosphere sign or barcode sign), indicating the presence of pneumothorax.

Panel 2. Ultrasound diagnosis of lung abscess (convex probe). Panel 2.a: Computed tomography showing a surrounding, thick and irregular consolidation containing a fluid, inner level. In panel 2.b, high amplitude echoes are clearly visible as well as multiple echogenic small air inclusions.

Panel 3. Ultrasound diagnosis of lung tumour (convex probe). Panel 3.a: Computed tomography showing a large right apical mass infiltrating the chest wall. Panel 3.b.: corresponding ultrasonographic view of a hypoechoic lesion with posterior acoustic enhancement (PAE) and irregular borders. The visceral pleura is interrupted since it is infiltrated by the tumor (white arrows).

Panel 4. Ultrasound diagnosis of malignant pleural mesothelioma (convex probe). Panel 4.a: Computed tomography of large pleural, confluent, masses (yellow arrows), wide thickening of soft tissue attenuation involving the right chest wall and the diaphragm and associated with malignant pleural effusion. Panel 4.b: Ultrasound demonstrating large, anechoic effusion, above a flattened diaphragm, extensively infiltrated by thick, irregular nodularity arising from the diaphragm and the visceral pleura.

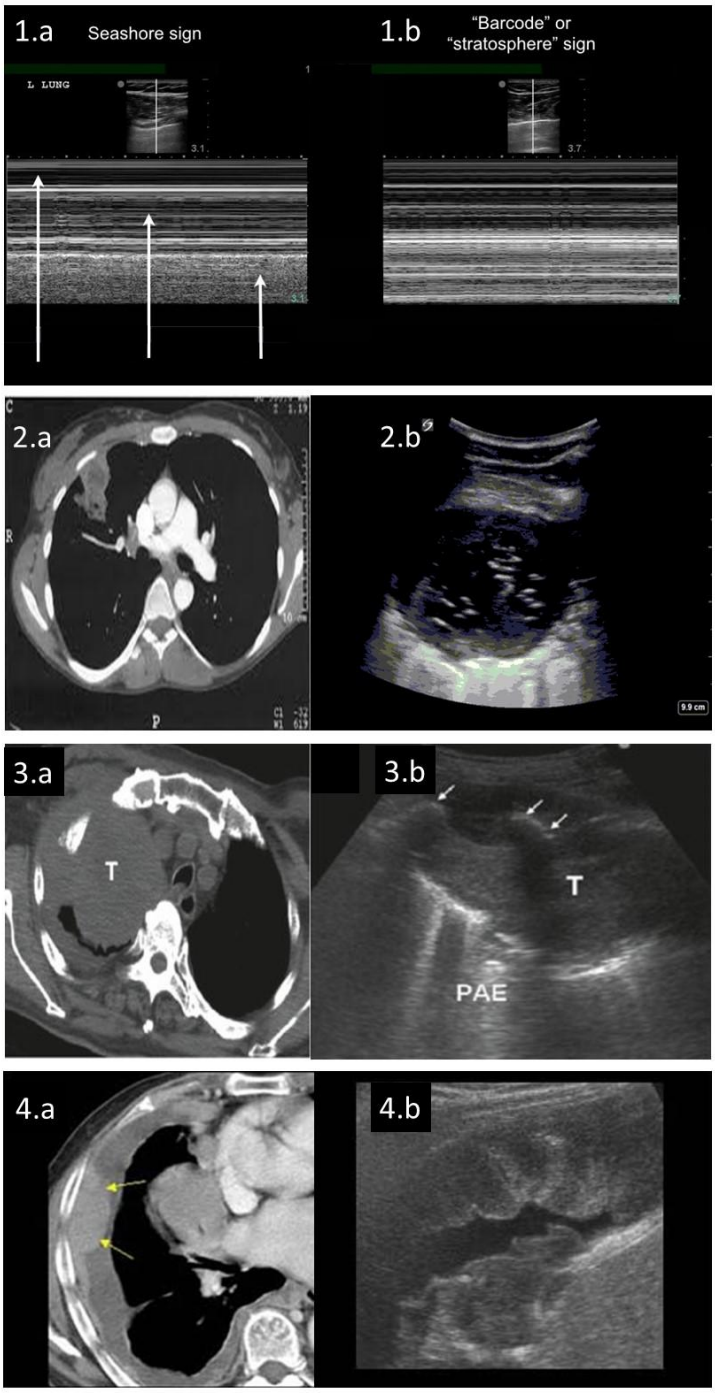
1.a
Seashore sign
L LUNG
1.b
"Barcode" or
"stratosphere" sign
2.a
2.b
3.a
T
3.b
T
PAE
4.a
4.b

515

*Manuscript with marked changes
Click here to view linked References

ABSTRACT

Objectives- To investigate on the current evidence on the use of point-of-care chest ultrasound in older patients and geriatric settings, and present the current state-of-art of chest ultrasound applications.

Design- ~~Systematic review with narrative analysis~~Special article based on a literature review with narrative analyses, and expert clinical knowledge.

Setting and participants- All studies performed in a geriatric setting were included. Observational and intervention studies and meta-analyses including participants aged ≥70 were also considered, even if not specifically focused on a geriatric setting.

Measures- Data on participant characteristics, diagnostic accuracy of chest ultrasound and outcomes were collected for each considered study. Data were analyzed and discussed with a particular focus on the possible applications and advantages of chest ultrasound in geriatric medicine, underlining the possible areas of future research.

Results- We found only five studies on the diagnostic accuracy and prognostic relevance of chest ultrasonography in geriatrics. However, several studies performed in Emergency Departments, Intensive Care Units and internal medicine wards, included a large number of participants over 70 years old; they suggest that chest ultrasonography may represent a valid aid to the diagnostics of acute dyspnea, pneumonia, acute heart failure, pneumothorax, and pleural diseases, with an accuracy in some cases superior to standard X-rays, especially when mobility-limitation is present. Diaphragm ultrasound may also represent a valid tool to guide mechanical ventilation weaning in older patients with acute respiratory failure.

Conclusions and Implications- Chest ultrasound may represent a valid bedside diagnostic aid to the management of acute respiratory diseases in older patients. However, specific evidence is lacking for geriatric patients. Future research will need to focus on defining the reference standards and the diagnostic accuracy for frail and multimorbid elderly patients, cost/efficacy and

cost/effectiveness of the technique, its impact for clinical outcomes and role for follow-up in the post-acute care.

Key words: lung ultrasound; point-of-care; respiratory diseases; diagnostic accuracy

INTRODUCTION

In modern medicine, point-of-care ultrasonography has become one of the most ~~powerful and versatile~~popular tools for assisting the diagnostic process in hospitalized patients, as a technologic complement to physical examination and laboratory biomarkers.[1] Although partly dependent on the skills of each operator, it is considered a safe and rapid imaging technique providing ~~immediate~~ responses to several clinical questions directly at the bedside and ~~exactly~~ at the moment of need.[1]

Chest ultrasound is perhaps one of the least expected applications of point-of-care ultrasonography, ~~since~~ because respiratory structures, and particularly the lung parenchyma, cannot be directly explored by ultrasounds. In fact, lung parenchyma has a high acoustic impedance preventing the definition of anatomically faithful images.[1] However, ultrasonographic evaluation of the lung may provide ~~several~~ a great deal of clinically relevant information in both health and disease, thanks to a simple and highly reproducible semeiotics.[1-3] This technique has entered clinical practice for the diagnosis of respiratory diseases in several settings, ranging from Emergency Departments (EDs) to Intensive Care Units (ICUs) to acute Internal Medicine and Pulmonology wards.[2,3]

Unfortunately, ~~this is probably not the case for~~ chest ultrasound is not so popular in Geriatric wards. Possible barriers for bedside implementation of this technique may include reduced availability of portable equipment, ~~and~~ limited access to specific training courses, perception of ultrasound as a scarcely reproducible examination, especially in subjects with severe mobility-limitations and dementia. ~~However, chest ultrasound is a practical and easy-to-learn technique, even for those who have little experience with abdominal ultrasound. In fact, under specific questions, bedside chest ultrasound is an effective diagnostic tool also in the hands of relatively unskilled healthcare professionals, such as medical residents.[4]~~

OBJECTIVES AND METHODS

Our aim was to investigate ~~on~~ the current evidence on the use of point-of-care chest ultrasound in older patients and geriatric~~s~~ wards, present its current applications and ~~to~~ identify areas ~~of development of the technique~~for future research in the geriatric setting.

A literature search was ~~made~~ conducted on PubMed as of December 19th, 2018, using the search strategy reported in the Supplementary Material, that used "chest ultrasound", "lung ultrasound", "geriatric" and "older individuals" as the main key words.

The results of the search showed substantial lack of papers ~~on the topic~~with a geriatric focus (16 manuscripts, of ~~whom~~ which only 5 reporting original data). Thus, we decided to present the current state-of-the-art of chest ultrasound applications in medical patients with a narrative approach, focusing on studies where participants with a mean age ≥70 years old were enrolled and highlighting the points of interest for older patients and applications for geriatric medicine.

~~THE SEMEIOTICS OF~~ CHEST ULTRASOUND METHODOLOGY AND RELATED ISSUES

The recommendations on the best way to perform a bedside chest ultrasound[1] are summarized in Table 1. There are no specific recommendations for geriatric patients in the scientific literature. The main critical issue in older individuals is severe mobility-disability, preventing the patient to maintain the sitting position for the time of the examination. However, some protocols include the possibility of performing ultrasound with the patient lying supine, or with the aid of a second operator, helping the patient to remain seated[~~4~~5], so that the methodology of examination fits to the patient's motoric performance (Table 1). This versatility represents a consistent advantage of ultrasound, compared to X-ray. It also makes ultrasound an ideal diagnostic tool for low-resource or low-care-intensity settings, including nursing homes and home-based palliative care, because it can be delivered directly at the bedside preventing patient's distress for transfers.[5]

Modern ultrasound equipment is generally portable, making it possible to reach the patient bedside in hospital facilities. Smaller, hand-held pocket-size devices are however becoming increasingly popular, making it possible to perform ultrasound in any clinical scenario. The image quality of these devices is generally considered inferior than standard portable ultrasound, but recent studies report good levels of diagnostic accuracy in ED patients[6] and subjects with interstitial lung disease.[7] Pocket-size ultrasound was compared with standard ultrasound in geriatric patients in only one study.[8] Although not focused only on chest examination, it demonstrated that pocket-size ultrasound performed the same as standard equipment in presence of a pre-test clinical suspicion.[8]

~~In normal situations (Figure 1), the ultrasound images should visualize the skin, the hypodermis and the muscles in superficial plans. On a deeper level of that of the ribs, the pleural line, corresponding to the pleura-lung interface, should appear as a hyperechogenic line moving in synchrony with breath.[2] The normal lungs appear below the pleural line as a black space, possibly containing horizontal artifacts appearing as parallel equidistant lines, the so-called A-lines, representing reverberations of acoustic interfaces situated above.[2] At the caudal extreme of the lungs, in~~

~~correspondence of the costophrenic recess, a "curtain sign" may appear, representing the movement of abdominal organs with diaphragm contraction and breath.[3] The diaphragm appears as a hyperechogenic line surrounding the liver and the spleen, and moving in synchrony with breathing acts[3,6] (Figure 1). A description of normal lung sonographic findings is provided in Table 2.~~

The ultrasonographic appearance of a normal chest is well described in the literature[1-3,9-10], and is summarized in the Supplemental Material (Table S1, Figure S1). In the most common pathological respiratory conditions of elderly patients, such as pneumonia, pleural effusion, pulmonary edema and~~,~~ interstitial lung disease~~ and pneumothorax~~, specific alterations appear on chest ultrasound images, mainly in the form of artifacts[1,10~~7~~] (Table ~~3~~2; Figure ~~2~~1; see also Supplemental Material Figures S2-S10 for a wider set of images). Chest ultrasound can also provide reliable diagnostic signs also for less common conditions, including pneumothorax, lung abscess, lung cancer and pleural mesothelioma (Table 2; Figure 2; Supplemental Material Figure S10). Although these signs do not always correspond to precise anatomical alterations, they are associated with well-known patho-physiological alterations typical of each disease (Table 2).[1,10~~7~~] ~~Thus, they have a high diagnostic value, because each of the main acute respiratory diseases is associated with a reproducible semeiotics[1,7] (Table 3).~~

~~Despite the simple classification of ultrasonographic signs, t~~To ~~allow the formulation of an accurate~~make a correct diagnosis, chest ultrasonography requires in many cases an integration of imaging with clinical ~~and anamnestic~~ data. For example, B lines, the main sign associated with "wet lungs" typical of acute heart failure, can be detected also in areas surrounding an isolated alveolar consolidation, such as those seen in pneumonia[~~8~~11] ~~(Figure 1)~~. In case of thoracic trauma, B lines and consolidation patterns may coexist and indicate a lung contusion. The differential diagnosis of isolated lung consolidations may also be particularly challenging, since they can be associated with pneumonia, cancer, pulmonary embolism or atelectasis. The ~~visualization and~~ characterization of consolidations ~~are~~ is generally easier when they are positioned in subpleural regions, while

~~differential diagnosis may result difficult for deeper lesions~~deeper lesions are more difficult to detect.~~9~~-[12]

Apart from these critical issues, the achievement of technical competency in lung ultrasound is generally easier and quicker than abdominal ultrasound. Different studies have shown that novice sonographers have a fair to excellent agreement with experienced sonographers in making basic diagnoses after training courses lasting no more than few days.[13-15] Moreover, the inter-operator agreement in ultrasound image obtainment and interpretation is high (≥90%) when the examination is repeated on the same patient by sonographers with different level of experience.[4]

APPLICATIONS OF CHEST ULTRASOUND IN DIFFERENT CLINICAL SITUATIONS

Acute dyspnea and acute respiratory failure

Chest ultrasound has been particularly studied in ~~the context of~~ management of acute dyspnea in the ED, where it can be ~~applied~~ performed even in the absence of a specific diagnostic question.[~~10~~-16] It has been implemented also in ICUs, for detecting the causes of acute respiratory failure and monitoring the evolution of respiratory conditions.[~~11~~-17]

According to a recent meta-analysis including studies with a high number of older patients, chest ultrasound has ~~a~~ very good diagnostic performance in the detection of the most common causes of acute dyspnea in the ED.[~~10~~–16] The pooled Areas Under the Receiver Operating Characteristics (AUROCs) curves were 0.948 for pneumonia, 0.914 for acute heart failure and 0.906 for COPD exacerbations.[~~10~~-16]

In the largest of these studies, chest ultrasound was able to differentiate cardiac vs noncardiac causes of dyspnea with a significantly higher accuracy (sensitivity 97%, specificity 97.4%) than chest X-ray or clinical-anamnestic workup in 1,005 patients with a mean age of 77.[~~12~~-18]

~~Older age may however have some negative impact on the diagnostic accuracy of chest ultrasound in differentiating causes of acute dyspnea.~~ In a group of 130 older patients aged in average 81 years old admitted with acute dyspnea ~~to~~ in an internal medicine ward, the diagnostic performance was slightly lower than that reported in other studies (sensitivity 93.~~75~~8%, specificity 86.1~~1~~%), though remaining excellent and non-inferior than X-ray.[~~13~~-19] In an ED setting, the diagnostic accuracy of chest ultrasound for differentiating cardiogenic causes of dyspnea in 236 patients with a mean age of 80 was lower than expected (sensitivity 57.7%, specificity 87.9%)~~.~~[~~14~~20], indicating that older age may have some negative impact on chest ultrasound diagnostic performance.

Despite these limitations, the implementation of chest ultrasound in the ED implies faster treatment and disposition. In the only randomized ~~controlled~~ trial published to date, 320 patients presenting to the ED with acute dyspnea (mean age 73) received point-of-care ultrasonography vs usual care.[~~15~~-21] Four hours after ED admission, the number of patients with a correct presumptive diagnosis was

significantly higher in the ultrasound group, implying quicker symptom relief and disposition in appropriate care settings.[21~~15~~]

In critical patients admitted to ICUs, chest ultrasound is a very useful technique ~~not only for differentiating the causes of acute respiratory failure, but~~ also for monitoring fluid repletion in acute circulatory failure, assessing Acute Respiratory Distress Syndrome (ARDS), investigating pneumonia as a possible cause of fever and assisting physicians during invasive maneuvers.[~~16~~ 22] Lung ultrasound outperformed chest X-ray in detecting the cause of acute respiratory ~~failure~~[~~17~~] failure[23] and differentiating cardiogenic acute pulmonary edema from other diseases, including ARDS, in patients under 70 years old.[24~~18~~] In the only study specifically focused on a geriatric ICU population (51 patients aged from 73 to 91), lung ultrasound was able to recognize the presence of ARDS with a fairly good accuracy (AUROCs 0.783 and 0.902 at the first and third day of stay, respectively), and the diagnostic performance significantly improved when lung ultrasonography was performed in combination with echocardiography (AUROCs 0.924 and 0.956, respectively).[25~~19~~] Interestingly, ~~some~~ simplified protocols of chest ultrasound assessment (such as the BLUE and FALLS protocols) have been developed in the ICU setting, to overcome the limitations implied by limited patient mobility.[~~20~~ 26] Although these limitations are shared also by many geriatric patients outside the ICU, no studies have evaluated the diagnostic performance of these protocols in a geriatric setting.

Pneumonia

In a recent literature meta-analysis, the diagnostic performance of lung ultrasound for detection of pneumonia in ED was optimal (pooled AUROC 0.97).[~~21~~ 27] ~~The presence of a clinical suspicion, combined with t~~The ~~ultrasonographic detection~~presence of parenchymal consolidations with dynamic air bronchogram or focal interstitial syndrome at lung ultrasound~~,~~ in patients with compatible clinical signs and symptoms ~~allowed to reach a correct diagnosis~~was diagnostic of pneumonia in almost all cases, with very few false negative examinations. In this context,

ultrasound exhibits a high concordance with ~~CT[22]~~CT[28], and a lower concordance with X-ray findings.~~[23]~~-[29]

These considerations apply also to patients admitted to medical wards. Two meta-analyses of the existing studies performed in this setting identified a summary AUROC of 0.99 for the diagnosis of pneumonia,~~[24]~~[30]~~,[25]~~-[31] while another more recent meta-analysis showed a summary AUROC of 0.90, with ~~a diagnostic performance significantly better than that of~~ultrasound outperforming X-ray (summary AUROC 0.59).~~[26]~~-[32] The diagnostic capacity of ultrasound is reduced only in case of deep lesions not involving subpleural plans (8% of pneumonic consolidations detected by CT), as suggested by two studies performed in groups of 342 and 362 adult (mean age <65) internal medicine patients, respectively.~~[27]~~[33]~~,[28]~~-[34] Once the diagnosis is established, ultrasound may also represent a useful tool for monitoring the resolution of pneumonic infiltrations at follow-up.~~[27]~~-[33]

Very few investigations have assessed the diagnostic performance of ultrasonography for pneumonia in geriatric patients. In a group of 169 older patients (mean age 83) hospitalized for acute respiratory symptoms, the diagnostic accuracy for pneumonia of ultrasound was significantly higher than that of X-ray (0.90 vs 0.67), and the difference was particularly pronounced in those subjects with frailty and severe mobility-disability.~~[5]~~-[4]

Acute heart failure

The diagnostic performance of lung ultrasound in detecting acute heart failure has been well demonstrated in ED and ICU settings as superior to that of X-ray, particularly when echocardiography is also performed.~~[12]~~-[18]

In internal medicine wards, bedside ultrasound can be very useful for monitoring treatment response and modulating diuretic therapy.~~[29]~~[35]~~,[30]~~-[36] B-lines are in fact expression of extravascular lung water and their number is related to the severity of congestion[37]. ~~The presence of r~~Residual B-lines at discharge ~~is a significant predictor of~~predict hospital readmission and mortality.~~[29]~~-[35] During hospital

stay, a close ultrasonographic follow-up, with daily or alternate day assessment, can help to adjust diuretic dosage and speed up the discharge time.[~~30~~ 36]

Moreover, bedside lung ultrasound can be used to estimate the volemic state and the possible presence of fluid overload. The addition of inferior vena cava ultrasonography can be particularly useful in this context.[~~30~~ 36]

Unfortunately, the application of repeated lung ultrasound monitoring in geriatric acute heart failure patients has not been specifically addressed by the existing literature to date. However, lung ultrasound has proven useful in assessing lung congestion in older patients with end-stage renal disease undergoing dialysis[38].

Pneumothorax

In a recent meta-analysis of the literature, lung ultrasound has proven as significantly more ~~accurate~~ sensitive than chest X-ray for the detection of pneumothorax (~~sensitivity~~ 78.6% vs 39.8%), with similar specificity~~ 98.4% vs 99.3%)~~.[~~31~~–39] ~~This is particularly true~~The diagnostic accuracy is particularly high for small lesions, that cannot generally be detected by standard X-rays, ~~allowing to spare the prescription of CTs~~and would generally require a CT examination for prompt diagnosis.[~~32~~ 40] Ultrasound can also help to stage the pneumothorax severity, identifying the percentage of lung collapse or the distance between lung parenchyma and visceral pleura.[~~33~~-41] However, all the existing studies were focused on the detection of traumatic or iatrogenic pneumothorax in critical care, and none was specifically focused on older individuals.

Pleural diseases

The detection and monitoring of pleural effusion is probably the oldest and simplest application of chest ultrasound. Its diagnostic accuracy is very high, especially for mild effusions that cannot be easily detected with X-rays.[~~34~~–42] Additionally, ultrasound is an excellent guide for ~~performing~~ thoracentesis ~~in safety and~~procedures, limiting the risk of iatrogenic pneumothorax.[~~34~~ 42]

Ultrasound can also help to estimate the severity of a pleural effusion. Besides the simple count of intercostal spaces where the effusion can be visualized, more precise methods of assessment have been proposed. ~~These methods are generally based on t~~The ultrasonographic measurement of the distance from visceral pleura to chest wall, the distance from lung base to apex of diaphragm cupola and the height of the effusion~~, and~~ allows the calculation of fluid volume using validated equations.[~~35~~-43] The maximal distance between visceral and parietal pleura can be also used as a proxy of fluid volume.[~~36~~-44] The estimations of fluid volume obtained using these methods were significantly correlated with the volume obtained by thoracentesis drainage.[~~37~~-45]

Chest ultrasound also exhibited a higher accuracy than X-ray for the detection of complicated effusions, pleural adhesions and exudative effusions.[~~34~~42,~~37~~-45] Moreover, it exhibited an optimal diagnostic performance also for the detection of parapneumonic effusions, since it can be very helpful also for identifying the parenchymal consolidations.[~~38~~-46]

Unfortunately, none of the existing studies on the ultrasonographic assessment of pleural effusions was specifically focused on older patients.

Recent research has also demonstrated that chest ultrasonography is an excellent tool for the detection of asbestos-related pleural plaques and other small non-malignant lesions, visualized as focal pleural line thickenings.[~~39~~47,~~40~~-48] The diagnostic accuracy in this field may be even superior to that of CT,[~~39~~-47] and ultrasound may also be useful for the follow-up of lesions detected with CT.[~~40~~-48]

Pulmonary embolism

A meta-analysis showed that chest ultrasound exhibits a good diagnostic accuracy (sensitivity 87%, specificity 81.8%) for pulmonary embolism, though inferior to that of contrast-enhanced CT.[~~41~~-49] Thus, chest ultrasound in pulmonary embolism may represent only a complementary diagnostic test, and not a routine procedure. However, in patients with a clearly positive lung ultrasound examination, the prescription of contrast-enhanced CT could be avoided, reducing costs and radiation exposure, and with definite advantages in subjects with chronic kidney disease.[~~42~~-50]

Diaphragm dysfunction assessment

The assessment of diaphragmatic motion with M-Mode chest ultrasound is a highly reproducible technique that can be easily applied in clinical practice.[6-51] In a group of elderly (age ≥80) patients admitted with acute respiratory failure to a Chinese ICU and subdued to at least 48 hours of mechanical ventilation, the M-mode ultrasound-diagnosed diaphragmatic dysfunction was significantly associated with ventilation weaning failure and poor outcomes.[52~~43~~]

Alternatively, diaphragmatic dysfunction can be assessed with B-mode ultrasound, measuring changes in diaphragm thickness during tidal volume (ΔTdi). In mechanically ventilated patients, this parameter was significantly associated with a longer ICU stay and increased risk of hospital death.[53~~44~~] In a group of elderly patients (mean age 78) undergoing noninvasive mechanical ventilation (NIV) for acute COPD exacerbation, ΔTdi <20% was the best single clinical parameter to predict NIV failure and adverse outcomes.[54~~45~~]

GERIATRIC CHEST ULTRASOUND: A CALL FOR ACTION~~S~~

Overview of results

The results of chest ultrasound studies performed either in a geriatric setting or in a population with mean age ≥70 years old are summarized in Table 3, with their evidence grade and quality ranking, determined according to the methods already used by Barth and colleagues (see also Supplemental Material).[55] Altogether, these studies support the implementation of bedside chest ultrasound in geriatric wards, but their number and quality is too scarce to formulate specific recommendations. Studies focused on older patients and geriatric settings are thus urgently needed.

The possible advantages of chest ultrasound in geriatrics

A number of circumstances indicate that the geriatric patient may represent the ideal recipient of chest ultrasound implementation programs. First, ~~The~~ the aging respiratory system~~s~~ is characterized by some peculiarities that make ~~traditional imaging diagnostics~~X-rays and, to a lesser extent, CT more difficult to perform and less accurate to interpret even when a respiratory disease is absent[56]. ~~These may include changes in lung volumes, mucociliary clearance, bronchial responsiveness, tracheal and bronchial dilation, bronchial wall thickening, air trapping and secretions, that make imaging interpretation challenging even in the absence of defined illnesses.[46]~~ The age-related modifications of lower airways, ~~combined with~~ increases in interstitial connective tissue and reduction of parenchymal vascularization~~,~~ may in fact contribute to define the so-called "dirty chest"~~ on X-rays~~.[~~47~~56-58] Ultrasound is influenced by all these phenomena as well, but its diagnostic performance is maintained thanks to its defined semeiotics and the clinical interpretation of signs.~~This consideration can also apply to chest CT, although the diagnostic accuracy of the technique is certainly superior to X-ray.[48]~~

~~Moreover~~Second, mobility-limitations or reduced capacity to follow instructions due to cognitive impairment ~~is~~ represent ~~another important~~additional issues in older patients, limiting the quality of

chest X-ray or CT scans and reducing their diagnostic accuracy.[59] Ultrasound is only marginally influenced by these factors, exhibiting good performance also in the sickest and in those with severe disability.[4] ~~The acquisition of a good chest X-ray scan requires that the patient maintains the upright posture. Unfortunately, in many cases this is not possible due to osteoarticular diseases, sarcopenia, critical illness, disability, and even severe cognitive impairment with reduced capacity to follow instructions by operators. Thoracolumbar curvatures may particularly affect respiratory function and limit the acquisition of good radiographic images. As a result, the diagnostic performance of chest X-ray may dramatically decrease, with a significant prevalence of misdiagnosis, delayed treatment, and poorer outcomes.[49]~~

~~Chest ultrasound may contribute to bypass many of these problems. However, the current literature state of art on thoracic ultrasound applications shows a substantial lack of studies specifically focused on elderly patients or performed in a geriatric environment. The few existing studies were conducted in the field of acute dyspnea management and pneumonia diagnosis, and all support the implementation of this technique. Research performed in ED, ICU, and internal medicine ward settings also suggests several possible advantages of applying chest ultrasound in the geriatric practice. Specifically focused studies are however needed.~~

Finally, ultrasound is cheaper and safer than traditional imaging examinations, and its routine use optimizes follow-up of critical patients, reducing the number of X-rays and, possibly, CTs, with lower costs and radiation exposure.[60] This advantage is particularly useful in geriatric patients, who have often a high level of clinical complexity requiring several diagnostic resources.

Areas of development

~~At the current state of art~~Although ultrasound images are less influenced by age-related changes in anatomy and physiology of the respiratory system than X-ray, ~~the~~ its normal reference standards ~~of chest ultrasound imaging~~ in healthy older persons are still unclear, and should be carefully studied.

~~The age-related changes in anatomy and physiology of the respiratory system can modify the ultrasonographic appearance of a normal chest,[46-48] and should be carefully studied.~~

Aging can also affect diaphragmatic structure and function independently of the presence of respiratory diseases. Thus, normative data on this aspect are needed, in order to clarify the usefulness of diaphragmatic ultrasound in clinical practice.

~~Future research should also help to clarify several critical points of the application of bedside chest ultrasound in older patients with respiratory diseases.~~ Besides the evaluation of diagnostic accuracy in different clinical situations and settings, ~~these~~ other critical points deserving future investigations in older patients may ~~concern~~include:

- The effects of multimorbidity, and particulary cardio-respiratory multimorbidity,[~~50~~–61] on ultrasonographic findings in patients with acute respiratory symptoms;
- The diagnostic advantages of combining chest ultrasound with point-of-care echocardiography in the evaluation of acute dyspnea;
- The usefulness of simplified protocols of ultrasonographic evaluations, such as the FALLS and BLUE protocols~~,~~;[2~~0~~6] ~~in geriatric patients;~~
- The role of chest ultrasound in the detection of diaphragm sarcopenia, either isolated or in the context of systemic sarcopenia;
- The cost/efficacy and cost/effectiveness of chest ultrasonography ~~in the elderly~~;
- The role of chest ultrasound in the post-acute and long-term ~~care~~ follow-up of older patients with cardio-respiratory diseases.

Moreover, the effects of chest ultrasound implementation in clinical practice on patient-related outcomes should be particularly investigated. In this field, education of geriatricians and residents in geriatrics on point-of-care ultrasound principles could help to improve the quality of care and contribute to improve outcomes.

CONCLUSIONS AND IMPLICATIONS

Chest ultrasound is an easy, accurate and versatile diagnostic tool for the management of acute respiratory symptoms and conditions in many clinical settings, including acute-care hospital wards, nursing homes and community services. However, very few studies have explored this diagnostic technique specifically in a geriatric environment. Even if no evidence-based recommendations on the use of bedside chest ultrasound can be specifically made ~~specifically~~ for geriatric patients, ~~an~~ implementation of this technique in geriatric research and practice is desirable, considering the large amount of evidence in younger patients and in different clinical settings. ~~Future research should be focused on the reference standards in the elderly, on the advantages and cost-effectiveness of the implementation of the technique in both acute and post-acute care setting and on the relationship of its findings with multimorbidity and sarcopenia.~~

ACKNOWLEDGEMENTS

Conflict of interest

The authors have nothing to disclose.

Funding

There is no external funding to report for this study.

REFERENCES

1. Volpicelli G, Elbarbary M, Blavais M, et al. International evidence-based recommendations for point-of-care lung ultrasound. Intensive Care Med 2012;35:577-591.
2. Koenig SJ, Narasimhan M, Mayo PH. Thoracic ultrasonography for the pulmonary specialist. Chest 2011;140(5):1332-1341.
3. Zanforlin A, Giannuzzi R, Nardini S, et al. The role of chest ultrasonography in the management of respiratory diseases: document I. Multidiscip Respir Med 2013;8:54.
4. ~~Mozzini C, Fratta Pasini AM, Garbin U, et al. Lung ultrasound in internal medicine: training and clinical practice. Crit Ultrasound J 2016;8:10.~~
4. Ticinesi A, Lauretani F, Nouvenne A, et al. Lung ultrasound and chest X-ray for detecting pneumonia in an acute geriatric ward. Medicine 2016;95:27(e4153).
5. Dhamija E, Thulkar S, Bhatnagar S. Utility and potential of bedside ultrasound in palliative care. Indian J Palliat Care 2015;21(2):132-136.
6. Sforza A, Mancusi C, Carlino MV, et al. Diagnostic performance of multi-organ ultrasound with pocket-sized device in the management of acute dyspnea. Cardiovasc Ultrasound 2017;15(1):16.
7. Cogliati C, Antivalle M, Torzillo D, et al. Standard and pocket-size lung ultrasound devices can detect interstitial lung disease in rheumatoid arthritis patients. Rheumatology 2014;53(8):1497-1503.
8. ~~5.~~ Fröhlich E, Beller K, Muller R, et al. Point of care ultrasound in geriatric patients: prospective evaluation of a portable handheld ultrasound device. Ultraschall Med 2019;in press Apr 26. Doi:10.1055/a-0889-8070.
9. ~~6.~~ Scarlata S, Mancini D, Laudisio A, et al. Reproducibility and clinical correlates of supine diaphragmatic motion measured by M-mode ultrasonography in healthy volunteers. Respiration 2018;96(3):259-266.

~~7.~~10. Wallbridge P, Steinfort D, Tay TR, et al. Diagnostic chest ultrasound for acute respiratory failure. Resp Med 2018;141:26-36.

~~8.~~11. Dietrich CF, Mathis G, Blavais M, et al. Lung B-line artifacts and their use. J Thorac Dis 2016;8(6):1356-1365.

12. Reissig A, Gramegna A, Aliberti S. The role of lung ultrasound in the diagnosis and follow-up of community-acquired pneumonia. Eur J Intern Med 2012;23:391-397.

13. Mozzini C, Fratta Pasini AM, Garbin U, et al. Lung ultrasound in internal medicine: training and clinical practice. Crit Ultrasound J 2016;8:10.

14. Begot E, Grumann A, Duvoid T, et al. Ultrasonographic identification and semiquantitative assessment of unloculated pleural effusions in critically ill patients by residents after a focused training. Intensive Care Med 2014;40:1475-1480.

~~9.~~15. Andersen GN, Viset A, Mjølstad OC, et al. Feasibility and accuracy of point-of-care pocket-size ultrasonography performed by medical students. BMC Med Educ 2014;14:156.

~~10.~~16. Staub LJ, Mazzali Biscaro RR, Kaszubowski E, et al. Lung ultrasound for the emergency diagnosis of pneumonia, acute heart failure, and exacerbations of chronic obstructive pulmonary disease/asthma in adults: a systematic review and meta-analysis. J Emerg Med 2018; ahead of print Oct 9. Doi: 10.1016/j.jemermed.2018.09.009.

~~11.~~17. Ashton-Cleary DT. Is thoracic ultrasound a viable alternative to conventional imaging in a critical care setting? Br J Anesthesia 2013;111(2):152-160.

~~12.~~18. Pivetta E, Goffi A, Lupia E, et al. Lung ultrasound-implemented diagnosis of acute decompensated heart failure in the ED. A SIMEU multicenter study. Chest 2015;148(1):202-210.

~~13.~~19. Perrone T, Maggi A, Sgarlata C, et al. Lung ultrasound in internal medicine: a bedside help to increase accuracy in the diagnosis of dyspnea. Eur J Intern Med 2017;46:61-65.

~~14.~~20. Sartini S, Frizzi J, Borselli M, et al. Which method is best for an early accurate diagnosis of acute heart failure? Comparison between lung ultrasound, chest X-ray and NT pro-BNP performance: a prospective study. Intern Emerg Med 2017;12:861-869.

~~15.~~21. Laursen CB, Sloth E, Lassen AT, et al. Point-of-care ultrasonography in patients admitted with respiratory symptoms: a single-blind, randomized controlled trial. Lancet Respir Med 2014;2(8):638-646.

~~16.~~22. Lichtenstein D, van Hooland S, Elbers P, et al. Ten good reasons to practice ultrasound in the critical care. Anaesthesiol Intensive Ther 2014;46(5):323-335.

~~17.~~23. Xirouchaki N, Magkanas E, Vaporidi K, et al. Lung ultrasound in critically ill patients: comparison with bedside chest radiography. Intensive Care Med 2011;37:1488-1493.

~~18.~~24. Sekiguchi H, Schenck LA, Horie R, et al. Critical care ultrasonography differentiates ARDS, pulmonary edema, and other causes in the early course of acute hypoxemic respiratory failure. Chest 2015;148(4):912-918.

~~19.~~25. Huang D, Ma H, Xiao Z, et al. Diagnostic value of cardiopulmonary ultrasound in elderly patients with acute respiratory distress syndrome. BMC Pulm Med 2018;18(1):136.

~~20.~~26. Lichtenstein DA. BLUE-protocol and FALLS protocol: two applications of lung ultrasound in the critically ill. Chest 2015;147(6):1659-1670.

~~21.~~27. Orso D, Guglielmo N, Copetti R. Lung ultrasound in diagnosing pneumonia in the emergency department: a systematic review and meta-analysis. Eur J Emerg Med 2018;25(5):312-321.

~~22.~~28. Nazerian P, Volpicelli G, Vanni S, et al. Accuracy of lung ultrasound for the diagnosis of consolidations when compared to chest computed tomography. Am J Emerg Med 2015;33:620-625.

~~23.~~29. Self WH, Courtney DM, McNaughton CD, et al. High discordance of chest X-ray and computed tomography for detection of pulmonary opacities in ED patients: implications for diagnosing pneumonia. Am J Emerg Med 2013;31:401-405.

~~24.~~30. Chavez MA, Shams N, Ellington LE, et al. Lung ultrasound for the diagnosis of pneumonia in adults: a systematic review and meta-analysis. Respir Res 2014;15:50.

~~25.~~31. Hu QJ, Shen YC, Jia LQ, et al. Diagnostic performance of lung ultrasound in the diagnosis of pneumonia: a bivariate meta-analysis. Int J Clin Exp Med 2014;7(1):115-121.

~~26.~~32. Ye X, Xiao H, Chen B, et al. Accuracy of lung ultrasonography versus chest radiography for the diagnosis of adult community-acquired pneumonia: review of the literature and meta-analysis. PLoS One 2014;10(6):e0130066.

~~27.~~33. Reissig A, Copetti R, Mathis G, et al. Lung ultrasound in the diagnosis and follow-up of community-acquired pneumonia: a prospective, multicenter, diagnostic accuracy study. Chest 2012;142(4):965-972.

~~28.~~34. Sperandeo M, Carnevale V, Muscarella S, et al. Clinical application of transthoracic ultrasonography in inpatients with pneumonia. Eur J Clin Invest 2011;41(1):1-7.

~~29.~~35. Cogliati C, Casazza G, Ceriani E, et al. Lung ultrasound and short-term prognosis in heart failure patients. Int J Cardiol 2016;218:104-108.

36. Mozzini C, Di Dio Perna M, Pesce G, et al. Lung ultrasound in internal medicine efficiently drives the management of patients with heart failure and speeds up the discharge time. Intern Emerg Med 2018;13(1):27-33.

37. Picano E, Pellikka PA. Ultrasound of extravascular lung water: a new standard for pulmonary congestion. Eur Heart J 2016;37:2097-2104.

~~30.~~38. Zoccali C, Tripepi R, Torino C, et al. Lung congestion as a risk factor in end-stage renal disease. Blood Purif 2013;36:184-191.

~~31.~~39. Alrajab S, Youssef AM, Akkus NI, et al. Pleural ultrasonography versus chest radiography for the diagnosis of pneumothorax: review of the literature and meta-analysis. Crit Care 2013;17:R208.

~~32.~~40. Lichtenstein DA, Mezière G, Lascols N, et al. Ultrasound diagnosis of occult pneumothorax. Crit Care Med 2005;33(6):1231-1238.

~~33.~~41. Volpicelli G, Boero E, Sverzellati N, et al. Semi-quantification of pneumothorax volume by lung ultrasound. Intensive Care Med 2014;40:1460-1467.

~~34.~~42. Hooper C, Lee YCG, Maskell N. Investigation of a unilateral pleural effusion in adults: British Thoracic Society pleural disease guideline 2010. Thorax 2010;65(Suppl 2):ii4-ii17.

~~35.~~43. Hassan M, Rizk R, Essam H, et al. Validation of equations for pleural effusion volume estimation by ultrasonography. J Ultrasound 2017;20:267-271.

~~36.~~44. Balik M, Plasil P, Waldauf P, et al. Ultrasound estimation of volume of pleural fluid in mechanically ventilated patients. Intensive Care Med 2006;32:318-321.

~~37.~~45. Remérand F, Dellamonica J, Mao Z, et al. Multiplane ultrasound approach to quantify pleural effusion at the bedside. Intensive Care Med 2010;36:656-664.

~~38.~~46. Svigals PZ, Chopra A, Ravenel JG, et al. The accuracy of pleural ultrasonography in diagnosing complicated parapneumonic pleural effusions. Thorax 2017;72(1):94-95.

~~39.~~47. Scarlata S, Finamore P, Giannunzio G, et al. Chest ultrasonography in health surveillance of asbestos related pleural disease. Lung Cancer 2017;111:139-142.

~~40.~~48. Smargiassi A, Pasciuto G, Pedicelli I, et al. Chest ultrasonography in health surveillance of asbestos-related lung diseases. Toxicol Ind Health 2017;33(6):537-546.

~~41.~~49. Squizzato A, Rancan E, Dentali F, et al. Diagnostic accuracy of lung ultrasound for pulmonary embolism: a systematic review and meta-analysis. J Thromb Hemost 2013;11:1269-1278.

50. Koenig S, Chandra S, Alaverdian A, et al. Ultrasound assessment of pulmonary embolism in patients receiving CT pulmonary angiography. Chest 2014;145(4):818-823.

~~42.~~51. Scarlata S, Mancini D, Laudisio A, et al. Reproducibility of diaphragmatic thickness measured by M-mode ultrasonography in healthy volunteers. Respir Physiol Neurobiol 2019;260:58-62.

~~43.~~52. Huang D, Ma H, Zhong W, et al. Using M-mode ultrasonography to assess diaphragm dysfunction and predict the success of mechanical ventilation weaning in elderly patients. J Thorac Dis 2017;9(9):3177-3186.

~~44.~~53. Dubè BP, Dres M, Mayaux J, et al. Ultrasound evaluation of diaphragm function in mechanically ventilated patients: comparison to phrenic stimulation and prognostic implications. Thorax 2017;72:811-818.

~~45.~~54. Marchioni A, Castaniere I, Tonelli R, et al. Ultrasound-assessed diaphragmatic impairment is a predictor of outcomes in patients with acute exacerbation of chronic obstructive pulmonary disease undergoing noninvasive ventilation. Crit Care 2018;22:109.

55. Barth BE, Waligora G, Gaddis GM. Rapid systematic review: age-adjusted D-dimer for ruling out pulmonary embolism. J Emerg Med 2018;55(4):586-592.

~~46.~~56. Occhipinti M, Larici AR, Bonomo L, et al. Aging airways: between normal and disease. A multidimensional diagnostic approach by combining clinical, functional, and imaging data. Aging Dis 2017;8(4):471-485.

~~47.~~57. Bonomo L, Larici AR, Maggi F, et al. Aging and the respiratory system. Radiol Clin N Am 2008;46:685-702.

~~48.~~58. Copley SJ, Wells AU, Hawtin KE, et al. Lung morphology in the elderly: comparative CT study of subjects over 75 years old versus those under 55 years old. Radiology 2009;251:566-573.

59. Basi SK, Marrie TJ, Huang JQ, et al. Patients admitted to hospital with suspected pneumonia and normal chest radiographs: epidemiology, microbiology, and outcomes. Am J Med 2004;117:305-311.

~~49.~~60. Zieleskiewicz L, Cornesse A, Hammad E, et al. Implementation of lung ultrasound in polyvalent intensive care unit: impact on irradiation and medical cost. Anaesth Crit Care Pain Med 2015;34:41-44.

~~50.~~61. Vizioli L, Forti P, Bartoli E, et al. Accuracy of lung ultrasound in patients with acute dyspnea: the influence of age, multimorbidity and cognitive and motor impairment. Ultrasound Med Biol 2017;43(9):1846-1852.

TABLE 1

Summary of the main recommendations, retrieved by the scientific literature and international consensus, on how the bedside chest ultrasound should be performed.

ISSUE	RECOMMENDATIONS
Patient position	- Sitting on the bed side (ideal position) - Maintained in the sitting position by a second operator (for those with severe mobility-disability) - Lying supine on the bed (only for bedridden patients) - Supine position is ideal for diaphragm assessment
Use of probes	- Use both convex 3.5-5 MHz and linear 4-8 mHz probes - Convex probes assure a panoramic view, allow ~~to detect~~detection of gross lesions and focus on deeper plans - Linear probes assure a careful examination of surface structures (ling-pleura interface, small pleural and subpleural lesions) at the expense of a reduced penetration of ultrasounds into deeper anatomical plans
Ultrasound modality	- Examination of pleura and lungs should be performed in B-mode - M-mode can be useful for a study of the diaphragm
Methodology of examination	- Split each hemithorax into an antero-lateral (from parasternal to posterior axillary lines) and a posterior sector (from posterior axillary to paravertebral lines), and divide each sector into a superior and inferior half - Investigate systematically the four areas of each hemithorax - Put the probe in each intercostal space, perpendicularly, obliquely and in parallel to the course of the ribs - In bedridden patients, limit investigation to the antero-lateral sectors - Allow small movements ~~Small movements~~ of rotation and tilting of the probes ~~are allowed~~ to assure an optimal visualization of structures - Measure~~ment of~~ diaphragm thickness, excursion in forced respiration, variation of thickness between end inspiration and expiration

~~**TABLE 2**~~

~~Overview of the main ultrasonographic signs that can be detected when examining the chest in normal situations.~~

~~**SIGN/STRUCTURE**~~	~~**ULTRASONOGRAPHIC FEATURES AND CLINICAL MEANING**~~
~~Visceral pleura~~	~~Fine echogenic line which is normally included in the thick line of total reflection of ultrasound waves at the air-filled lung~~
~~Parietal pleura~~	~~Fine, sometimes weak echogenic line, often obscured by reverberation artifacts. With highest resolution transducers, the line of parietal pleura may appear divided into two layers: the parietal pleura and the external endothoracic fascia~~
~~Pleural cavity~~	~~Echo-free to hypoechoic space due to the presence of a small amount of fluid. Often undetectable.~~
~~"Gliding sign"~~	~~Bright, linear interface produced by the air filled lung covered by visceral pleura, moving backwards and forwards with respiration~~
~~Comet-tail artifacts~~	~~Small uneven irregularities at the visceral pleural surface. Such vertical artifacts are common in interstitial lung disease (B-lines), but can be occasionally seen in the normal lung.~~
~~A-lines~~	~~Horizontal, multiple artifacts arising from pleural surface reverberation on the deeper lung plans, typically parallel to the pleural plane. Distance between A-lines is equal to, or a multiple of, the distance between the skin and the parietal pleura. The presence of A-lines testifies to adequate lung expansion and homogeneous ventilation.~~

TABLE ~~3~~2

Overview of the main ultrasonographic signs that can be detected when examining the chest and their correlation with respiratory diseases.

~~US~~ ULTRASOUND SIGN	MOST PROBABLE DIAGNOSIS	DIFFERENTIAL DIAGNOSIS
Hypoechoic space between chest wall and lung (possibly with quadrilater or sinusoid shape, "quad sign" and "sinusoid sign")	Pleural effusion	Pleural thickening Pleural cancer Intraparenchymal cysts
Absent pleural line sliding	Pneumothorax	~~ARDS~~ Acute Respiratory Distress Syndrome Local fibrosis
Dynamic air bronchogram within a parenchymal hyperechoic consolidation	Pneumonia	Atelectasis Pulmonary infarction Pulmonary contusion Cancer
Increased parenchymal echogenicity with loss of pleural line and hypoechoic vascular structures	Pneumonia	Atelectasis Pulmonary infarction Pulmonary contusion Cancer
Peripheral wedge-shaped consolidation	Pulmonary embolism	Pneumonia Cancer
Static air bronchogram within a parenchymal hyperechoic consolidation	Atelectasis	Pulmonary infarction Pulmonary contusion Cancer
Increased B-lines with a widespread distribution	Cardiogenic pulmonary edema	~~ARDS~~Acute Respiratory Distress Syndrome Pneumonia Interstitial lung disease
B-lines with focal distribution (focal interstitial syndrome)	Pneumonia	Pulmonary infarction Pulmonary contusion Acute heart failure
Reduced diaphragm thickness and thickening ratio / reduced excursion	Diaphragm dysfunction	Neuromuscular disease ~~COPD~~Chronic Obstructive Pulmonary Disease Severe focal lung disease (pneumonia, cancer, atelectasis)

~~US=Ultrasound; ARDS=Acute Respiratory Distress Syndrome; COPD=Chronic Obstructive Pulmonary Disease.~~

TABLE 3

Summary of the results of the main studies on chest ultrasound in which a population with a mean age ≥70 years old was enrolled. Grading and quality of evidence is also provided using the method proposed by Barth et al.[53]

First author, journal, year, [ref]	Setting and design	Number of patients	Mean age	Main outcome	Gold standard	Sensitivity	Specificity	Grade of evidence	Quality of evidence	Key finding
Pivetta, Chest, 2015, [18]	7 EDs, observational	1005	77	Cardiogenic vs other dyspnea	Blind review of medical record	0.97	0.97	C	Adequate	Ultrasound can improve the diagnostic accuracy of acute dyspnea in the ED
Perrone, Eur J Intern Med, 2017, [19]	IM ward, observational	150	81	Cardiogenic vs other dyspnea	Discharge diagnosis	0.94	0.86	C	Poor	Bedside ultrasound improves the diagnostic workup of dyspnea in wards
Sartini, Intern Emerg Med, 2017, [20]	ED, observational	236	80	Cardiogenic vs other dyspnea	Expert review of medical records	0.58	0.88	C	Poor	To diagnose acute heart failure, ultrasound should be integrated with clinical information
Laursen, Lancet Respir Med, 2014, [21]	ED, prospective parallel-group trial	320	73	Assignment to the right treatment for dyspnea	Masked audit on clinical records	NA	NA	B	Good	Ultrasound allows quicker and more appropriate treatment of dyspnea, and faster disposition from ED
Ticinesi, Medicine, 2016, [4]	IM/geriatric ward, observational	169	83	Pneumonia vs other respiratory conditions	Blind review of medical record	0.92	0.94	C	Adequate	Ultrasound has higher diagnostic accuracy for pneumonia than X-ray, especially in frail patients
Huang, BMC Pulm Med, 2018, [25]	ICU, prospective	51	82	ARDS vs no ARDS	Chest CT	0.88	0.89	C	Adequate	Lung ultrasound was consistent with CT findings in the diagnosis of ARDS
Cogliati, Int J Cardiol, 2016, [35]	IM ward, prospective	150	81	Prediction of adverse events in AHF	Echo-cardiography	NA	NA	C	Adequate	Persistence of ultrasound signs of acute heart failure is associated with mortality
Mozzini, Intern Emerg Med, 2018, [36]	IM ward, prospective parallel-group trial	120	84	Prediction of LOS and therapeutic adjustments	Echo-cardiography	NA	NA	C	Adequate	Lung ultrasound reduced LOS and predicted therapeutic variations in AHF

				in AHF						
Huang, J Thorac Dis, 2017, [50]	ICU, prospective	40	84	Mechanical ventilator weaning in ARF	NA	NA	NA	C	Poor	Diaphragmatic dysfunction, assessed by M-mode ultrasound, predict mechanical ventilator weaning failure
Marchioni, Crit Care, 2018, [52]	ICU, prospective	75	78	NIV weaning in AECOPD	NA	NA	NA	C	Adequate	Change in diaphragm thickness predict NIV weaning failure and mortality

ED=Emergency Department; IM=Internal Medicine; NA=Not Assessed; ICU=Intensive Care Unit; ARDS=Acute Respiratory Distress Syndrome; CT=Computed Tomography; AHF=Acute Heart Failure; ARF=Acute Respiratory Failure; NIV=Non-Invasive Ventilation; AECOPD=Acute Exacerbation of Chronic Obstructive Pulmonary Disease

~~**FIGURE 1**~~

~~Normal ultrasonographic findings in chest ultrasound using a sector, longitudinal scan (panels A and B) and a convex array probe for an abdominal, transhepatic view of the diaphragm at both b and m-modes (panel C).~~

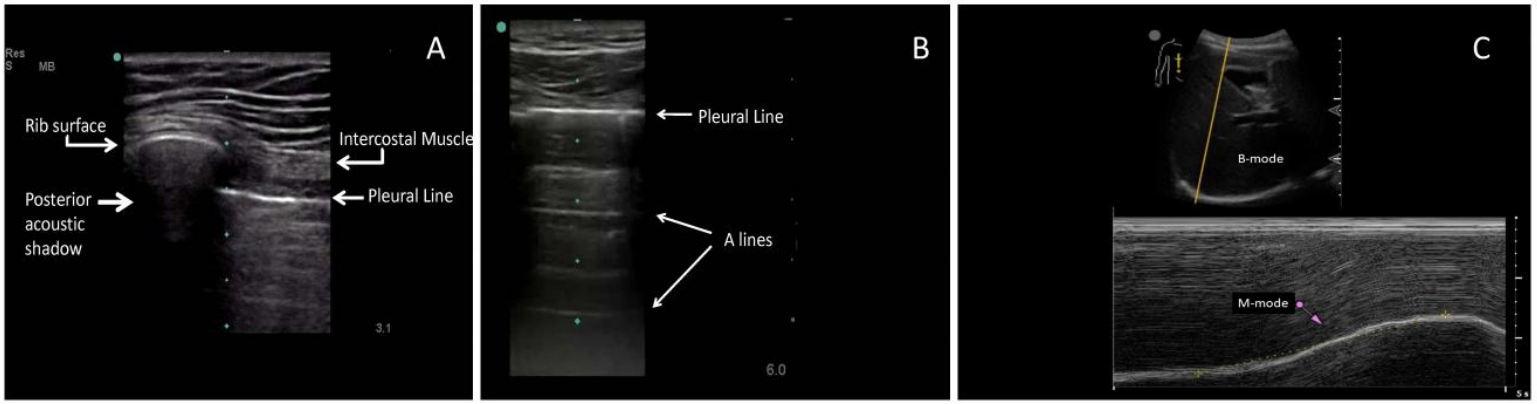

Formatted: Font: (Default) Times New Roman, 12 pt

FIGURE ~~2~~1

Principal pathologic findings at chest ultrasound using a convex probe. **A:** hyperechoic, consolidated lung parenchima (dotted line). The hyperechoic spots are consistent with an air bronchogram (continued line circle); **B:** Free flowing non septated, anechoic, pleural effusion (dotted line). The compressed lung parenchima is not ventilated and, consequently, athelectasic, clearly detectable and hypoechoic (continued line); **C:** Complex, loculated pleural effusion (dotted line) surrounding a partially collapsed lower lobe (continued line); **D:** Ultrasonographic B lines, long wide bands of hyperechoic artifact likened to the beam of a flashlight (dotted line).

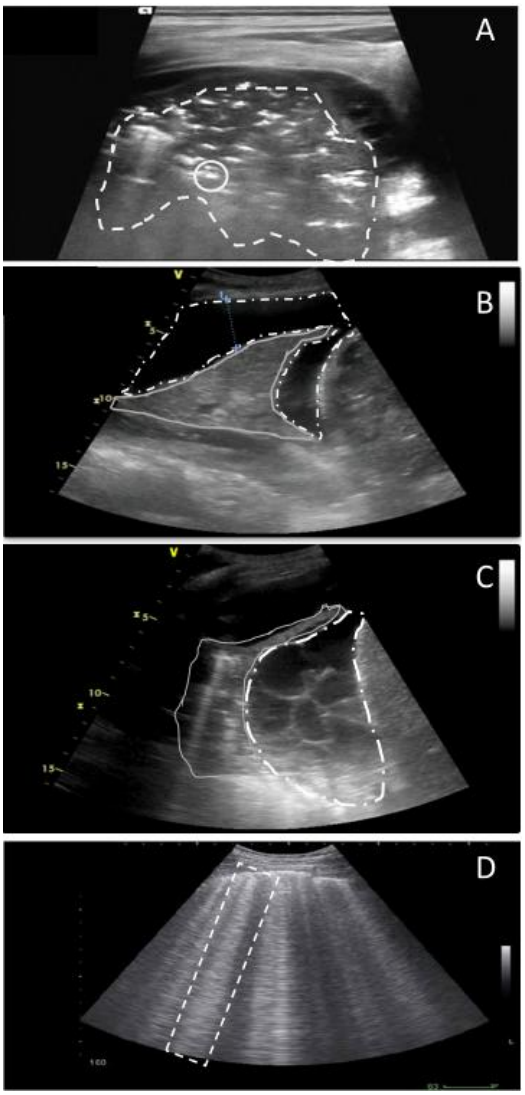

FIGURE 2

Panel 1. Ultrasound diagnosis of Pneumothorax (linear probe). In panel 1.a, the M-mode image demonstrates a linear, laminar pattern in the tissue superficial to the pleural line and a granular or "sandy" appearance deep to the pleural line, suggesting the absence of pneumothorax (seashore sign). In panel 1.b, the M-mode image shows a linear, laminar pattern in the pleural interface, and a similar linear pattern deep to the pleural line (stratosphere sign or barcode sign), indicating the presence of pneumothorax.

Panel 2. Ultrasound diagnosis of lung abscess (convex probe). Panel 2.a: Computed tomography showing a surrounding, thick and irregular consolidation containing a fluid, inner level. In panel 2.b, high amplitude echoes are clearly visible as well as multiple echogenic small air inclusions.

Panel 3. Ultrasound diagnosis of lung tumour (convex probe). Panel 3.a: Computed tomography showing a large right apical mass infiltrating the chest wall. Panel 3.b.: corresponding ultrasonographic view of a hypoechoic lesion with posterior acoustic enhancement (PAE) and irregular borders. The visceral pleura is interrupted since it is infiltrated by the tumor (white arrows).

Panel 4. Ultrasound diagnosis of malignant pleural mesothelioma (convex probe). Panel 4.a: Computed tomography of large pleural, confluent, masses (yellow arrows), wide thickening of soft tissue attenuation involving the right chest wall and the diaphragm and associated with malignant pleural effusion. Panel 4.b: Ultrasound demonstrating large, anechoic effusion, above a flattened diaphragm, extensively infiltrated by thick, irregular nodularity arising from the diaphragm and the visceral pleura.

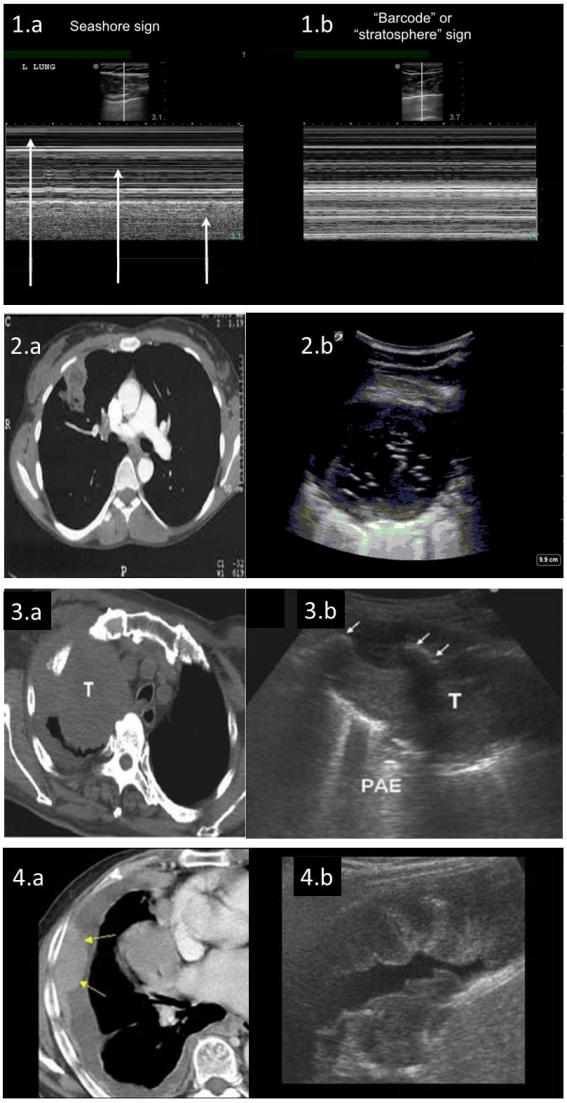

Formatted: Font: (Default) Times New Roman, 12 pt

Figure 1

Click here to download high resolution image

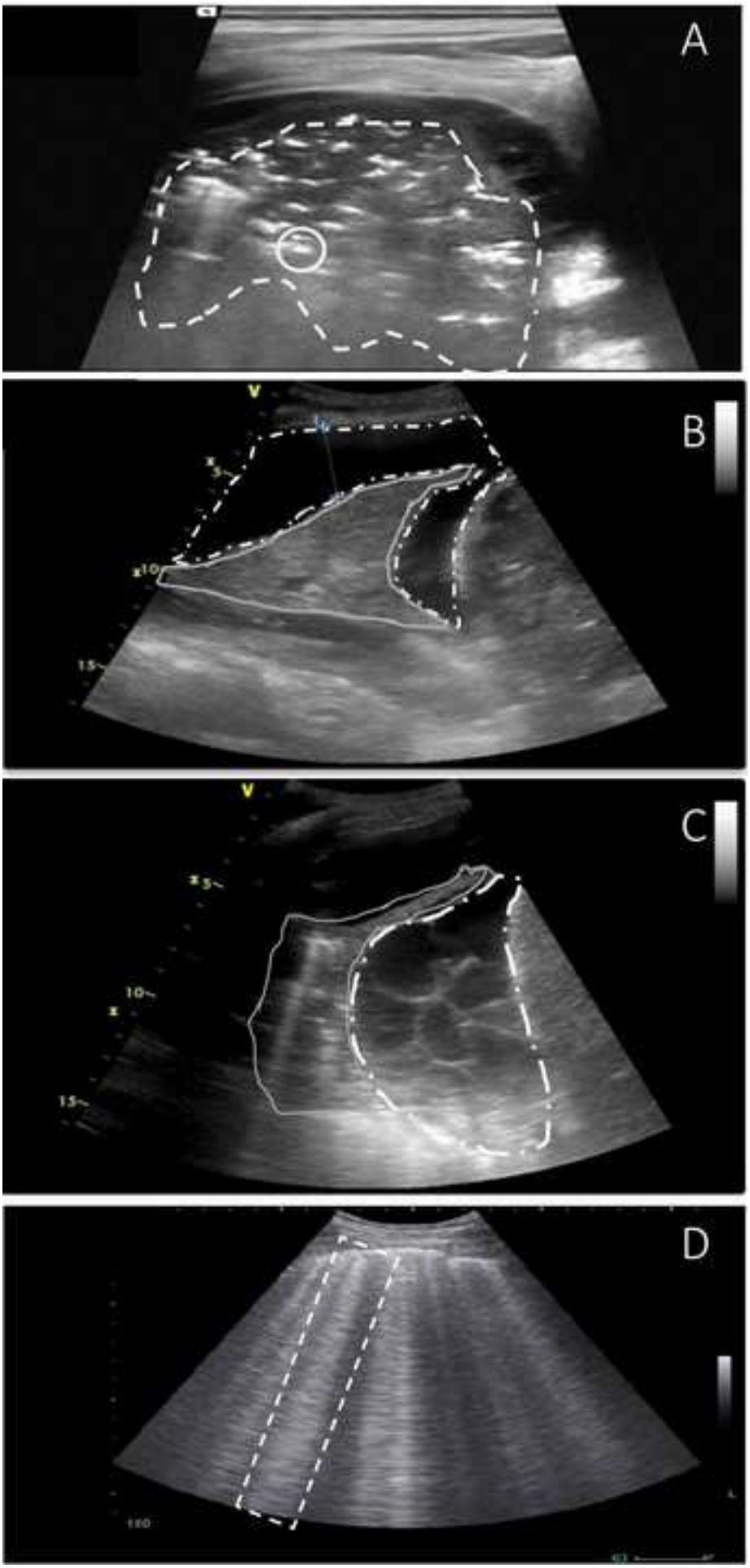

Figure 2

Click here to download high resolution image

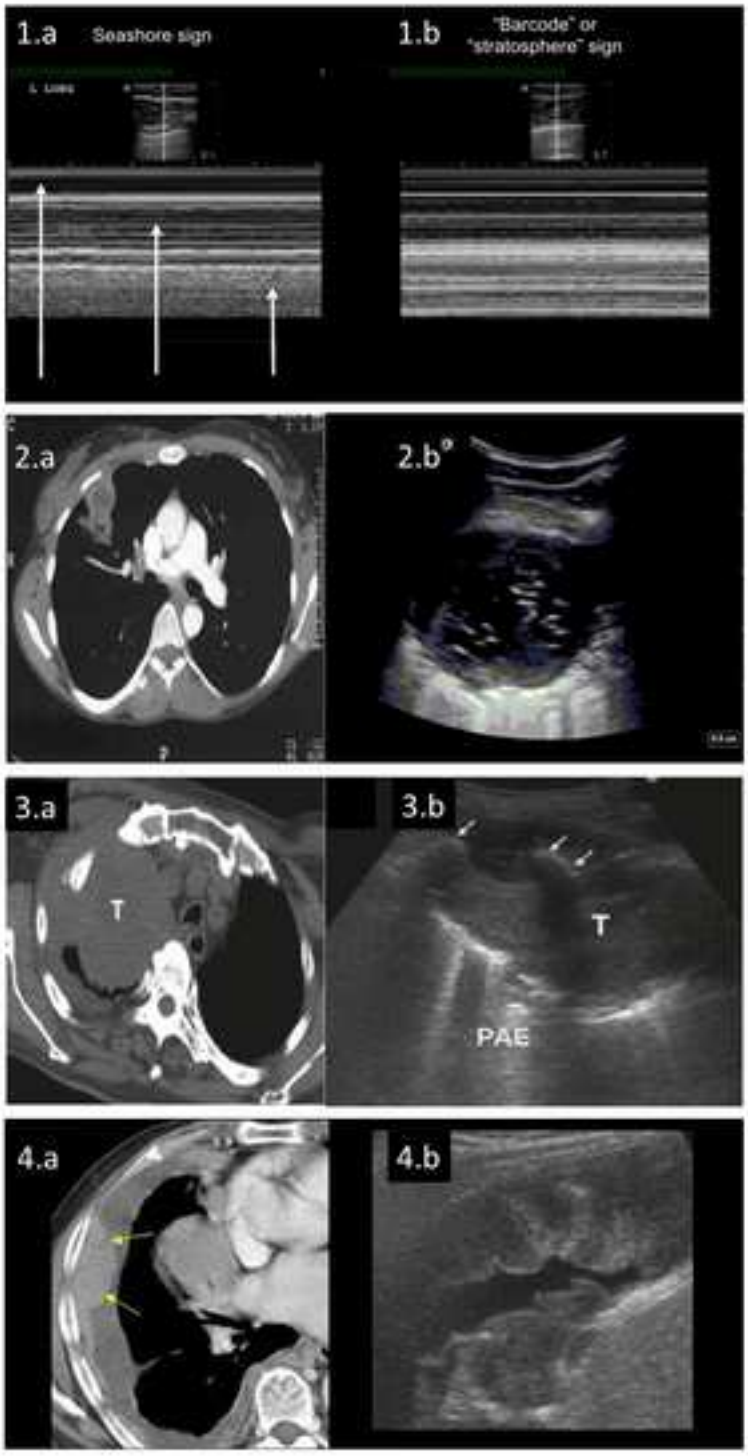

Supplementary Material

Click here to download Supplementary Material: Supplementary material revised.docx