

# Case report of a familial triple: a syndrome and review of the literature

Federica Gaiani, MD<sup>a,\*</sup>, Pierpacifico Gismondi, MD<sup>b</sup>, Roberta Minelli, MD, PhD<sup>a</sup>, Giovanni Casadio, MD<sup>c</sup>, Nicola de'Angelis, MD, PhD<sup>d</sup>, Fabiola Fornaroli, MD<sup>a</sup>, Gian Luigi de'Angelis, MD, PhD<sup>a</sup>, Marco Manfredi, MD<sup>e</sup>

## Abstract

**Rationale:** Triple-A syndrome, or Allgrove syndrome (AS), is a rare autosomal recessive disorder characterized by the alacrimia, achalasia, and adrenal insufficiency triad. Alacrimia usually starts at early infancy, while achalasia and adrenal insufficiency appear later during childhood or adulthood. Some patients may also present with the so-called Double-A syndrome (i.e., alacrimia and achalasia, or alacrimia and adrenal insufficiency); adrenal insufficiency usually represents a life-threatening event due to severe hypoglycemia. Many patients may also present other associated manifestations, such as neurological disorders. We describe, here, 2 sisters of non-consanguineous parents.

**Patient concerns:** An 8-year-old girl was admitted to the Pediatric Care Unit of Parma after an episode characterized by seizure with loss of consciousness and generalized hypertonia lasting a few minutes. Her sister, a 6-year-old girl, presented with recurrent episodes of vomiting and failure to thrive.

**Diagnoses:** Both children were investigated by laboratory tests, esophagogastroduodenoscopy, and imaging. The first patient had the complete triad of AS (alacrimia, achalasia, adrenal insufficiency), while the second one presented only alacrimia and achalasia. Both resulted from a mutation in the achalasia, addisonianism, alacrimia syndrome gene.

**Interventions:** Both patients were treated with oral hydrocortisone for Addison disease, and with artificial tears in the first case. After many pneumatic endoscopic dilations and therapy with nifedipine, both patients underwent surgical Heller myotomy for achalasia.

**Outcomes:** A rapid and favorable recovery to normal diet and with improvement of growth parameters was obtained. These cases are also compared with the literature data, reported in a brief review.

**Lessons:** AS is a rare multisystemic disorder. The longer diagnosis is delayed, the greater extent to which this syndrome may be life-threatening, mainly because of hypoglycemia due to adrenal insufficiency. In AS, the red-flag symptom of alacrimia should instigate investigation for achalasia, Addison disease, and achalasia, addisonianism, alacrimia syndrome gene mutation.

**Abbreviations:** AAAS = achalasia, addisonianism, alacrimia syndrome, ACTH = adreno-cortico-tropic hormone, AS = Allgrove syndrome.

**Keywords:** achalasia, Addison disease, alacrimia, Allgrove syndrome, case report, familial cases

Editor: Maya Saranathan.

Written informed consent was obtained from the patients' parents for publication of this case report and any accompanying images. A copy of the written consent is available for review by the Editor of this journal.

The authors have read the CARE checklist (2016), and the manuscript was prepared and revised according to the CARE checklist (2016).

The authors have no funding and conflicts of interest to disclose.

Data sharing not applicable to this article as no datasets were generated or analyzed during the current study.

<sup>a</sup>Gastroenterology and Endoscopy Unit, University Hospital of Parma, University of Parma, <sup>b</sup>Pediatric Clinic, <sup>c</sup>Pediatric Surgery, "Pietro Barilla" Children's Hospital, University Hospital of Parma, Parma, Italy, <sup>d</sup>Department of Digestive, Hepatobiliary Surgery and Liver Transplantation, Henri Mondor University Hospital, Créteil, France, <sup>e</sup>Pediatric Unit, Maternal and Child Department, Azienda USL of Reggio Emilia, Sant'Anna Hospital, Castelnovo ne' Monti, Italy.

\* Correspondence: Federica Gaiani, Gastroenterology and Endoscopy Unit, University Hospital of Parma, University of Parma, via Gramsci 14, Parma 43126, Italy (e-mail: federica.gaiani@unipr.it).

Copyright © 2020 the Author(s). Published by Wolters Kluwer Health, Inc.

This is an open access article distributed under the Creative Commons Attribution License 4.0 (CCBY), which permits unrestricted use, distribution, and reproduction in any medium, provided the original work is properly cited.

How to cite this article: Gaiani F, Gismondi P, Minelli R, Casadio G, de'Angelis N, Fornaroli F, de'Angelis GL, Manfredi M. Case report of a familial triple: a syndrome and review of the literature. *Medicine* 2020;99:22(e20474).

Received: 24 November 2019 / Received in final form: 14 March 2020 / Accepted: 28 April 2020

<http://dx.doi.org/10.1097/MD.00000000000020474>

## 1. Introduction

Triple-A syndrome, or Allgrove syndrome (AS) (OMIM #231550), first described by Allgrove in 1978,<sup>[1]</sup> is a rare disease characterized by adrenal insufficiency, achalasia, and alacrimia, and it can be variably associated with autonomic nervous system dysfunction and neurodegeneration. AS is an autosomal recessive disorder due to a mutation in the achalasia, Addisonianism, alacrimia syndrome (AAAS) gene localized on chromosome 12q13 and coding for a protein called alacrimia, achalasia, adrenal insufficiency, neurologic disorder (commonly referred to as ALADIN), which is involved in transductional intracellular pathways.<sup>[1,2]</sup>

The characteristic triad of AS may manifest incompletely, but at least 2 features are necessary to make the clinical diagnosis, then being the so-called “double-A syndrome”.<sup>[3]</sup> When autonomic nervous system dysfunctions are present, followed by a central and peripheral nervous system involvement (muscular atrophy, fasciculation, hypoesthesia, nasal speech, ataxia, optic atrophy, and intellectual impairment), the so-called “4A syndrome” is diagnosed.<sup>[4–8]</sup> Moreover, when spinal amyotrophy appears, we can talk about “5A syndrome”.<sup>[9]</sup>

In AS, the onset of clinical features may not be simultaneous. Alacrimia represents the earliest and the most constant symptom, and it usually presents at birth. The symptoms of achalasia, the main complaint leading to specialist consultation, and adrenal insufficiency, due to glucocorticoid secretion deficiency, appear later during childhood or adulthood. Adrenal insufficiency is reported in 85% of patients, whereas mineralocorticoid impairment affects only about 15% of the patients. According to the overall literature data, the full triad is found in almost two-thirds of patients, 2 symptoms in one-third, and 1 symptom alone in less than 10%.<sup>[10,11]</sup>

## 2. Methods

We retrospectively analyzed the cases of 2 pediatric patients with AS diagnosed, treated, and followed-up in our institution since. This case presentation was conducted in accordance with the Declaration of Helsinki. The CARE guidelines were followed in accordance with the journal policies.

### 2.1. Case 1 presentation

An 8-year-old girl was admitted to the Pediatric Care Unit of Parma after an episode characterized by seizure with loss of consciousness and generalized hypertonia lasting a few minutes.

**2.1.1. Physical examination.** Glasgow coma scale score was 10/15, and the patient did not react to verbal stimuli. Temperature and vital signs were normal. The physical examination showed xerosis cutis, skin hyperpigmentation, and no subcutaneous fat thickness; she had a normal vesicular murmur associated with crackling lung sounds. Heart rate and heart sounds were normal.

**2.1.2. Laboratory examinations.** C-reactive protein was slightly increased (24.4 mg/L; normal range: 0–5 mg/L) and blood glucose level was very low (20 mg/dL; normal range: 60–100 mg/dL). The patient was treated with a glucosaline solution, and experienced a progressive restoration of consciousness. The immunological pattern (lymphocytes and serum immunoglobulin, islet cell auto-antibodies, enzyme glutamic acid decarboxylase, antithyroglobulin antibodies, antithyroperoxidase antibodies, anti-adrenal autoantibodies), angiotensin converting enzyme and tuberculin skin test results were all within normal limits.

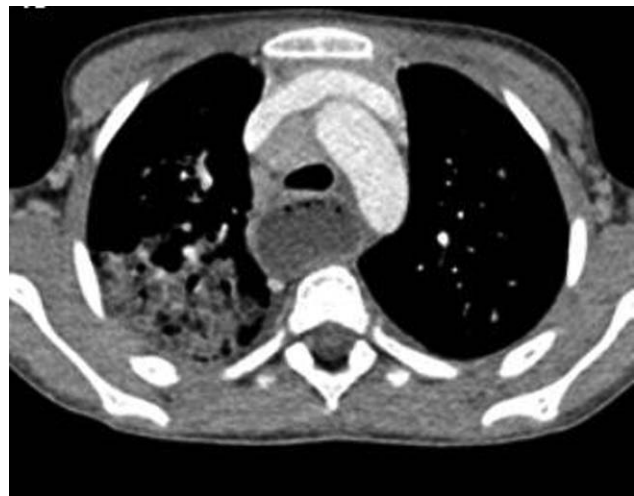**2.1.3. Imaging examinations.** The electroencephalography, electrocardiography and brain CT-scan findings, blood cell count, liver and renal function markers, and electrolytes were normal. The brain MRI showed a normal pattern of cerebral tissue, while the optic nerve appeared presumably reduced in thickness. On the contrary, electromyography was normal.

**2.1.4. Past and familial history.** The patient is the third of 4 children of Moroccan non-consanguineous parents. She was born via natural vaginal delivery after a full-term, uncomplicated pregnancy. The parents reported a normal achievement of psychomotor milestones. The patient received all routine childhood vaccinations, took no medications, and had no known allergies. At time of diagnosis, she had a living, apparently healthy, younger sister. Two other siblings died in Morocco due to unknown causes, at the ages of 18 months and 6 years, respectively. The father was in apparent good health, and the mother had undergone cardiosurgical valvuloplasty and pacemaker implantation to address an unspecified cardiac disease.

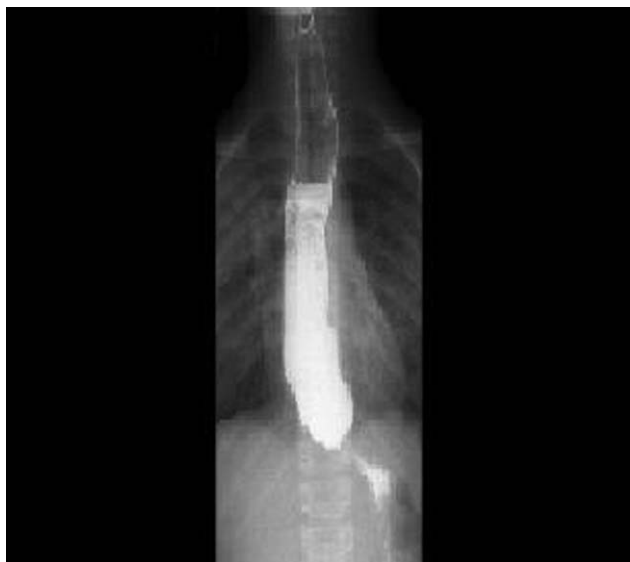
**2.1.5. Further diagnostic work-up.** Because of the extremely low blood glucose level and the hyperpigmentation, the patient's endocrinological features were investigated. An extremely high blood adrenocorticotrophic hormone (ACTH) level (2645 pg/mL; normal range: 5–49 pg/mL) and low blood cortisol level (2.0 µg/dL; normal range: 6.7–22.3 µg/dL) were found; therefore, Addison disease was diagnosed. Normal mineralocorticoid activity was confirmed by physiological aldosterone levels.

During the patient's admission, she presented a persistent cough, constant high inflammatory markers, and crackling bilateral lung sounds. A chest x-ray was performed, which showed bilateral pneumonia and enlarged mediastinal lymph nodes. The subsequent chest CT-scan showed right parenchymal lobar pneumonia associated with air bronchogram, diffuse “ground glass” images, and multiple mediastinal enlarged lymph nodes. Furthermore, it showed an entirely dilated esophagus filled with solid material (Fig. 1).

After a detailed history-taking, the parents reported progressive dysphagia, failure to thrive, weight loss during the last



**Figure 1.** Chest computed tomography scan showing right parenchymal lobar pneumonia associated with air bronchogram, diffuse “ground glass” images, multiple mediastinal enlarged lymph nodes, and a dilated esophagus filled with solid material.



**Figure 2.** Barium swallow showing a dilation of the esophagus, narrow esophago-gastric junction with a “bird beak” appearance, aperistalsis, and a poor emptying of the barium.

6 months, and crying without tears since birth. Therefore, upper gastrointestinal and bronchial endoscopies were performed, showing a dyskinetic esophagus and purulent secretion in the bronchial tree. The barium swallow showed dilation of the esophagus, narrow esophagogastric junction with a “bird beak” appearance, aperistalsis, and a poor emptying of the barium (Fig. 2). The subsequent esophageal manometry exam showed normal pressure of the upper esophageal sphincter and coordination between the pharynx and esophagus, an absent esophageal peristalsis but simultaneous uncoordinated contractions, and an augmented lower esophageal sphincter pressure, confirming esophageal achalasia.

Moreover, Schirmer test showed hypolacrimia in both eyes (< 5 mm).

## 2.2. Case 2 presentation

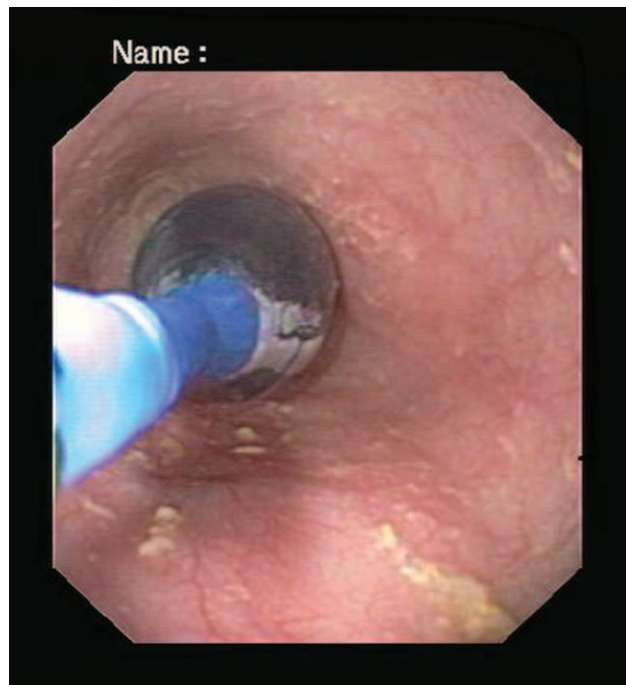
During the diagnostic workup, the sister of the patient presented in case 1 was investigated. She was a 6-year-old girl, presenting with recurrent episodes of vomiting and failure to thrive.

**2.2.1. Diagnostic work-up.** The patient underwent the same diagnostic procedures as her sister (barium swallow, upper gastrointestinal endoscopy, esophageal manometry, Schirmer test), according to suspicion of the same disease. All the tests confirmed esophageal achalasia and alacrimia. The ACTH test result was within the normal range.

The coexistence of adrenal insufficiency, achalasia, and alacrimia lead to suspect AS, therefore genetic testing for AS was performed.

## 2.3. Therapeutic approach

For the first child, a substitutive therapy with intravenous hydrocortisone was initially administered. The therapy was eventually shifted to oral administration, with no side effects. During the hospitalization, she also underwent 3 esophageal balloon dilations (Fig. 3) and began a pharmacological therapy



**Figure 3.** Esophageal pneumatic endoscopic dilation. The balloon was inflated under fluoroscopic control and left in the site for about 1 minute.

with nifedipine (1.5 mg/kg/die t.i.d.); 17 days later, the girl started a gradual progressive oral refeeding, without dysphagia. Dysphagia and other symptoms such as drooling and weight gain were carefully monitored during the follow-up between 2 dilation sessions. The patient was discharged on therapy with oral hydrocortisone (0.75 mg/kg/die t.i.d.) and nifedipine (1.5 mg/kg/die t.i.d.). A week later, the patient’s conditions had improved; blood samples demonstrated a normalization of the inflammatory markers, and blood ACTH level of 1213 pg/mL. She had gained 1.5 kg of weight from the first day of admittance.

For her sister (case 2), a therapy with nifedipine was started and periodic pneumatic endoscopic dilations were performed (Fig. 3).

For both sisters, despite therapy with periodic pneumatic endoscopic dilations, frequent episodes of vomiting and the failure to thrive continued. So, a surgical laparoscopic Heller myotomy was performed without complications after 36 months from diagnosis, and 7 endoscopic dilations were performed for the first child after 25 months and 6 endoscopic dilations for her sister.

## 2.4. Final diagnosis

The final diagnosis of the 2 presented cases was AS. The syndrome was confirmed by genetic testing; both sisters were found to be homozygous for the variant c.1024C>T (p. Arg342Term) of the AAAS gene (a nonsense mutation). For the second child, the ACTH was within normal range and the double-A syndrome was diagnosed.

## 2.5. Outcome and follow-up

Both sisters were discharged at day 7 after their surgical procedure and with a normal diet. Nifedipine was gradually

withdrawn, with good compliance. The clinical examination at follow-up 6 months after surgery showed good clinical conditions, a complete tolerance of a conventional diet, and regular growth parameters.

### 3. Discussion

AS is a rare disease with still unknown prevalence and an autosomal recessive pattern of inheritance. The 3 pathognomonic clinical manifestations are alacrimia, Addison disease, and achalasia. Although some authors consider achalasia<sup>[12]</sup> to be the first manifestation of the disease, alacrimia seems to be the earliest symptom,<sup>[13]</sup> although it can remain undiagnosed for a long time, mainly just until an accurate history-taking is performed with parents. Other authors have stated that achalasia most probably appears later, often during adolescence or pre-adolescence.<sup>[14]</sup>

Alacrimia itself is a rare condition, either congenital or acquired. It can be part of familial dysautonomia, lacrimoauriculodentodigital syndrome, the anhidrotic type of ectodermal dysplasia, Sjögren syndrome, congenital disorder of deglycosylation, the alacrimia, achalasia mental retardation syndrome, and triple-A syndrome. Alacrimia is very unlikely to be an isolated finding in children; therefore, children should always be further investigated if the parents report “crying without tears”. The gold standard of diagnosis is Schirmer test, and the therapy is represented by a symptomatic approach (artificial tears and eye drops).<sup>[14]</sup>

Derrar et al<sup>[25]</sup> described 3 African children, of 4, 5, and 7 years of age respectively, all presenting dry eye associated to achalasia with normal adrenal function. A French report<sup>[7]</sup> described 14 patients affected by AS, ranging in age from 10 to 79 years, among whom the complete triad (alacrimia, achalasia, and adrenal insufficiency) was present in only 9 of the cases. Alacrimia was the earliest symptom, starting in the neonatal period. The mean age of onset of the first symptom leading to consultation was 7 years (2–13 years). However, adrenal insufficiency, achalasia and neurologic disorders were the first evidence of triple-A syndrome in 9, 3, and 2 of those patients, respectively.

Addison disease is characterized by adrenal insufficiency. In AS, the glucocorticoid function is lacking, while the mineralocorticoid function is not usually affected.

Acute adrenal insufficiency is an acute lack of glucocorticoid activity. It is usually triggered by viral infections and it is characterized by fatigue, anorexia, vomiting, abdominal pain, cyanosis, cold extremities, hypotension, increased heart rate, and weak pulse, and it can be life-threatening if misdiagnosed.<sup>[15]</sup> Kurnaz et al<sup>[16]</sup> evaluated 6 patients, all children of consanguineous parents and with a clinical diagnosis of AS. All of the children had both adrenal insufficiency and alacrimia, and only 4 presented achalasia. Four children presented with seizure, while 2 presented with recurrent vomiting and weakness. Low blood glucose level was present in 3 out of the 6 total children. One of these patients had a novel mutation in exon 14 of the AAAS gene.

Achalasia is a primary motor disorder of the esophagus, characterized by lower esophageal sphincter impaired relaxation and a loss of esophageal peristalsis due to an imbalance between excitatory and inhibitory neurons caused by inflammation, fibrosis, and degeneration of the inhibitory myenteric plexus. Clinical presentation varies from regurgitation of ingested food (described as vomiting immediately after meals), progressive

dysphagia to solids and liquids, a deficit of growth parameters or weight loss, and repeated aspiration pneumonia.<sup>[17]</sup> The diagnosis of achalasia is supported by results from barium swallow (dilation of the esophagus, narrow esophagus with a “bird beak” appearance, aperistalsis, and poor emptying of the barium) and esophageal manometry. The upper endoscopy procedure aims to assess the proximal dilatation of the esophagus and the presence of retained food material in the distal esophagus, and to exclude any other diseases (i.e., esophagitis, *Trypanosoma cruzi*, malignancy, and other secondary causes of achalasia).<sup>[18]</sup>

Esophageal achalasia usually requires a combined approach that includes endoscopic pneumatic dilations and a pharmacological therapy with nifedipine, with eventual surgery (Heller myotomy) in cases in which cardiac stenosis persists. Actually, patients affected by achalasia usually undergo several endoscopic dilations during their lifetime, but most cases eventually require surgical intervention. Nifedipine is only a short-term therapy because it does not correct the anatomical condition, and it is associated with possible side effects (flushing and hypotension). Recently, botulinum toxin injection into the lower esophageal sphincter has been suggested, exploiting its relaxing activity on muscular fibers; however, its activity lasts only months to years and it is only a transient correction,<sup>[19]</sup> making it not often considered, especially in pediatric age patients, due to risks and the limited duration.

Considering that the presentation of AS may vary widely in terms of timing, age of onset, and coexisting disorders, the final diagnosis is often difficult and delayed.<sup>[20]</sup> Available literature data and case reports confirm the rarity of this syndrome and the variety of symptoms or associated diseases, mostly neurologic disorders, abnormal skin pigmentation, or edentulism, which may even precede the cardinal clinical manifestations. Moreover, although the onset in pediatric age and familiarity are usual, reports also describe adult-age onsets and unrelated cases.<sup>[21–23]</sup> A review of the literature is presented in Table 1.

Several papers have reported on hypoglycemic seizures as the first clinically relevant event,<sup>[5,14,24]</sup> while other patients come to the attention of clinicians due to the onset of various neurologic disorders, such as optic neuropathy, amyotrophy, gait impairment, or ataxia.<sup>[23,25,26]</sup>

Tibussek et al<sup>[10]</sup> described 2 unrelated cases affected by AS. The first involves a 3.5-year-old girl hospitalized for repeated hypoglycemic myoclonic events. The diagnostic exams that followed revealed adrenal insufficiency and alacrimia (present since early infancy) but no achalasia. The genetic research confirmed the presence of the AAAS gene mutation. The second patient, an 8-month-old boy suffering from anisocoria, was diagnosed with unilateral optic atrophy and cerebellar vermis hypotrophy. Because of several episodes of vomiting and failure to thrive, achalasia was also diagnosed. The boy's mother reportedly mentioned the absence of tears since birth, leading to the clinical diagnosis of AS. However, the results of investigation of the common associated genetic mutations was negative.<sup>[14]</sup>

Edentulism<sup>[12,24]</sup> and abnormal skin pigmentation<sup>[7,27–30]</sup> are other rare and unusual presentations, which should however lead to further investigations for AS.

Vahedi et al<sup>[12]</sup> described a young edentulous boy with the triad of AS suffering from pain associated with dysphagia, vomiting, and weight loss. After surgical Heller myotomy and supplementation of hydrocortisone, the boy's symptoms, and growth rate improved, so that he achieved a normal development. This patient had 1 sister with the same clinical characteristics.<sup>[12]</sup>

**Table 1**  
Review of the literature, case reports, and case series of Allgrove syndrome.

Author	Year	Patients, n	Familiarity among cases	Age in yr, mean	Sex	Symptoms at presentation	Typical manifestations	Other clinical manifestations	Genetic confirmation	Treatment
Houlden et al <sup>[6]</sup>	2002	20	No	3–25	M/F	Dysphagia, ataxia, visual impairment	Alacrimia, achalasia, adrenal insufficiency	Neurologic disorders	Yes	N/A
Kimber et al <sup>[5]</sup>	2003	3	Yes	40–60 (48.3)	M (2); F (1)	Dysphagia, weakness, visual impairment	Alacrimia, achalasia	Multiple neurologic and autonomic disorders, gonadotropic disorders	Yes	N/A
Nakamura et al <sup>[21]</sup>	2010	1	N/A	40	M	Dysphagia, autonomic disorders	Alacrimia, achalasia	Neurologic disorders	Yes	N/A
Razavi et al <sup>[24]</sup>	2010	4	Yes	6–15 (11)	M (1); F (3)	Hypoglycemic seizures, vomit	Alacrimia, adrenal insufficiency, achalasia	Edentulism, hearing deficit, neurodevelopmental delay	Yes	N/A
Kilicli et al <sup>[11]</sup>	2012	1	N/A	23	F	Tachycardia, sweating, fatigue	Alacrimia, adrenal insufficiency, achalasia	Urinary tract infection, melena	No	Heller myotomy, hydrocortisone, artificial tears
Bizzarri et al <sup>[26]</sup>	2013	1	N/A	13	M	Addison disease, dysphagia, fatigue, ataxia	Adrenal insufficiency, achalasia	Neurologic disorders, cryptorchidism	Yes	Heller myotomy, hydrocortisone
Sanyal et al <sup>[9]</sup>	2013	1	N/A	22	M	Erectile dysfunction, dizziness, hypotension	Alacrimia, adrenal insufficiency, achalasia	Neurologic (autonomic) disorders, hyperpigmentation	Yes	N/A
Alakeel et al <sup>[29]</sup>	2015	1	N/A	4	F	Oral hyperpigmentation and diffusely acquired melanoderma, alacrimia	Alacrimia, adrenal insufficiency, achalasia	N/A	Yes	Endoscopic dilation, hydrocortisone, artificial tears
Derrar et al <sup>[25]</sup>	2015	3	Yes	4–7 (8)	M (1); F (2)	Visual impairment, vomit	Alacrimia, achalasia	Corneal damage	No	Heller myotomy, artificial tears
Misgar et al <sup>[27]</sup>	2015	3	N/A	18	M	Fatigue	Alacrimia, adrenal insufficiency, achalasia	Hyperpigmentation	N/A	Heller myotomy, hydrocortisone
Li et al <sup>[7]</sup>	2015	3	No	2.6–7.5 (4.7)	M (1) F (2)	Vomit, hyperpigmentation	Alacrimia, adrenal insufficiency, achalasia	Neuropathy (1), hyperpigmentation (3)	Yes	N/A
				0.7	M	Vomit, failure to thrive	Achalasia, alacrimia	Anisocoria for unilateral optic atrophy and cerebellar vermis hypotrophy	No	N/A
Brown et al <sup>[30]</sup>	2016	1	N/A	6	F	Pain, vomit, fatigue, fever	Alacrimia, adrenal insufficiency, achalasia	Gingival hypertrophy, hyperpigmentation of the buccal mucosa and gingiva	Yes	Heller myotomy, hydrocortisone, artificial tears
Jerie et al <sup>[22]</sup>	2016	1	N/A	36	F	Dysphagia, gait impairment	Alacrimia, adrenal insufficiency, achalasia	Neurologic disorders	Yes	N/A
Kalabi et al <sup>[8]</sup>	2016	26	No	1–10 (2.9)	M (12); F (14)	Seizures, neurologic impairment, dysphagia	Alacrimia (26); Achalasia (23); adrenal insufficiency (26)	Neurologic disorders	Yes	N/A
Vahedi et al <sup>[12]</sup>	2016	2	Yes	15	M (1); F (1)	Vomit, failure to thrive, pain	Alacrimia, achalasia, adrenal insufficiency	Edentulism	No	Hydrocortisone; Heller myotomy
van Tellinggen et al <sup>[20]</sup>	2016	1	N/A	4	M	Hypothyroidism, mental retardation	Alacrimia, adrenal insufficiency, achalasia	Hypothyroidism	Yes	Endoscopic dilation, hydrocortisone, artificial tears
Berrani et al <sup>[28]</sup>	2018	2	Yes	1	F	Fatigue, vomit	Alacrimia, adrenal insufficiency, achalasia	Hyperpigmentation, failure to thrive, autonomic dysfunction	Yes	Endoscopic dilation, hydrocortisone, artificial tears
				2.6	M	Fatigue, anorexia		Hyperpigmentation, failure to thrive, partial loss of primary dentition		
de Freitas et al <sup>[23]</sup>	2018	1	N/A	25	M	Weakness and amyotrophy of limbs	Alacrimia, achalasia	Neurologic disorders	Yes	N/A
Kurnaz et al <sup>[16]</sup>	2018	6	Yes	3–7.5 (4.5)	M (5); F (1)	Seizure (4) Vomit, fatigue (2) Hypoglycemia (3)	Alacrimia, adrenal insufficiency (6) Achalasia, alacrimia, adrenal insufficiency (4)	Neurologic disorders	Yes	N/A

Brown et al.<sup>[30]</sup> described a 6-year-old girl who presented with diffuse intermittent abdominal pain, vomiting, fatigue, and fever. The medical history of the patient revealed a presumed diagnosis of gastroesophageal reflux at the age of 5 years. Diagnostic tests showed adrenal insufficiency with gingival hypertrophy, and hyperpigmentation of the buccal mucosa and gingiva. At 2 years of age, she stopped having overflow tears. The genetic research confirmed the mutation in the AAAS gene.<sup>[30]</sup>

#### 4. Conclusion

AS is a rare multisystemic disorder. The longer diagnosis is delayed, the greater extent to which this syndrome may be life-threatening, mainly because of hypoglycemia due to adrenal insufficiency. Clinically, alacrimia can be considered the red-flag symptom of AS,<sup>[15]</sup> although the disorder could remain undiagnosed for a long time. Moreover, other unspecific associated disorders could precede the cardinal symptoms of AS, among which some could be considered more suspicious, such as edentulism and abnormal hyperpigmentation. Overall, in all patients presenting alacrimia, mutations of the AAAS gene should be always verified to avoid diagnostic delay of AS. On the contrary, achalasia, and adrenal insufficiency usually begin later, during childhood or adolescence, although often before the neurological manifestations.<sup>[3,31]</sup> Each of these pathognomonic signs and symptoms should always be considered in association and carefully investigated, as the earlier and more precise is the diagnosis, the better is the clinical outcome.

#### Acknowledgments

We gratefully acknowledge the patients and their family for collaboration.

#### Author contributions

Gaiani F, Gismondi P, Manfredi M and de'Angelis GL conceived of the study; Gaiani F, Manfredi M, Casadio G and Fornaroli F wrote the manuscript; Minelli R, de'Angelis N and de'Angelis GL revised the manuscript for important intellectual content. All authors approved the final version.

#### References

- [1] Handschug K, Sperling S, Yoon SJ, et al. Triple A syndrome is caused by mutations in AAAS, a new WD-repeat protein gene. *Hum Mol Genet* 2001;10:283–90.
- [2] Prpic I, Huebner A, Persic M, et al. Triple A syndrome: genotype-phenotype assessment. *Clin Genet* 2003;63:415–7.
- [3] Patt H, Koehler K, Lodha S, et al. Phenotype-genotype spectrum of AAA syndrome from Western India and systematic review of literature. *Endocr Connect* 2017;6:901–13.
- [4] Aragona P, Rania L, Roszkowska AM, et al. 4A syndrome: ocular surface investigation in an Italian young patient. *BMC Ophthalmol* 2014;14:155. Published 2014 Dec 8. doi:10.1186/1471-2415-14-155.
- [5] Kimber J, McLean BN, Prevett M, et al. Allgrove or 4 "A" syndrome: an autosomal recessive syndrome causing multisystem neurological disease. *J Neurol Neurosurg Psychiatry* 2003;74:654–7.
- [6] Houlden H, Smith S, de Carvalho M, et al. Clinical and genetic characterization of families with triple A (Allgrove) syndrome. *Brain* 2002;125(Pt 12):2681–90.
- [7] Li W, Gong C, Qi Z, et al. Identification of AAAS gene mutation in Allgrove syndrome: a report of three cases. *Exp Ther Med* 2015;10:1277–82.
- [8] Kallabi F, Belghuith N, Aloulou H, et al. Clinical and genetic characterization of 26 Tunisian patients with Allgrove syndrome. *Arch Med Res* 2016;47:105–10.
- [9] Sanyal D, Bhattacharjee S. A case of late-onset Allgrove syndrome presenting with predominant autonomic dysfunction. *Ann Indian Acad Neurol* 2013;16:266–8.
- [10] Roucher-Boulez F, Brac de la Perriere A, Jacquez A, et al. Triple-A syndrome: a wide spectrum of adrenal dysfunction. *Eur J Endocrinol* 2018;178:199–207.
- [11] Kilicli F, Acibucu F, Senel S, et al. Allgrove syndrome. *Singapore Med J* 2012;53:e92–4.
- [12] Vahedi M, Fathi S, Allahbakhshi H. Edentulous child with Allgrove syndrome: a rare case report. *Korean J Pediatr* 2016;59:456–9.
- [13] Ornek K, Atilla H, Zilelioglu G. Pediatric alacrima, achalasia, and mental retardation. *J AAPOS* 2002;6:261–3.
- [14] Tibussek D, Ghosh S, Huebner A, et al. "Crying without tears" as an early diagnostic sign-post of triple A (Allgrove) syndrome: two case reports. *BMC Pediatr* 2018;18:6. Published 2018 Jan 15. doi:10.1186/s12887-017-0973-y.
- [15] Husebye ES, Allolio B, Arlt W, et al. Consensus statement on the diagnosis, treatment and follow-up of patients with primary adrenal insufficiency. *J Intern Med* 2014;275:104–15.
- [16] Kurnaz E, Duminuco P, Aycan Z, et al. Clinical and genetic characterisation of a series of patients with triple A syndrome. *Eur J Pediatr* 2018;177:363–9.
- [17] Hallal C, Kieling CO, Nunes DL, et al. Diagnosis, misdiagnosis, and associated diseases of achalasia in children and adolescents: a twelve-year single center experience. *Pediatr Surg Int* 2012;28:1211–7.
- [18] Chuah SK, Hsu PI, Wu KL, et al. 2011 update on esophageal achalasia. *World J Gastroenterol* 2012;18:1573–8.
- [19] Lee CW, Kays DW, Chen MK, et al. Outcomes of treatment of childhood achalasia. *J Pediatr Surg* 2010;45:1173–7.
- [20] van Tellingen V, Finken MJ, Israels J, et al. Poorly controlled congenital hypothyroidism due to an underlying Allgrove syndrome. *Horm Res Paediatr* 2016;86:420–4.
- [21] Nakamura K, Yoshida K, Yoshinaga T, et al. Adult or late-onset triple A syndrome: case report and literature review. *J Neurol Sci* 2010;297:85–8.
- [22] Jerie M, Vojtech Z, Malikova H, et al. Allgrove syndrome with prominent neurological symptoms. Case report. *Neuro Endocrinol Lett* 2016;37:184–8.
- [23] de Freitas MRG, Orsini M, Araujo APQC, et al. Allgrove syndrome and motor neuron disease. *Neurol Int* 2018;10:7436. Published 2018 Jul 4. doi:10.4081/ni.2018.7436.
- [24] Razavi Z, Taghdiri MM, Eghbalian F, et al. Premature loss of permanent teeth in Allgrove (4A) syndrome in two related families. *Iran J Pediatr* 2010;20:101–6.
- [25] Derrar R, Boutimzine N, Laghmari A, et al. Congenital alacrima revealing a Allgrove syndrome: report of three cases. *Pan Afr Med J* 2015;20:359. Published 2015 Apr 14. doi: 10.11604/pamj.2015.20.359.4717.
- [26] Bizzarri C, Benevento D, Terzi C, et al. Triple A (Allgrove) syndrome: an unusual association with syringomyelia. *Ital J Pediatr* 2013;39:39. Published 2013 Jun 24. doi:10.1186/1824-7288-39-39.
- [27] Misgar RA, Pala NA, Ramzan M, et al. Allgrove (Triple A) syndrome: a case report from the Kashmir Valley. *Endocrinol Metab (Seoul)* 2015;30:604–6.
- [28] Berrani H, Meskini T, Zerkaoui M, et al. Clinical and molecular report of c.1331 + 1G > A mutation of the AAAS gene in a Moroccan family with Allgrove syndrome: a case report. *BMC Pediatr* 2018;18:184.
- [29] Alakeel A, Raynaud C, Rossi M, et al. Allgrove syndrome. *Ann Dermatol Venereol* 2015;142:121–4.
- [30] Brown B, Agdere L, Muntean C, et al. Alacrima as a harbinger of adrenal insufficiency in a child with Allgrove (AAA) syndrome. *Am J Case Rep* 2016;17:703–6.
- [31] Grant DB, Barnes ND, Dumic M, et al. Neurological and adrenal dysfunction in the adrenal insufficiency/alacrima/achalasia (3A) syndrome. *Arch Dis Child* 1993;68:779–82.