



UNIVERSITÀ DI PARMA

ARCHIVIO DELLA RICERCA

University of Parma Research Repository

Successful management of a triplet heterotopic caesarean scar pregnancy after in vitro fertilization-embryo transfer.

This is the peer reviewed version of the following article:

Original

Successful management of a triplet heterotopic caesarean scar pregnancy after in vitro fertilization-embryo transfer / Litwicka, K; Greco, E; Prefumo, F; Fratelli, N; Scarselli, F; Ferrero, S; Iammarrone, E; Frusca, Tiziana. - In: FERTILITY AND STERILITY. - ISSN 0015-0282. - 95:1(2011), pp. 291-293. [10.1016/j.fertnstert.2010.05.025]

Availability:

This version is available at: 11381/2681608 since: 2016-10-20T16:46:11Z

Publisher:

Published

DOI:10.1016/j.fertnstert.2010.05.025

Terms of use:

Anyone can freely access the full text of works made available as "Open Access". Works made available

Publisher copyright

note finali coverpage

(Article begins on next page)

Successful management of a triplet heterotopic caesarean scar pregnancy after in vitro fertilization-embryo transfer

Katarzyna Litwicka, M.D.,^a Ermanno Greco, M.D.,^a Federico Prefumo, M.D., Ph.D.,^b Nicola Fratelli, M.D.,^b Filomena Scarselli, B.Sc.,^a Susanna Ferrero, M.D.,^a Elisabetta Iammarrone, M.D.,^a and Tiziana Frusca, M.D.^b

^a Assisted Reproduction Centre, European Hospital, Rome; and ^b Maternal Fetal Medicine Unit, University of Brescia, Brescia, Italy

Objective: To report a case of a triplet heterotopic caesarean scar pregnancy (CSP) with two gestational sacs implanted in the caesarean scar after in vitro fertilization-embryo transfer.

Design: Case report.

Settings: Private reproductive medicine center and obstetric department of a university hospital.

Patient(s): A 31-year-old woman with previous caesarean section affected by secondary infertility related to male azoospermia.

Intervention(s): In vitro fertilization-embryotransfer followed by early ultrasound diagnosis of heterotopic CSP and selective embryo reduction performed by transvaginal ultrasound-guided potassium chloride and methotrexate injection in the ectopic gestational sacs.

Main outcome measure(s): Successful pregnancy outcome.

Result(s): An ongoing intrauterine pregnancy with a live birth after successful management of ectopic gestational sacs.

Conclusion(s): Triplet heterotopic CSP with two ectopic gestational sacs may occur after IVF-ET and, to our knowledge, this is the first time such a complication has been reported. Ultrasound is the main tool allowing early diagnosis of this condition, and the injection of potassium chloride and methotrexate is a safe and efficacious treatment method. The gynecologist managing early pregnancy should be aware of the possibility of CSP, and patients must be appropriately counseled about the different treatment options. (*Fertil Steril*® 2011;95:291.e1–e3. ©2011 by American Society for Reproductive Medicine.)

Key Words: Caesarean scar pregnancy, heterotopic pregnancy, embryo reduction, potassium chloride, methotrexate

Caesarean scar pregnancy (CSP) is considered a type of ectopic pregnancy and constitutes a life-threatening condition due to the high risk of uterine rupture with related maternal and fetal morbidity and mortality (1, 2). The etiology of this condition and the best management are still unclear (1, 2). However, some medical and surgical treatment modalities have recently been suggested (1–6).

The frequency of spontaneous heterotopic pregnancies is reported as 1:10,000 to 1:50,000, but evidence suggests that assisted reproductive technologies may increase this risk up to 1% (7–9). CSP coexisting with intrauterine gestation is extremely rare (3–6). Its simultaneous occurrence with a viable intrauterine gestation, which should be preserved, limits availability of several CSP treatment modalities and makes clinical management more difficult (3–6).

Received March 4, 2010; revised April 26, 2010; accepted May 6, 2010; published online June 20, 2010.

K.L. has nothing to disclose. E.G. has nothing to disclose. F.P. has nothing to disclose. N.F. has nothing to disclose. F.S. has nothing to disclose. S.F. has nothing to disclose. E.I. has nothing to disclose. T.F. has nothing to disclose.

Reprint requests: Katarzyna Litwicka, M.D., Assisted Reproduction Centre, European Hospital, Via Portuense 700, 00149 Rome, Italy (TEL: 00-36-6-65975643; FAX: 00-39-6-6534897; E-mail: Litwicka@yahoo.it).

We report the first case of triplet heterotopic CSP in which two ectopic gestational sacs were implanted into the previous caesarean scar. In this case, a local injection of potassium chloride (KCI) and methotrexate (MTX) was successfully performed preserving the intrauterine pregnancy. We also discuss the management options and review the literature.

CASE REPORT

A 31-year-old woman, gravida 1, para 0, presented to our clinic with a 4-year history of secondary infertility. Nine years earlier, she had a spontaneous pregnancy with her previous partner and underwent a lower segment transverse caesarean section because of fetal breech presentation without any postoperative complication.

Routine investigation of couples showed the presence of severe male infertility factor with azoospermia. A preprocedure hysteroscopy failed to identify any abnormality of uterine cavity or wall defect, and a successful testicular sperm extraction was performed with testicular spermatozoa recovery and cryopreservation for further intracytoplasmic sperm injection treatment.

The woman underwent controlled ovarian hyperstimulation using a GnRH antagonist regimen, starting recombinant FSH on day 2 of

the cycle. A total of seven oocytes were obtained, but according to the Italian legislation in force at that time only the best three were used for intracytoplasmic sperm injection. Three embryos with good morphology were transferred into the uterus under abdominal ultrasound guidance. The result of the first pregnancy test was positive (β -hCG 1378 mUI/mL) 14 days after ET, and all further assessments showed a regular β -hCG increment.

The routine vaginal ultrasound examination performed at 5 weeks' gestation showed only one intrauterine sac. One week later, we observed the presence of another two gestation sacs implanted in the anterior isthmic wall close to the caesarean section scar and separated from the bladder wall by a thin myometrial layer. The ultrasound control repeated at 7 weeks identified normal yolk sac, crown-rump length, cardiac activity, and peritrophoblastic vascularization in all gestational sacs (Fig. 1). The physical examination revealed a normal uterine cervix and abdomen. No pelvic pain and vaginal bleeding were reported.

The extensive counseling about the condition, its risks, and treatment options resulted in a conservative management chosen by the patients' because of the desire to preserve the intrauterine pregnancy and further fertility. After informed consent was obtained, a selective embryo reduction of the caesarean scar pregnancies was performed at 8 weeks' gestation at the Maternal Fetal Medicine Unit, University of Brescia. The treatment procedure did not require approval of the institutional review board, and there were no vested interests of a commercial nature or conflicts of interest.

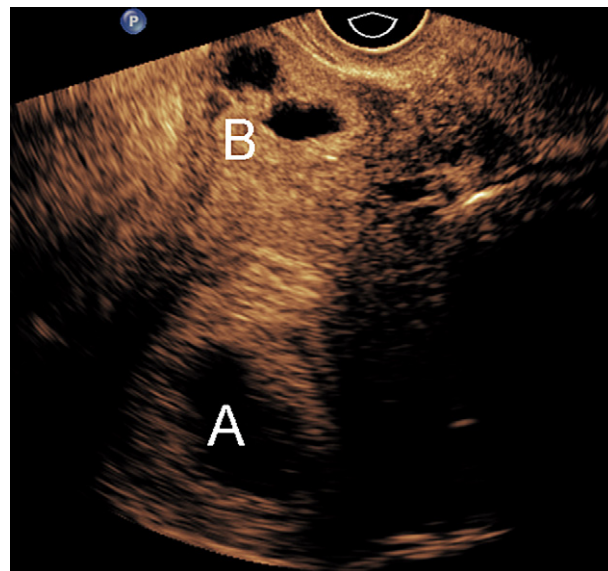
The procedure was performed transvaginally under ultrasound control using a 20-gauge needle. Similar to what was described by Baker et al. (10), 2 ml of 2 mEq KCl were mixed with 15 mg of MTX to a total volume of 4 ml. The mixture was injected into each ectopic gestational sac at 0.5-mL steps. Cardiac activity stopped in both sacs after the injection of 1 mL, at which time no further injection was performed and as much fluid as possible was aspirated from the gestational sac until its collapse. The patient tolerated the procedure well and there were no immediate complication. The ultrasound examination performed the following day confirmed the absence of heart activity in the ectopic sacs. However, the Doppler evaluation revealed a persistence of vascularization around one of two treated sacs. The patient was discharged in good condition 5 days after the procedure. She experienced moderate pelvic pain and a small amount of vaginal bleeding for 1 week.

All ultrasound examinations performed during the pregnancy revealed an amorphous mass of 5×3 cm at the isthmus of the anterior wall of the uterus. The intrauterine pregnancy was uneventful except for a small vaginal bleeding and uterine contractions at 28 and 34 weeks' gestation. Unexpected massive hemorrhage and complete placenta detachment occurred at 36 weeks, leading to the emergency caesarean section with the delivery of male baby weighing 1900 g. The baby showed only four fingers in both feet and small, protruding cup-shaped ears. One month later Miller syndrome was diagnosed, which is considered a rare genetic condition inherited as an autosomal recessive trait (11).

Surgical exploration of the uterine scar evidenced no sign of rupture. The mass measuring 5×3 cm suggestive of remaining trophoblastic tissue of the scar pregnancies was still found at the lower segment of the uterus. This mass was removed for the pathological examination, which found placental and deciduous tissues. Because of the massive blood loss before and during the caesarean section (Hb, 6.1 g/dL) two units of packed red blood cells were immediately transfused. The patient had an uneventful recovery and was discharged in good condition on day 5.

FIGURE 1

Transvaginal sagittal section showing the (A) retroverted uterus with one intrauterine gestational sac and (B) the two sacs implanted on the caesarean scar.



Litwicka. Heterotopic caesarean scar pregnancy management. *Fertil Steril* 2011.

DISCUSSION

Between 1978 and 2001, only 18 cases of CSP were reported in the literature in English. This number increased to 66 during the next 3 years, suggesting that a growing number of caesarean deliveries, together with higher incidence of specific indications, might have an effect on the major scar implantation (1, 2).

Because of the rarity of this condition, no universal treatment guidelines have been established to date (1, 2). The first case of CSP reported by Larsen and Solomon (12) was treated by gestational tissue evacuation during laparotomy. The surgical approach includes hysteroscopy combined with laparoscopy or laparoscopy alone (1, 2, 6). Furthermore, medical treatments based on systemic or local injection of MTX, KCl, and hyperosmolar glucose have been proposed (1–3, 5).

The literature reports only a few cases of heterotopic CSP. Its occurrence in conjunction with a viable intrauterine pregnancy and patient's desire to maintain the intrauterine pregnancy makes the therapeutic management more difficult. Salomon et al. (3) described a twin heterotopic CSP successfully treated with KCl injection into the cardiac area of the ectopically implanted embryo at 8 weeks' gestation. The development of normally implanted pregnancy was uneventful and a healthy girl, weighing 2800 g, was delivered by caesarean section at 36 weeks' gestation because of premature rupture of membranes. Hsieh et al. (4) reported a case of triplet heterotopic CSP with one embryo implanted in the caesarean scar, in which the contents of ectopic sac was aspirated transvaginally with a 16-gauge needle at 6 weeks' gestation. The remaining two intrauterine pregnancies proceeded without complication until 32 weeks' gestation, when an emergency delivery was performed because of preterm labor. Wang et al. (5) published a case report of twin heterotopic CSP in which the reduction of the embryo implanted in the caesarean scar was obtained by KCl

injection at 10 weeks' gestation. The prenatal course was uneventful, and at 35 weeks' gestation a male baby, weighing 1820 g, was delivered by cesarean section because of preterm labor. Recently, Demirel et al. (6) described a spontaneous twin heterotopic CSP successfully managed by a laparoscopic approach under ultrasound guidance. Ongoing intrauterine pregnancy ended with a cesarean delivery at 38 weeks' gestation. Laparoscopic excision of the CSP gave the opportunity to preserve the viable intrauterine gestation while constituting a strong lower uterine segment and avoiding side effects of medical approaches.

To our knowledge, we reported the first case of triplet heterotopic CSP with two gestational sacs implanted in the cesarean scar. It was a particularly challenging case because of the patient's desire to maintain the intrauterine pregnancy and further fertility. We avoided surgical management because we believed that the double-scar implantation, with a major ectopic mass to be removed, would increase the procedure-related complications and expose the intrauterine pregnancy to serious risks. In addition, the early gestational age at the time of diagnosis and a lack of symptoms reported by the patient gave the possibility of conservative management.

Wang et al. (5) used KCl injection, and the serial follow-up evidenced the persistence of gestational tissue over the scar, which was associated with massive blood loss at cesarean section. Gyamfi et al. (13) also described massive bleeding from the retained trophoblastic tissue, which occurred during cesarean section, after fetal reduction of a cervical heterotopic pregnancy by KCl injection. In addition, a doubt about potential toxic effects of KCl is still present (14, 15). To reduce the risks of persistent trophoblastic tissue, the local injection of MTX, alone or in combination with KCl or vasopressin, has been described in cases of heterotopic cervical (16–18) and interstitial pregnancy (10). We considered MTX as highly effective to halt trophoblast proliferation and reduce the risk of CSP to minimal. However, there is evidence of MTX-related teratogenicity observed in a surviving intrauterine fetus after failed medical abortion or ectopic pregnancy treatment (19, 20), and

concerns have been raised about its use by local injection in the treatment of heterotopic pregnancies (21). Therefore, to reduce its negative impact on normally implanted embryo, we decided to add KCl, to reduce the dose of MTX, and to aspirate back the mixture at the end of the procedure. In fact, the isolated malformations observed in the baby are typical of Miller syndrome and different from complex embryopathy deriving from MTX use.

Many theories have been proposed to explain the occurrence of CSP. The most popular is embryo implantation into the uterine wall through a small internal dehiscence of the scar or through a tract from the endometrial canal up to the scar tissue (1, 2). The predisposing factors for pregnancy in this site are multiple cesarean sections increasing scar surface and breech presentation when incision is performed electively on a nondeveloped lower uterine segment (1). A question may be raised whether the CSP could be avoided by improving methods of ET. We routinely perform all ETs under ultrasound control, and hysteroscopy for uterine cavity assessment is a part of our standard preprocedural evaluation, but the heterotopic pregnancy occurred anyway. In addition, a strategy of limiting the number of embryos up to two in young women with previous cesarean section should be considered to minimize the risk of twin heterotopic CSP and simplify clinical management.

The cesarean section rate and reproductive technology has been increasingly enhancing the possibility of CSP increment in the future. Therefore, the gynecologist must be prepared to address a difficult choice of the best available treatment option for this condition. In addition, the intensive management of pregnancy and preparation before delivery must be considered to avoid possible complications and massive blood loss. More attention should be given upon reducing the known etiologic factors, which may contribute to the rapidly growing number of pregnancies implanted in a scarred uterus.

KCl and MTX injection may represent a valid therapeutic option for heterotopic CSP, but further study is needed to compare different treatment methods in terms of efficacy, safety, and reproductive outcome.

REFERENCES

- Maymon R, Halperin R, Mendlovic S, Sneider D, Herman A. Ectopic pregnancies in a Caesarean scar: review of the medical approach to an iatrogenic complication. *Hum Reprod Update* 2004;10:515–23.
- Ash A, Smith A, Maxwell D. Caesarean scar pregnancy. *BJOG* 2007;114:253–63.
- Salomon L, Fernandez H, Chauveaud A, Doumerc S, Frydman R. Successful management of a heterotopic Caesarean scar pregnancy: potassium chloride injection with preservation of the intrauterine gestation: Case report. *Hum Reprod* 2003;18:189–91.
- Hsieh BC, Hwang JL, Pan HS, Huang SC, Chen CY, Chen PH. Heterotopic Caesarean scar pregnancy combined with intrauterine pregnancy successfully treated with embryo aspiration for selective embryo reduction: Case report. *Hum Reprod* 2004;19:285–7.
- Wang CN, Chen CK, Wang HS, Chiueh HY, Soong YK. Successful management of heterotopic scar pregnancy combined with intrauterine pregnancy after in vitro fertilization-embryo transfer. *Fertil Steril* 2007;88:706.e13–6.
- Demirel L, Bodur H, Selam B, Lember A, Ergin T. Laparoscopic management of heterotopic caesarean scar pregnancy with preservation of intrauterine gestation and delivery at term: case report. *Fertile Steril* 2009;9:1293.e5–7.
- Barenetxea G, Rementeria LB, Larruzea AL, Agirreigoikoa JA, Mandiola M, Carbonero K. Heterotopic pregnancy: two cases and comparative review. *Fertil Steril* 2007;87:417.e9–15.
- Goldenberg JM, Bedaiwy MA. Transvaginal local injection of hyperosmolar glucose for the treatment of heterotopic pregnancy. *Obstet Gynecol* 2006;107:509–10.
- Molloy D, Deambrosio W, Keeping D, Hynes J, Harrison K, Hennessey J. Multiple-sited (heterotopic) pregnancy after in vitro fertilization and gamete intrafallopian transfer. *Fertil Steril* 1990;53:1068–71.
- Baker VL, Givens CR, Cadieux MC. Transvaginal reduction of an interstitial heterotopic pregnancy with preservation of the intrauterine gestation. *Am J Obstet Gynecol* 1997;176:1384–5.
- Stuart-Ogilvy AL, Parsons AC. Miller syndrome (postaxial acrofacial dysostosis): further evidence for autosomal recessive inheritance and expansion of the phenotype. *J Med Genet* 1991;28:695–700.
- Larsen JV, Solomon MH. Pregnancy in a uterine scar sacculus: An unusual cause of postabortal hemorrhage. *S Afr Med J* 1978;53:142–3.
- Gyamfi C, Cohen S, Stone J. Maternal complication of cervical heterotopic pregnancy after successful potassium chloride fetal reduction. *Fertil Steril* 2004;82:940–3.
- Tabsh KMA. Transabdominal multifetal pregnancy reduction: report of 40 cases. *Obstet Gynecol* 1990;75:739–41.
- Wapner RJ, Davis GH, Johnson A, Weinblatt VJ, Fischer RJ, Jackson LG, et al. Selective reduction in multifetal pregnancies. *Lancet* 1990;335:90–3.
- Peleg D, Bar-Hava I, Neuman-Levin M, Ashkenazi J, Ben-Rafael Z. Early diagnosis and successful nonsurgical treatment of viable combined intrauterine and cervical pregnancy. *Fertil Steril* 1994;62:405–8.
- Al-Azemi M, Ledger WL, Lockwood GM, Barlow DH. Successful transvaginal ultrasound-guided ablation of a cervical pregnancy in a patient with simultaneous intrauterine pregnancy after in vitro fertilization and embryo transfer. *Hum Fertil (Camb)* 1999;2:67–9.
- Honda R, Matsuura K, Okamura H. Heterotopic cervical pregnancy with preservation of the intrauterine gestation. *Reprod Med Biol* 2005;4:221–3.
- Adam MP, Manning MA, Beck AE, Kwan A, Enns GM, Clericuzio C, et al. Methotrexate/misoprostol embryopathy: report of four cases resulting from failed medical abortion. *Am J Med Genet A* 2003;123A:72–8.
- Goffman D, Cole DS, Bobby P, Garry DJ. Failed methotrexate termination of pregnancy: a case report. *J Perinatol* 2006;26:45–7.
- Timor-Tritsch IE. Is it safe to use methotrexate for selective injection in heterotopic pregnancy? *Am J Obstet Gynecol* 1998;178:193–4.