



# UNIVERSITÀ DI PARMA

## ARCHIVIO DELLA RICERCA

University of Parma Research Repository

Concordant body stalk anomaly in a monoamniotic twin pregnancy at 9 weeks

This is the peer reviewed version of the following article:

*Original*

Concordant body stalk anomaly in a monoamniotic twin pregnancy at 9 weeks / Roviola, Paola Linda; Prefumo, Federico; Frusca, Tiziana; Fichera, Anna. - In: PRENATAL DIAGNOSIS. - ISSN 0197-3851. - 34:(2014), pp. 915-916. [10.1002/pd.4392]

*Availability:*

This version is available at: 11381/2774133 since: 2015-02-03T09:00:06Z

*Publisher:*

*Published*

DOI:10.1002/pd.4392

*Terms of use:*

Anyone can freely access the full text of works made available as "Open Access". Works made available

*Publisher copyright*

note finali coverpage

(Article begins on next page)

17 April 2024

## RESEARCH LETTER

# Concordant body stalk anomaly in a monoamniotic twin pregnancy at 9 weeks

Paola Linda Rovida<sup>1</sup>, Federico Prefumo<sup>1\*</sup>, Tiziana Frusca<sup>1,2</sup> and Anna Fichera<sup>1</sup>

<sup>1</sup>Maternal-Fetal Medicine Unit, Department of Obstetrics and Gynecology, University of Brescia, Italy

<sup>2</sup>Department of Obstetrics and Gynecology, University of Parma, Italy

\*Correspondence to: Federico Prefumo. E-mail: federico.prefumo@gmail.com

Funding sources: None

Conflicts of interest: None declared

Body stalk anomaly is a rare abnormality with a reported incidence between 1 per 14,000 to 1 per 31,000 pregnancies.<sup>1</sup> Because of the high rate of subsequent intrauterine death and pregnancy termination, the incidence at birth is much lower, about 0.32 per 100,000 births.<sup>1</sup> Body stalk anomaly is characterized by herniation of the abdominal contents into the extraembryonic coelom through a large wall defect and by a very short or absent umbilical cord.<sup>2</sup> Cranial defects, kyphoscoliosis, and limb defects can be also observed. The prognosis is almost universally lethal, given the complex abnormalities and the association with pulmonary hypoplasia, although occasional cases of long-term survival have been reported.<sup>3</sup> When limb abnormalities and complex craniofacial abnormalities are also present, the term limb-body wall complex or defect is often employed.<sup>2</sup> Body stalk anomaly can occur both in dizygotic and monozygotic twins, and the latter can be concordant or discordant for this abnormality.<sup>4</sup> Although there are a number of reports of body stalk anomaly diagnosed in the second or third trimester, cases of early pregnancy diagnosis are relatively few.

A 22-year-old gravida 2 para 1 attended our hospital for a first trimester ultrasound scan at 9<sup>+5</sup> gestational weeks. She had an unremarkable medical history and reported no consanguinity. Sonographic examination performed with Philips iU-22 ultrasound system using a C10-3v multi-frequency curved array transvaginal transducer (Philips, Bothell, WA, USA) revealed a monochorionic monoamniotic twin pregnancy: the gestational sac contained two live embryos with a crown-rump length of 29 mm, and no dividing membrane could be identified; a single yolk sac was identified. Both embryos had a large abdominal wall defect, partial evisceration of abdominal contents and heart, and were connected to the placenta by a short umbilical cord. Lower limbs were not identified in one fetus and grossly abnormal in the other; the latter also had a cystic structure at the caudal pole (Figure 1). The lower part of the body of both embryos was visualized within the extraembryonic coelom,

outside of an apparently intact amniotic membrane. After genetic counseling, estimation of the recurrence risk and explanation of the severe prognosis, the woman requested termination of the pregnancy while refusing fetal karyotyping. A detailed pathological examination of the embryos was not possible as the specimen obtained after surgical termination was severely disrupted.

Data on first trimester diagnosis of body stalk anomaly are limited. In a series of 106,727 nuchal translucency scans performed at 10–14 weeks, 14 fetuses with body stalk anomaly were found.<sup>5</sup> Another study identified four cases of body stalk anomaly from a total of 6952 nuchal translucency scans.<sup>6</sup> A third study diagnosed the anomaly in five of 45,191 fetuses having a scan at 11–14 weeks.<sup>7</sup> All cases were characterized by a large ventral wall defect, with herniation of abdominal contents into the extraembryonic coelom, where they appeared to be directly attached to the placenta. No umbilical cord could be identified. In all cases, the upper part of the fetus remained within the amniotic cavity and no craniofacial defects were seen. Out of 23 fetuses with body stalk anomaly at 10–14 weeks described in these three series, 17 (74%) had a nuchal translucency above the 95th percentile.<sup>5–7</sup> We are aware of only one case report of body stalk anomaly diagnosed before 10 gestational weeks<sup>8</sup>: at 9<sup>+5</sup> weeks the embryo was visualized within the coelomic cavity outside an apparently intact amniotic membrane and had multiple anomalies including a skull and brain defect, abdominal wall defect, kyphoscoliosis, and gross deformities of the lower limbs. Most published cases of twin pregnancies complicated by body stalk anomaly have been reviewed by Vidaeff *et al.*<sup>4</sup> In monochorionic pregnancies, the twins can be either concordant or discordant for the anomaly, regardless of amnionicity, and significant anatomic details visible on ultrasound are only described in the most recent cases. A further case of monoamniotic fetuses discordant for the anomaly and diagnosed at 11 weeks of gestation was

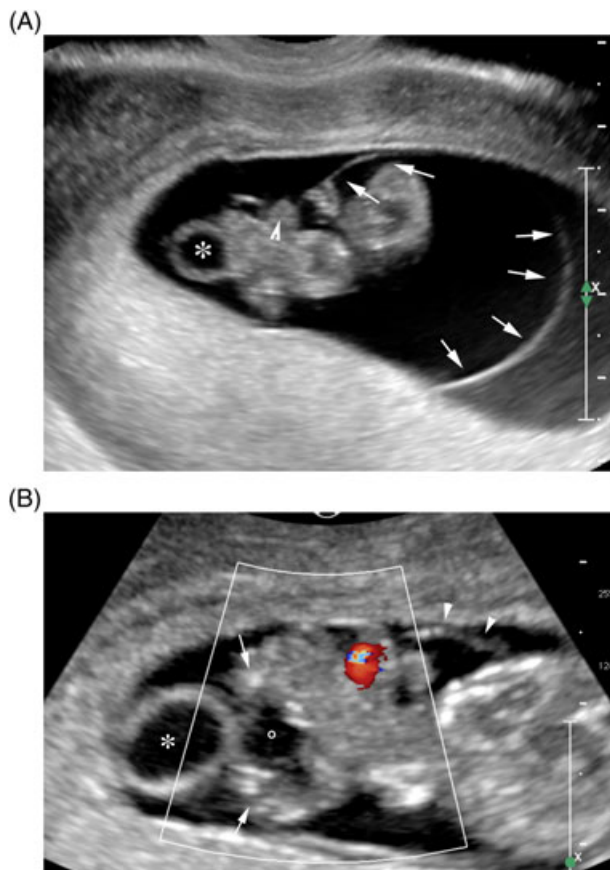


Figure 1 Ultrasound images showing (A) the sagittal view of one embryo showing the amniotic membrane (arrows), the yolk sac (asterisk), and the ectopic heart (arrowhead); and (B) the second embryo with amniotic membrane (arrowhead), the yolk sac (asterisk), the ectopic heart, abnormal lower limbs (arrows), and a cystic structure at the caudal pole (circle)

very recently reported<sup>9</sup>: the affected fetus presented with a large anterior abdominal wall defect, scoliosis, absent lower limbs, short umbilical cord, and increased nuchal translucency.

To the best of our knowledge, the current report is the second ultrasound observation of body stalk anomaly before 10 gestational weeks, and the first in concordant monoamniotic twins at this early gestation. The amniotic cavity was intact with no signs suggestive of rupture, and both embryos had the same anomaly, although with slightly different features. These findings do not support early amniotic membrane rupture or vascular hypoperfusion as the primary event in the pathogenesis of body stalk anomaly and are rather in keeping with the hypothesis of a primary ectodermal failure in the early embryonic disk explaining most features of the body stalk anomaly/limb-body wall complex.<sup>10</sup> The relationship between the embryo/fetus, amniotic membrane, and extraembryonic coelom becomes usually more difficult to assess later in pregnancy, when the umbilical cord becomes very short or absent, and the extraembryonic coelom obliterates.<sup>2</sup>

#### WHAT'S ALREADY KNOWN ABOUT THIS TOPIC?

- Cases of early pregnancy diagnosis of body stalk anomaly are relatively few, particularly in twins.

#### WHAT DOES THIS STUDY ADD?

- This is the first diagnosis of concordant body stalk anomaly in monoamniotic twins before 10 gestational weeks.
- The observation of an intact amniotic cavity with both embryos showing the same anomaly supports a primary ectodermal failure as the cause for body stalk anomaly.

## REFERENCES

1. Forrester MB, Merz RD. Epidemiology of abdominal wall defects, Hawaii, 1986-1997. *Teratology* 1999;60:117-23.
2. Prefumo F, Izzi C. Fetal abdominal wall defects. *Best Pract Res Clin Obstet Gynaecol* 2014;28:391-402.
3. Kanamori Y, Hashizume K, Sugiyama M, *et al.* Long-term survival of a baby with body stalk anomaly: report of a case. *Surg Today* 2007;37:30-3.
4. Vidaeff AC, Delu AN, Silva JB, Yeomans ER. Monoamniotic twin pregnancy discordant for body stalk anomaly: case report with nosologic implications. *J Ultrasound Med* 2005;24:1739-44.
5. Daskalakis G, Sebire NJ, Jurkovic D, *et al.* Body stalk anomaly at 10-14 weeks of gestation. *Ultrasound Obstet Gynecol* 1997;10:416-8.
6. Murphy A, Platt LD. First-trimester diagnosis of body stalk anomaly using 2- and 3-dimensional sonography. *J Ultrasound Med* 2011;30:1739-43.
7. Syngelaki A, Chelemen T, Dagklis T, *et al.* Challenges in the diagnosis of fetal non-chromosomal abnormalities at 11-13 weeks. *Prenat Diagn* 2011;31:90-102.
8. Becker R, Runkel S, Entezami M. Prenatal diagnosis of body stalk anomaly at 9 weeks of gestation. Case report. *Fetal Diagn Ther* 2000;15:301-3.
9. Tavares MV, Domingues AP, Tavares M, *et al.* Monoamniotic twins discordant for body stalk anomaly. *J Matern Fetal Neonatal Med* 2014, DOI: 10.3109/14767058.2014.900035.
10. Hunter AG, Seaver LH, Stevenson RE. Limb-body wall defect. Is there a defensible hypothesis and can it explain all the associated anomalies? *Am J Med Genet A* 2011;155A:2045-59.

## SUPPORTING INFORMATION

Additional supporting information may be found in the online version of this article at the publisher's web site.