



# UNIVERSITÀ DI PARMA

## ARCHIVIO DELLA RICERCA

University of Parma Research Repository

Fetoscopic cord transection for treatment of monoamniotic twin reversed arterial perfusion sequence

This is the peer reviewed version of the following article:

*Original*

Fetoscopic cord transection for treatment of monoamniotic twin reversed arterial perfusion sequence / Prefumo, F.; Fichera, A.; Frusca, Tiziana. - In: ULTRASOUND IN OBSTETRICS & GYNECOLOGY. - ISSN 0960-7692. - 43:2(2014), pp. 234-235. [10.1002/uog.13229]

*Availability:*

This version is available at: 11381/2774129 since: 2016-10-06T16:17:08Z

*Publisher:*

*Published*

DOI:10.1002/uog.13229

*Terms of use:*

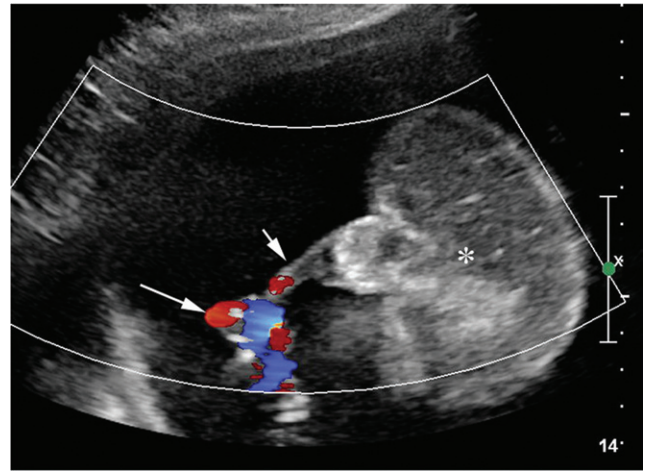
Anyone can freely access the full text of works made available as "Open Access". Works made available

*Publisher copyright*

note finali coverpage

(Article begins on next page)

24 April 2024

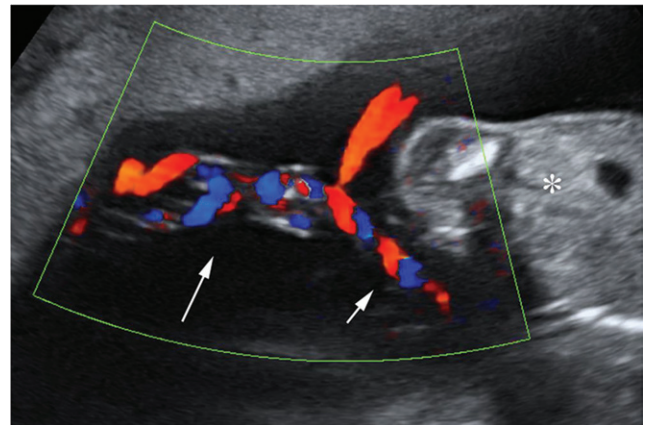


**Figure 1** Ultrasound image of Case 1 at 23 + 2 weeks, showing entanglement of the two cords (long arrow) and a very short length of free parasitic twin umbilical cord at abdominal insertion (short arrow). Asterisk indicates the parasitic twin.

### Fetoscopic cord transection for treatment of monoamniotic twin reversed arterial perfusion sequence

We read with interest two articles discussing the role and timing of intrafetal procedures, particularly interstitial laser therapy, for the treatment of twin reversed arterial perfusion (TRAP) sequence<sup>1,2</sup>. In both case series and in the systematic review by Pagani *et al.*<sup>1</sup>, no case appeared to involve a monoamniotic twin pregnancy. However, approximately 3–4% of cases of TRAP sequence are monoamniotic<sup>3</sup>. Since the umbilical cord of the parasitic twin is often very short, this does not usually affect treatment modality. However, when the cord is long enough to allow cord entanglement with the pump twin, this can pose a major challenge. Although cord entanglement *per se* is not associated with increased risk of complications in monoamniotic pregnancies<sup>4</sup>, occlusion of blood flow to the abnormal twin may be associated with increased risk of intrauterine death of the surviving twin and has been described as a cause of intrauterine demise in TRAP sequence<sup>5</sup>. It is possible that the unperfused cord undergoing involution may easily act as a band constricting the co-twin's cord more than a normally perfused cord with an adequate amount of Wharton's jelly. To avoid such risks, it is feasible to transect the umbilical cord with laser after its occlusion, thus allowing release of the entanglement; this has been reported in only one case of TRAP sequence<sup>5</sup>.

We describe here two further cases of TRAP sequence in monoamniotic twin pregnancies with cord entanglement (Figures 1 and 2), treated by fetoscopic laser cord coagulation and transection. Procedures were performed between March 2012 and March 2013, both with a single-entry technique using a 2-mm fetoscope inserted under ultrasound guidance in the amniotic cavity through a sheath with an outer diameter of 3 mm (Karl Storz, Tuttlingen, Germany). The umbilical cord of the parasitic



**Figure 2** Ultrasound image of Case 2 at 18 + 0 weeks, showing entanglement of the two cords (long arrow) and a segment of disentangled cord of the parasitic twin (short arrow). Asterisk indicates the pump twin.

twin was coagulated near its abdominal insertion over a length of 10–15 mm, using a 600- $\mu$ m diode laser beam (Medilas, Dornier MedTech, Wessling, Germany) with 5-s bursts at 40 W. After demonstrating the absence of blood flow with color Doppler, the cord was transected with laser using a contact technique (Videoclip S1).

In both cases, the parasitic twin was larger than the pump twin, and polyhydramnios and signs of pump twin cardiac overload (increased ductus venosus pulsatility) were seen. In Case 1, the procedure was performed at 23 + 3 weeks and required 15 minutes. A female weighing 2250 g was delivered by Cesarean section at 34 + 4 weeks at the referring hospital because of umbilical Doppler abnormalities. In Case 2, the procedure was performed at 18 + 1 weeks and required 10 minutes. A female weighing 1400 g was spontaneously delivered at 30 + 4 weeks and the postnatal course was uneventful. At the time of writing both children were normal at pediatric follow-up.

Although results of non-randomized studies<sup>1,2</sup> suggest that early intrafetal laser treatment of TRAP sequence is advantageous, our cases emphasize that pregnancies referred late, or with peculiar anatomical variants such as monoamnicity with cord entanglement, would still require a tailored approach which might involve fetoscopic laser cord coagulation and transection.

F. Prefumo\*, A. Fichera, C. Zanardini and T. Frusca  
Maternal-Fetal Medicine Unit,  
Department of Obstetrics and Gynaecology,  
University of Brescia, Brescia, Italy  
\*Correspondence.  
(e-mail: federico.prefumo@gmail.com)

DOI: 10.1002/uog.13229

## References

1. Pagani G, D'Antonio F, Khalil A, Papageorgiou A, Bhide A, Thilaganathan B. Intrafetal laser treatment for twin reversed arterial perfusion sequence: cohort study and meta-analysis. *Ultrasound Obstet Gynecol* 2013; **42**: 6–14.
2. Berg C, Holst D, Mallmann MR, Gottschalk I, Gembruch U, Geipel A. Early vs late intervention in twin reversed arterial perfusion (TRAP) sequence. *Ultrasound Obstet Gynecol* 2014; **43**: 60–64.
3. Cabassa P, Fichera A, Prefumo F, Taddei F, Gandolfi S, Maroldi R, Frusca T. The use of radiofrequency in the treatment of twin reversed arterial perfusion sequence: a case series and review of the literature. *Eur J Obstet Gynecol Reprod Biol* 2013; **166**: 127–132.
4. Rossi AC, Prefumo F. Impact of cord entanglement on perinatal outcome of monoamniotic twins: a systematic review of the literature. *Ultrasound Obstet Gynecol* 2013; **41**: 131–135.
5. Valsky DV, Martinez-Serrano MJ, Sanz M, Eixarch E, Acosta ER, Martinez JM, Puerto B, Gratacos E. Cord occlusion followed by laser cord transection in monochorionic monoamniotic discordant twins. *Ultrasound Obstet Gynecol* 2011; **37**: 684–688.

## SUPPORTING INFORMATION ON THE INTERNET

The following supporting information may be found in the online version of this article:



**Videoclip S1** Full-length video of the fetoscopic procedure in a case of twin reversed arterial perfusion sequence in a monoamniotic twin pregnancy with cord entanglement (Case 2)