



Original Article

# Increased Mucosal Thrombin is Associated with Crohn's Disease and Causes Inflammatory Damage through Protease-activated Receptors Activation

Jean-Paul Motta,<sup>a,b,○</sup> Simone Palese,<sup>a,c</sup> Carmine Giorgio,<sup>a,c</sup>  
Kevin Chapman,<sup>d</sup> Alexandre Denadai-Souza,<sup>a,○</sup> Perrine Rousset,<sup>a</sup>  
David Sagnat,<sup>a</sup> Laura Guiraud,<sup>a</sup> Anissa Edir,<sup>a</sup> Carine Seguy,<sup>a</sup>  
Laurent Alric,<sup>e,f,g</sup> Delphine Bonnet,<sup>e,f</sup> Barbara Bournet,<sup>f,g</sup>  
Louis Buscail,<sup>f,g</sup> Cyrielle Gilletta,<sup>f</sup> Andre G. Buret,<sup>h</sup> John L. Wallace,<sup>d</sup>  
Morley D. Hollenberg,<sup>d</sup> Eric Oswald,<sup>a</sup> Elisabetta Barocelli,<sup>c</sup>  
Sylvie Le Grand,<sup>b</sup> Bruno Le Grand,<sup>b</sup> Celine Deraison,<sup>a\*</sup>  
Nathalie Vergnolle<sup>a,d\*</sup>

<sup>a</sup>IRSD, Université de Toulouse, INSERM, INRA, ENVT, UPS, U1220, CHU Purpan, CS60039, 31024 Toulouse, France  
<sup>b</sup>CVasThera, Arobase Castres-Mazamet, Castres, France <sup>c</sup>Università di Parma, Dipartimento di Scienze degli Alimenti e del Farmaco, Parma, Italia <sup>d</sup>Departments of Physiology & Pharmacology, and Medicine, University of Calgary Cumming School of Medicine, Calgary, AB, Canada <sup>e</sup>Department of Internal Medicine and Digestive Diseases, CHU Toulouse, Toulouse, France <sup>f</sup>Pole Digestif, CHU Toulouse, Toulouse, France <sup>g</sup>Faculty of Medicine, Paul Sabatier University, Toulouse, France <sup>h</sup>Department of Biological Sciences, University of Calgary, Calgary, AB, Canada

Corresponding author: Dr Nathalie Vergnolle, PhD, Institut de Recherche en Santé Digestive [IRSD], INSERM UMR-1220, Purpan Hospital, CS60039, 31024 Toulouse cedex 03, France. Tel.: 33-5-62-74-45-00; fax: 33-5-62-74-45-58; email: [nathalie.vergnolle@inserm.fr](mailto:nathalie.vergnolle@inserm.fr)

\*Co-last authors

## Abstract

**Background and Aims:** Thrombin levels in the colon of Crohn's disease patients have recently been found to be elevated 100-fold compared with healthy controls. Our aim was to determine whether and how dysregulated thrombin activity could contribute to local tissue malfunctions associated with Crohn's disease.

**Methods:** Thrombin activity was studied in tissues from Crohn's disease patients and healthy controls. Intracolonic administration of thrombin to wild-type or protease-activated receptor-deficient mice was used to assess the effects and mechanisms of local thrombin upregulation. Colitis was induced in rats and mice by the intracolonic administration of trinitrobenzene sulphonic acid.

**Results:** Active forms of thrombin were increased in Crohn's disease patient tissues. Elevated thrombin expression and activity were associated with intestinal epithelial cells. Increased thrombin activity and expression were also a feature of experimental colitis in rats. Colonic exposure to doses of active thrombin comparable to what is found in inflammatory bowel disease tissues caused mucosal damage and tissue dysfunctions in mice, through a mechanism involving both protease-activated receptors -1 and -4. Intracolonic administration of the thrombin inhibitor

dabigatran, as well as inhibition of protease-activated receptor-1, prevented trinitrobenzene sulphonic acid-induced colitis in rodent models.

**Conclusions:** Our data demonstrated that increased local thrombin activity, as it occurs in the colon of patients with inflammatory bowel disease, causes mucosal damage and inflammation. Colonic thrombin and protease-activated receptor-1 appear as possible mechanisms involved in mucosal damage and loss of function and therefore represent potential therapeutic targets for treating inflammatory bowel disease.

**Key Words:** Thrombin; protease-activated receptors; colitis; epithelium; inflammation; barrier

## 1. Introduction

The pathogenesis of inflammatory bowel diseases [IBD], which include Crohn's disease [CD] and ulcerative colitis [UC], results from the complex interplay between genetic susceptibility, environmental input and immunological disorders.<sup>1</sup> To date, many therapeutic approaches for IBD have targeted the infiltration of inflammatory cells into the colonic tissue. However, it has been well established that leaky barrier and tissue dysfunctions also play roles in the pathology of IBD, complementing the immune system overactivation.<sup>2</sup> Among the mucosal factors that could contribute to tissue malfunctions, serine proteases are of particular interest.<sup>3</sup> Indeed, increased serine protease activity has been associated with both CD and UC, when measured in tissue biopsies<sup>4-7</sup> or in faeces of IBD patients,<sup>8</sup> compared with healthy controls. In a recent study, we have used activity-based probes in order to identify the proteases that were the most actively released by IBD patient tissues. This study found that thrombin levels were elevated 100-fold in biopsy supernatants of CD patients compared with healthy controls.<sup>5</sup> This increased thrombin activity in the colon of CD patients can originate either from the general circulation, or from the intestinal epithelium, which we have identified as a source of active thrombin.<sup>9</sup>

Several clinical studies suggest that thrombin could be a target for the treatment of IBD.<sup>10</sup> Indeed, increased systemic thrombin generation was observed in IBD patient's blood, particularly in patients with high C-reactive protein levels.<sup>11</sup> Coagulation cascade or platelet activation markers [including beta-thromboglobulin, D-dimer, or thrombin activatable fibrinolysis inhibitor] are associated with increased disease activity in CD patients.<sup>12-14</sup> Acquired hypercoagulation, along with microthrombi formation in bowel capillaries of IBD patients, have been reported.<sup>15,16</sup> Further, despite the recognised complication of increased intestinal bleeding, treatments of IBD patients with the anticoagulant, heparin [an indirect thrombin inhibitor], have demonstrated some clinical and endoscopic benefits.<sup>17-19</sup> This result was rather counter-intuitive, considering the pro-coagulant role of thrombin and the fact that IBD patients experience mucosal bleeding. However, the beneficial effects of thrombin inhibition in IBD patients were clearly reported, suggesting that thrombin itself might play a pro-inflammatory role in IBD, independent of its effect on coagulation. However, neither a pro-inflammatory role for thrombin in IBD nor its potential mechanism of action have yet been demonstrated.

Thus, our general objective was to determine the potential role of mucosal thrombin in intestinal inflammation and its mechanisms of action. First we evaluated whether there is an increased presence of active thrombin in CD, both in patient tissues and in an animal model of IBD. Second, recognising the advantages and disadvantages of rodent models of colitis, we investigated the effects on mucosal

damage and tissue dysfunction resulting from the intracolonic administration of thrombin in wild type [WT] and protease-activated receptor [PAR]1 or PAR4-null mice at doses comparable to levels detected in the tissue of CD patients. Finally, we evaluated the effects of thrombin or PAR inhibition in recognised rodent models of IBD.

## 2. Materials and Methods

### 2.1. Studies in patients: Crohn's disease and controls

#### 2.1.1. Tissue collection and patients

Human colonic tissue collection received ethical approval from the French Ethic Committee [Identifier: NCT01990716]. Patients received written and verbal information about the study and signed informed consent before the enrolment in the study. Colonic tissue samples were obtained from diagnosed CD patients undergoing colonoscopy at the Toulouse Hospital, Gastroenterology Pole. All CD patients had active disease and all samples were collected in inflammatory zones, only from colons, at no specific location within the colon. Healthy control samples were from individuals undergoing colon cancer screening who were negative for cancer diagnosis and otherwise healthy. In those patients, biopsies were randomly collected from different colon areas. Details on patient disease and demographics are provided in [Supplementary Table 1, available as Supplementary data at ECCO-JCC online](#).

Upon collection, fresh colonic biopsies were either immediately embedded at optimal cutting temperature [OCT], snap-frozen in dry ice, and stored at -80 °C for further *in situ* zymography or immunohistochemistry analysis, or stored at -80 °C in 400 µL of RP1 buffer [Macherey-Nagel].

#### 2.1.2. Western blot

Tissue protein extraction from colonic biopsies was performed by using the RNA/Protein Nucleospin Kit, according to manufacturer's instructions [Macherey-Nagel]. Upon protein quantification using the Pierce Protein BCA Assay Kit, according to/adapted to manufacturer's instructions [Thermo Scientific/Macherey-Nagel], protein content was adjusted to 5 µg/µL in protein-solving buffer [PSB] supplemented with the reducing agent tris[2-carboxyethyl] phosphine [PSB-TCEP, Macherey-Nagel]. Samples were heated at 95°C for 5 min, before being used for further western blot analysis. A total of 50 µg [10 µL] of protein per sample was loaded per lane, run into 4–20% Mini-Protean TGX precast gels [BioRad, 456–1085], and transferred onto nitrocellulose membrane using the Trans-Blot Turbo System [BioRad]. The membrane was blocked for 1 h in phosphate buffer saline [PBS] supplemented with 1% bovine serum albumin and 0.05% Tween-20, and then incubated overnight

in the same buffer complemented with the goat IgG anti-thrombin [1:200; K-20; sc-16972, Santa Cruz Biotech]. Membrane was then washed and incubated for 1 h with secondary antibody donkey anti-goat IgG conjugated to horse radish peroxidase [HRP] [1:50,000; Jackson Immunoresearch]. Immunoblots were resolved using the kit ECL Prime, according to instructions [GE Healthcare]. Membranes were visualised using a Chemidoc XRS [Bio-Rad]. Hence, membranes were striped and subjected to the same steps to immunodetect  $\beta$ -actin [1:10,000, A544041, Sigma], followed by incubation with anti-mouse IgG conjugated to HRP [V805A, Promega]. The molecular weight of bands of interest and the relative abundance to  $\beta$ -actin were estimated with the software ImageLab [version 5.0; build 18, Bio-Rad]. Data are expressed as fold change relative to the control group.

### 2.1.3. Immunostaining

As described above, human colonic biopsies were cryopreserved in OCT compound and sectioned at 6- $\mu$ m thickness. Slices were thawed at room temperature for 20 min and incubated with blocking solution [1% bovine serum albumin, 0.3% Triton X-100, PBS 1X] for 1 h. They were then incubated in the same solution complemented with the anti-thrombin described for western blot analysis [1/250 dilution] overnight. The secondary antibody used for detection was an anti-goat Alexa-555 from Life Technologies [A211432], used at 1/1000 dilution as previously described.<sup>9</sup> Counterstaining of nuclei was performed using 4',6-diamidino-2-phenylindole [DAPI] from Invitrogen France. EpCAM [epithelial cell adhesion molecule] staining was used as an epithelial marker [anti-EpCAM, ab71916, Abcam]. Representative images were obtained from random acquisition of four different fields, and images were acquired using a Leica LSM710 confocal microscope. Fiji freeware was used for final image mounting [v 1.51].

### 2.1.4. *In situ* zymography in human samples

Thrombin activity was detected in tissues by *in situ* zymography. Cryosections of colonic human tissue were rinsed with 2% Tween in PBS, and 50  $\mu$ l per slice of 400  $\mu$ M BOC-Val-Pro-Arg-amino-4-methylcoumarin hydro-chloride were applied for 4 h at 37°C. To confirm specific thrombin activity on tissues, frozen sections were pre-incubated with 10  $\mu$ M dabigatran for 30 min and incubated with substrate buffer plus 10  $\mu$ M dabigatran. Nuclei were counterstained using 4',6-diamidino-2-phenylindole. Sections were visualised with an LSM 710 confocal microscope. Representative images were obtained from random acquisition of a minimum of four different fields. Imaging analysis was performed with Zen 2009 software [Carl Zeiss].

## 2.2. Studies in animal models

### 2.2.1. Animals

Wistar rats [150–200 g] and C57BL/6 and BalbC mice [8 weeks old] were purchased from Janvier laboratories, Saint-Quentin Fallavier [France]. PAR1-deficient mice [PAR1<sup>-/-</sup>] and littermates [C57BL/6 background] were originally provided by Johnson & Johnson Pharmaceutical Research and Development. PAR4-deficient mice [PAR4<sup>-/-</sup>] and littermates [C57BL/6 background] were originally provided by Shaun Coughlin, University of San Francisco, California. PAR1<sup>-/-</sup>, PAR4<sup>-/-</sup> and littermates were all bred at the University of Calgary, and were housed in a temperature-controlled room and had free access to food and water. The Animal Care Committee of the University of Calgary approved all experimental protocols

for experiments using PAR-deficient mice. All the other animal experimentations were performed in Toulouse, under the approval of the Animal Care and Ethics Committee of US006/CREFRE [CEEA-122, APAFIS#7762-20161125092278235]. For all animal experiments, distal colon was considered for tissue collection and analysis. The schematic study outline for *in vivo* studies is resumed in [Supplementary Figure 1](#), available as [Supplementary data at ECCO-JCC online](#).

### 2.2.2. Intracolonic administration of thrombin

Thrombin [specific activity 2000 NIH units/mg protein, T6884, Sigma] was administered daily for 10 days intracolonicly [5 U/mouse in 50  $\mu$ l saline, 0.9% NaCl] under light anaesthesia [3% isoflurane] in PAR1<sup>-/-</sup>, PAR4<sup>-/-</sup>, and their WT littermates and in mice purchased from Janvier laboratories. Controls received heat-inactivated thrombin [same dose, 10 min at 100°C] or saline alone. After intracolonic instillation, mice were kept upside down for 2 min to allow colonic diffusion of the administered solution. After 10 days, mice were sacrificed by cervical dislocation and inflammation parameters were measured.

### 2.2.3. Colitis models and inflammation parameters

Trinitrobenzene sulphonic acid [TNBS] colitis was induced in fasted male rats [280–300 g, 9–10 weeks old] as previously described.<sup>20,21</sup> Animals were housed in ventilated cages and acclimatised for 1 week before experimentation started, and beddings were mixed twice. Briefly, TNBS was prepared at a final concentration of 120 mg/ml in 50% ethanol in saline and was kept in the dark before use. A catheter was inserted at 8 cm from the anus, and 30 mg of the TNBS solution was instilled through the catheter into the lumen in a final volume of 250  $\mu$ l/rat. For TNBS colitis induction in mice [20–25g, 8 weeks old], animals were fasted and were lightly anaesthetised with halothane. A polyethylene catheter was inserted intracolonicly 4 cm from the anus, and TNBS [40 mg/ml] dissolved in a solution of saline plus 40% ethanol was pushed into the catheter. At time of the sacrifice, colonic tissues were harvested.

Before opening the colon, luminal washes with PBS solution [1 ml] were performed in order to measure thrombin activity in those washes. Colons were then cut opened. Macroscopic damage scores were evaluated as previously described,<sup>9</sup> by a skilled observer unaware of the treatments. When observed, the following parameters were given score of 1: haemorrhage, oedema, stricture, ulceration, faecal blood, mucus, and diarrhoea. Erythema was scored a maximum of 2 depending on the length of the area being affected [0, absent; 1, less than 1 cm; and 2, more than 1 cm]. Adhesion was scored based on its severity [0, absent; 1, moderate; and 2, severe]. Colon thickness was measured using an electronic caliper [Mitutoyo, Mississauga, Canada, resolution 0.01 mm]. Myeloperoxidase [MPO] activity was measured as an index of granulocyte infiltration, as previously described. Tissue samples were homogenised in a solution of 0.5% hexadecyltrimethylammonium bromide dissolved in phosphate buffer solution [pH 6.0] for 1 min. Homogenised tissues were centrifuged at 13 000 g for 2 min. Supernatants were added to a buffer supplemented with 1% hydrogen peroxide and O-dianisidine dihydrochloride solution. Optical density readings were taken for 1 min at 30-s intervals at 450 nm.<sup>22</sup> Results were normalised to total protein content and expressed as OD<sub>450 nm</sub>/min/ $\mu$ g/ml.

For bacterial translocation assays, mesenteric lymph nodes were collected aseptically, weighed, and homogenised before being plated at 37°C in Columbia blood agar [BD Biosciences] for 24 h for aerobes,

and for 48 h for anaerobes left in anaerobic jars.<sup>9</sup> For permeability assays, mice received orally 4-kDa FITC Dextran [Sigma Aldrich] at the dose of 600 mg/kg body weight in PBS, and blood was collected 1-h afterwards. Fluorescence for FITC-dextran presence in serum was measured by spectrophotometry [excitation 485 nm, emission 528 nm].<sup>23</sup> Epithelial apoptosis was measured by TUNEL [terminal deoxynucleotidyl transferase dUTP nick end labelling] staining in mouse colonic tissues, as previously described.<sup>24,25</sup> Five random fields were captured per tissue section, and the percentage of apoptotic cells in the total cell population was determined by an observer unaware of the treatments.

#### 2.2.4. Thrombin and PAR1 inhibition during experimental colitis in rats

Rats were randomly divided into control group without colitis [intracolonic administration of vehicle PBS, 100  $\mu$ l,  $n$  = 6] and two TNBS-induced colitis groups [intracolonic administration of TNBS 120 mg/ml in 50% ethanol], in which one was administered dabigatran [100  $\mu$ l, 5  $\mu$ M dabigatran intracolonic,  $n$  = 10], and the other one was administered drug vehicle [100  $\mu$ l, 0.1% dimethylsulphoxide,  $n$  = 6]. Intracolonic administrations of dabigatran or vehicle were performed daily during 4 days. Animals were euthanised by a lethal dose of pentobarbital. Disease activity index was evaluated daily throughout the experimentation based on: i) faecal consistency [0 for normal faeces, 1 for soft faeces, 2 for diarrhoea]; ii) rectal bleeding [0 for negative, 1 for positive, 2 for gross bleeding]; iii) prolapse [0 for negative, 1 for positive, 2 for gross prolapse]; and iv) the presence of abdominal mass [0 for negative, 1 soft abdominal mass, 2 hard abdominal mass].

#### 2.2.5. Oral administration of vorapaxar

Vorapaxar [PAR1 antagonist, CVasThera, 2.5 mg/kg] or its vehicle [0.1% dimethylsulphoxide in corn oil] was administered by daily oral gavage [100  $\mu$ l] to rats or mice. Vorapaxar administration was concomitant with daily intrarectal administration of thrombin [in mice], or was administered 1 h before TNBS instillation [in rats or mice].

#### 2.2.6. Histology and immunostaining in mouse tissues

Mouse colon tissues were formalin-fixed and paraffin-embedded. Slides were processed for haematoxylin-eosin conventional staining for histology analysis. Other tissues were embedded in OCT and cryopreserved at -80°C. Sections were fixed in 100% acetone and incubated with blocking solution [1% bovine serum albumin, 0.3% Triton X-100, PBS 1X] for 1 h. Sections were then incubated overnight at 4°C in the same solution containing anti-claudin-1 antibody [ref7178000 Invitrogen, 1/100 dilution] or anti-Zonula Occludens-1 [ZO1] antibody [ref402300 Invitrogen, dilution 1/100]. The secondary antibody used for detection was an anti-rabbit Alexa-488 used at 1/1000 dilution [ref A-21206 Invitrogen]. Slides were counterstained with DAPI [Invitrogen, France]. Representative images were obtained from blind acquisition of four random fields per animals [total of  $n$  = 3 per group]. We acquired all images on a Leica LSM 710 confocal microscope, and FIJI freeware was used for final image colouring and mounting [v 2.0].

#### 2.2.7. Measurements of thrombin activity in rat colonic samples

Serine protease activity was quantified in colonic washes from rats with BOC-val-pro-arg-amino-4-methylcoumarin [VPR-AMC] hydrochloride [200  $\mu$ M, Sigma-Aldrich B9395] as substrate in 50 mM Tris, 10 mM CaCl<sub>2</sub>, 150 mM NaCl, pH = 8.3. Initial velocity was calculated by the change in fluorescence [excitation: 355 nm,

emission: 460 nm], measured over 15 min at 37°C using a Varioskan Flash microplate reader [Thermo Fisher Scientific]. Thrombin specific proteolytic activity was accounted for in the VPR-AMC assay, by pre-incubating samples with dabigatran [1  $\mu$ M, Sigma] for 10 min at 37°C before starting enzymatic reaction.

#### 2.2.8. Statistics

Statistical comparisons among groups were performed according to dataset structure using either unpaired Student's or Mann-Whitney tests, one-way analysis of variance [ANOVA] followed by the Student-Newman-Keuls multiple comparison tests, and two-way ANOVA followed by Bonferroni multiple comparison tests. Outliers were identified using ROUT tests set at  $Q$  = 1%. Graphic representation and statistical analyses were performed using GraphPad Prism [v6, La Jolla, USA]. Data are expressed as mean  $\pm$  standard error means, and the N number in all groups appear in figures. Probability [ $p$ -value] was considered statistically significant at  $p$  < 0.05.

### 3. Results

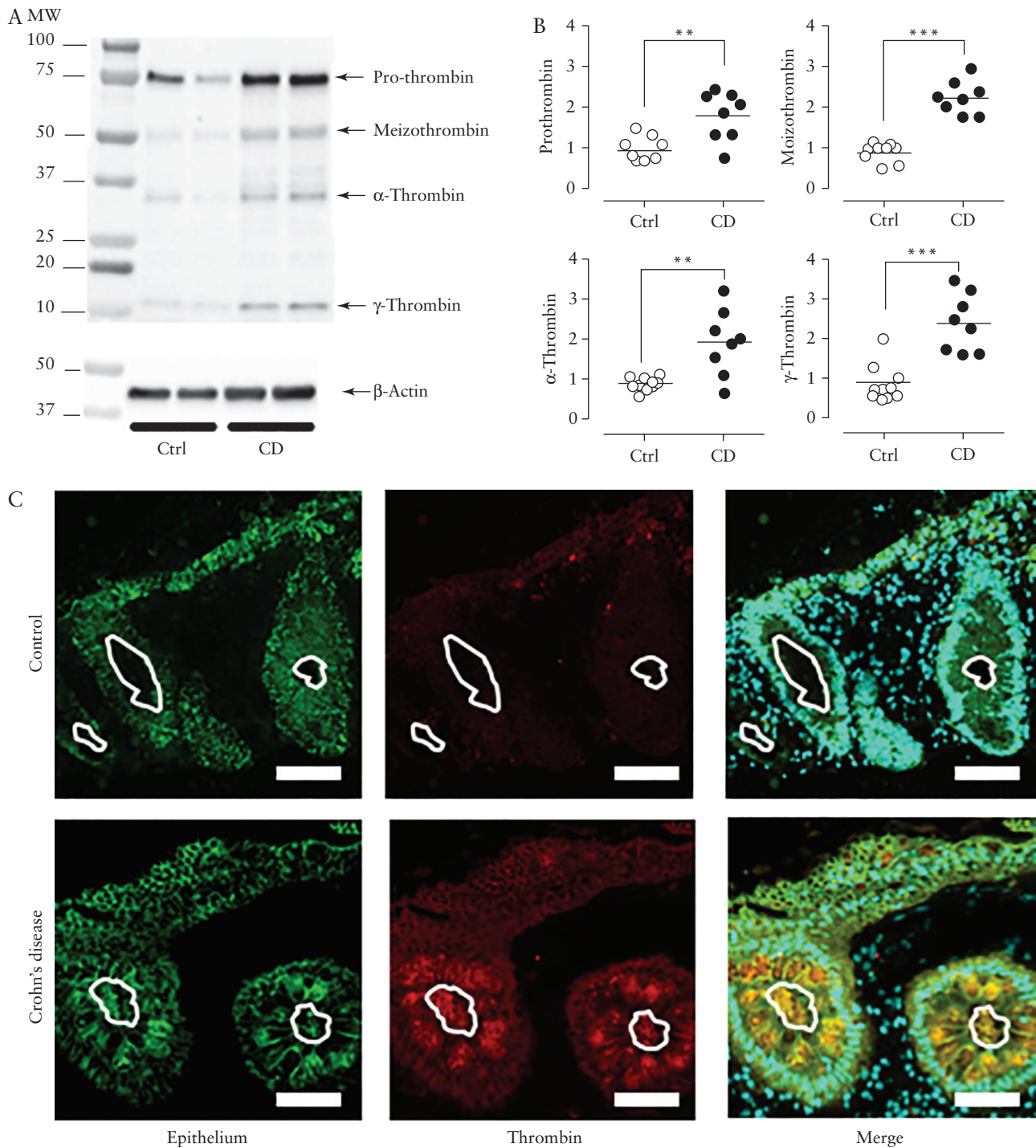
#### 3.1. Human studies

##### 3.1.1. Mucosal thrombin is upregulated upon intestinal inflammation

We and others have previously reported that thrombin activity released by tissues from IBD patients is significantly increased compared with tissues from healthy controls.<sup>5,10,11</sup> Here, we wanted to confirm that human intestinal tissues could indeed produce the thrombin protein, further identifying the presence of the different active and inactive forms of thrombin. We performed western blot analysis on tissue extracts of human biopsies [Figure 1A]. Under reducing conditions, thrombin bands<sup>26</sup> corresponding to the prothrombin form [~70 kDa], along with bands corresponding to active forms of thrombin: meizothrombin [~53 kDa], alpha-thrombin [~32 kDa], gamma-thrombin [~15 kDa] were detected in biopsy protein extracts from healthy controls and CD patients [Figure 1A]. Quantification of the detected bands revealed that prothrombin, alpha-thrombin, meizothrombin and gamma-thrombin forms were all significantly upregulated in biopsies from CD patients, compared with healthy controls [Figure 1B].

Immunohistochemistry showed that thrombin expression was associated with intestinal epithelial cells and was present at the mucosal surface of both healthy controls and CD patient tissues [Figure 1C]. We then used *in situ* zymography to gain more insights into the localisation of thrombin activity in human colonic tissues from IBD patients [two examples of CD patient tissues, Supplementary Figure 2, available as Supplementary data at ECCO-JCC online], using the fluorogenic thrombin substrate VPR-AMC. We observed that the thrombin activity detected in tissues from CD patients was elevated in the mucosa and the submucosa, showing a strong association with the epithelium [Supplementary Figure 2, left panels]. The detected tissue activity was inhibited by incubation with dabigatran, a thrombin inhibitor classically used therapeutically [Supplementary Figure 2, right panels]. Proteolytic activity was also blocked using another thrombin inhibitor, lepirudin [not shown], hence confirming the specificity of thrombin activity detected *in situ* in the frozen colonic tissues.

Taken together, these results showed that thrombin is present both as prothrombin and in an active form in human mucosal tissues, with prominent expression and activity associated with the mucosa. Mucosal thrombin activity is upregulated in IBD.



**Figure 1.** Representative western blot analysis [A] and relative abundance quantification [B] of thrombin protein expression in protein extracts from human colonic biopsies harvested from healthy control or Crohn's disease [CD] patients, and incubated for 1 h in PBS buffer. Bands with different molecular weights and corresponding to different forms of thrombin [prothrombin, meizothrombin,  $\alpha$ -thrombin,  $\beta$ -thrombin,  $\gamma$ -thrombin] were detected [A] and quantified [B]. Significant difference compared with controls were noted by \*\* for  $p < 0.01$  and \*\*\* for  $p < 0.005$ , Student's t test. [C] Immunohistochemistry for nuclei [DAPI staining in Cyan], epithelial cell marker [EpCAM, epithelial cell adhesion molecule, green], and thrombin [red] expression in human colonic biopsies harvested from healthy controls or CD patients. Lines indicate the limit between intestinal epithelium and lumen. Scale bar is 50  $\mu$ m.

### 3.2. Experimental models

#### 3.2.1. Thrombin activity is also upregulated in TNBS-induced experimental colitis

In a rat model of colitis, where inflammation was induced by the intracolonic administration of TNBS in 50% ethanol, we detected

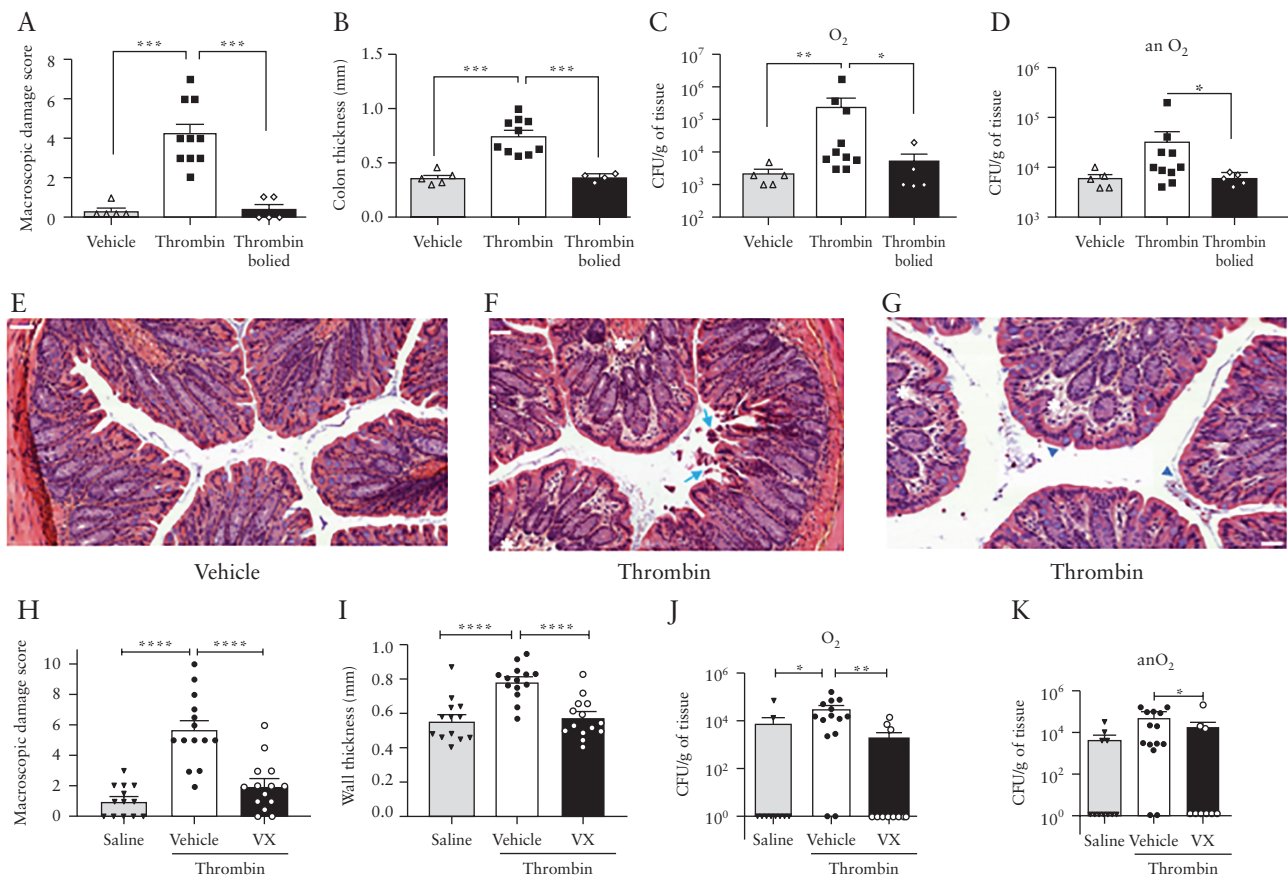
specific thrombin activity in colonic washes 7 days after the induction of colitis. This activity was compared with the activity detected in colonic washes of rats that had received saline [0.9% NaCl] intracolonic administration. Like in CD patients, we observed that inflamed rat colons released significantly higher thrombin activity

compared with non-inflamed rat colons [9.1-fold increase in TNBS colitis versus healthy controls [Supplementary Figure 3](#), available as [Supplementary data at ECCO-JCC online](#)].

### 3.2.2. Luminal thrombin upregulation recapitulates mucosal inflammation

Since thrombin activity was upregulated in the lumen of inflamed colon [human and rats], we hypothesised that thrombin itself might lead to an inflammatory response in colon tissues. We had previously determined that the ambient physiological range of thrombin activity in healthy colon luminal samples is in the range of 20 U/ml [200 nM] per day in humans and 1.5 U/ml [15 nM] per day in mice.<sup>9</sup> Relative to disease-free individuals, thrombin activity was five times and 98 times increased in tissues from UC and CD patients, respectively.<sup>5</sup> Therefore, to evaluate the impact of elevated luminal thrombin levels on the mouse colon *in vivo*, we chose a concentration equivalent to that observed in CD patients [100 U/ml, 1  $\mu$ M]. We observed that daily intracolonic administration of thrombin [50  $\mu$ l of 100 U/ml per mouse], but not boiled thrombin [same dose] caused macroscopic damage [Figure 2A] and a significant increase of colon thickness [Figure 2B], compared with vehicle [saline]-treated mice. When administered intracolonic, active thrombin also caused the translocation of aerobic bacteria into mesenteric lymph nodes, suggesting a disrupted intestinal barrier function [Figure 2C]. Translocation

of anaerobic bacteria was not significantly different in thrombin-treated mice, compared with the intracolonic administration of vehicle or boiled thrombin intracolonic administration [Figure 2D]. Histology sections of mouse distal colon showed no specific histological damage in mice that were treated intracolonic with vehicle [Figure 2E]. However, moderate oedema [stars in Figure 2F and G], epithelial erosion [arrows in Figure 2F and in [Supplementary Figure 4](#), available as [Supplementary data at ECCO-JCC online](#) for higher magnification], and some inflammatory cell transepithelial passage [arrow heads in Figure 2G and in [Supplementary Figure 4](#) for higher magnification] were observed in distal colons of mice that were treated daily with intracolonic thrombin. Occasionally, some depletion of mucus cells could also be observed in tissues from these mice [not shown]. However, no massive inflammatory cell infiltration or transmural inflammation was observed. We investigated the effects of thrombin further for its impact on colonic tight junction integrity, by performing immunofluorescence staining of ZO1 or claudin-1 in mouse colons [[Supplementary Figure 5](#), available as [Supplementary data at ECCO-JCC online](#)]. The intracolonic administration of thrombin disrupted the continuous ZO1 or claudin-1 staining observed in colons, compared with control mice that had received intracolonic PBS [arrows upper left panel, [Supplementary Figure 5](#)]. Instead, both ZO1 and claudin-1 staining were severely disorganised compared with control [PBS]. Clustered ZO1 staining



**Figure 2.** Colonic macroscopic damage score [A and H], colon thickness [B and I], aerobic [C and J], and anaerobic [D and K] bacteria translocated to mesenteric lymph nodes, distal colon histological sections [E, F, G] in mice that have received daily intracolonic administration of vehicle [E for histology], thrombin [50  $\mu$ l of 100 U/ml in saline] [F, G for histology], or boiled thrombin [same dose] for 10 days, and in mice that have been treated additionally with oral vehicle or vorapaxar [2.5 mg/kg] [H, I, J, K]. Panels F and G are two representative examples of histological sections of distal colon from mice that have received the same treatment. Significant differences compared with thrombin-treated mice were noted by \* for  $p < 0.05$ , \*\* for  $p < 0.01$ , and \*\*\* for  $p < 0.001$ , ANOVA with Newman-Keuls post hoc test.

and punctated claudin-1 staining were observed upon thrombin exposure, characteristic of morphological disruption of tight junctions [Supplementary Figure 5].

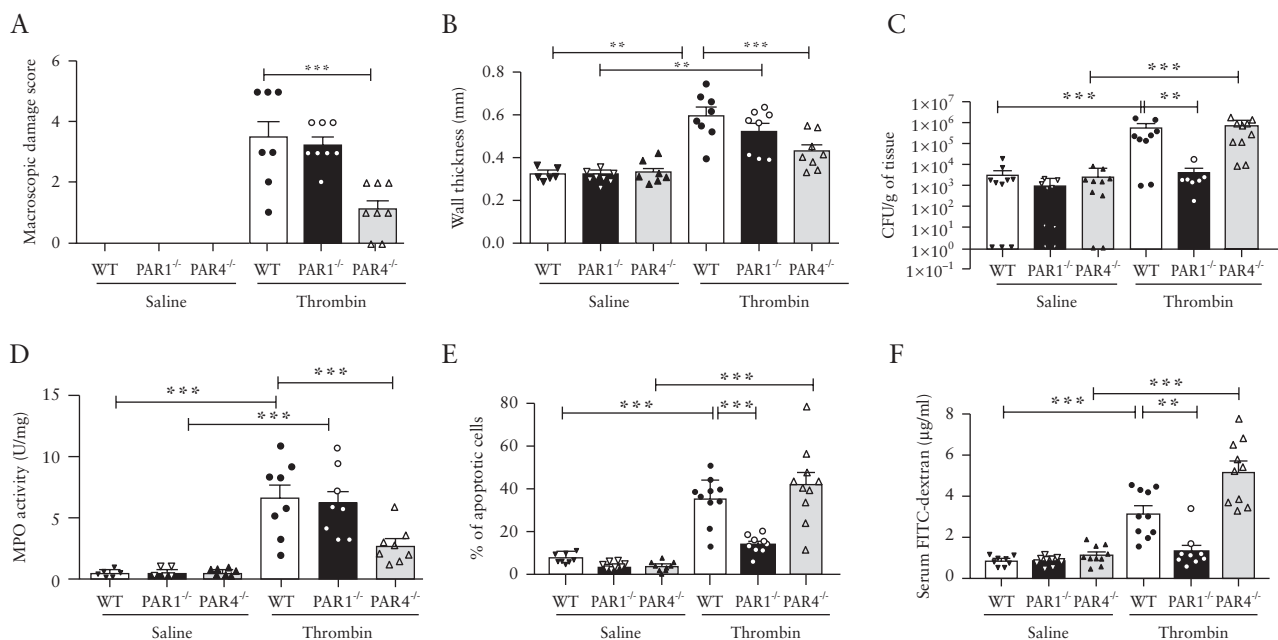
### 3.2.3. PAR activation is involved in thrombin-induced intestinal inflammation

We then investigated whether the proinflammatory effects of thrombin administered into the colon of mice were dependent on the activation of PAR1, the first identified thrombin receptor.<sup>27,28</sup> We first used a pharmacological approach, treating mice orally with the PAR1 antagonist vorapaxar. We observed that all the thrombin-induced signs of inflammation [increased macroscopic damage score, wall thickness and bacterial translocation] were significantly inhibited by treating mice orally with the PAR1 antagonist vorapaxar [Figure 2G–J]. The disrupted ZO1 staining and the disrupted claudin-1 staining observed in mouse colons after exposure to thrombin were also ameliorated by vorapaxar treatment of mice [Supplementary Figure 5]. We then employed a genetic approach, using mice deficient for the two signalling thrombin receptors: PAR1 and PAR4. We administered thrombin intracolonic as described above, in WT as well as in PAR1- or PAR4-deficient mice. In accordance with the data described above, we observed that in WT mice that thrombin caused signs of inflammation characterised by an increased macroscopic damage score, increased colonic wall thickness, and increased bacterial translocation [Figure 3A–C]. In addition, we followed MPO activity, apoptosis, and permeability [as measured by the passage of FITC dextran] [Figure 3D–F]. All of these inflammatory parameters were significantly increased in WT mice that received an intracolonic administration of thrombin [100 U/ml per day per mouse] compared with mice that received intracolonic saline alone [Figure 3]. In comparison with the WT animals, PAR1-deficient mice did not show increased bacterial translocation, apoptosis, or permeability in response to intracolonic thrombin [Figure 3C, E, and F], but still exhibited significant macroscopic damage, increased colonic

wall thickness, and elevated MPO activity [Figure 3A, B, and D]. In contrast, thrombin-induced damage score, increased wall thickness, and elevated MPO activity were significantly reduced in PAR4-deficient mice [Figure 3A, B, and D], whereas the thrombin-induced increase in bacterial translocation, apoptosis, and increased permeability were unchanged in the PAR4-null mice [Figure 3C, E, and F]. Taken together, these data showed that both PAR1 and PAR4 activation are involved in the inflammatory response to intracolonic administered thrombin. Thus, these two PARs appear to regulate different responses triggered by thrombin.

### 3.2.4. Thrombin-, PAR1- but not PAR4-inhibition protected against TNBS-induced colitis

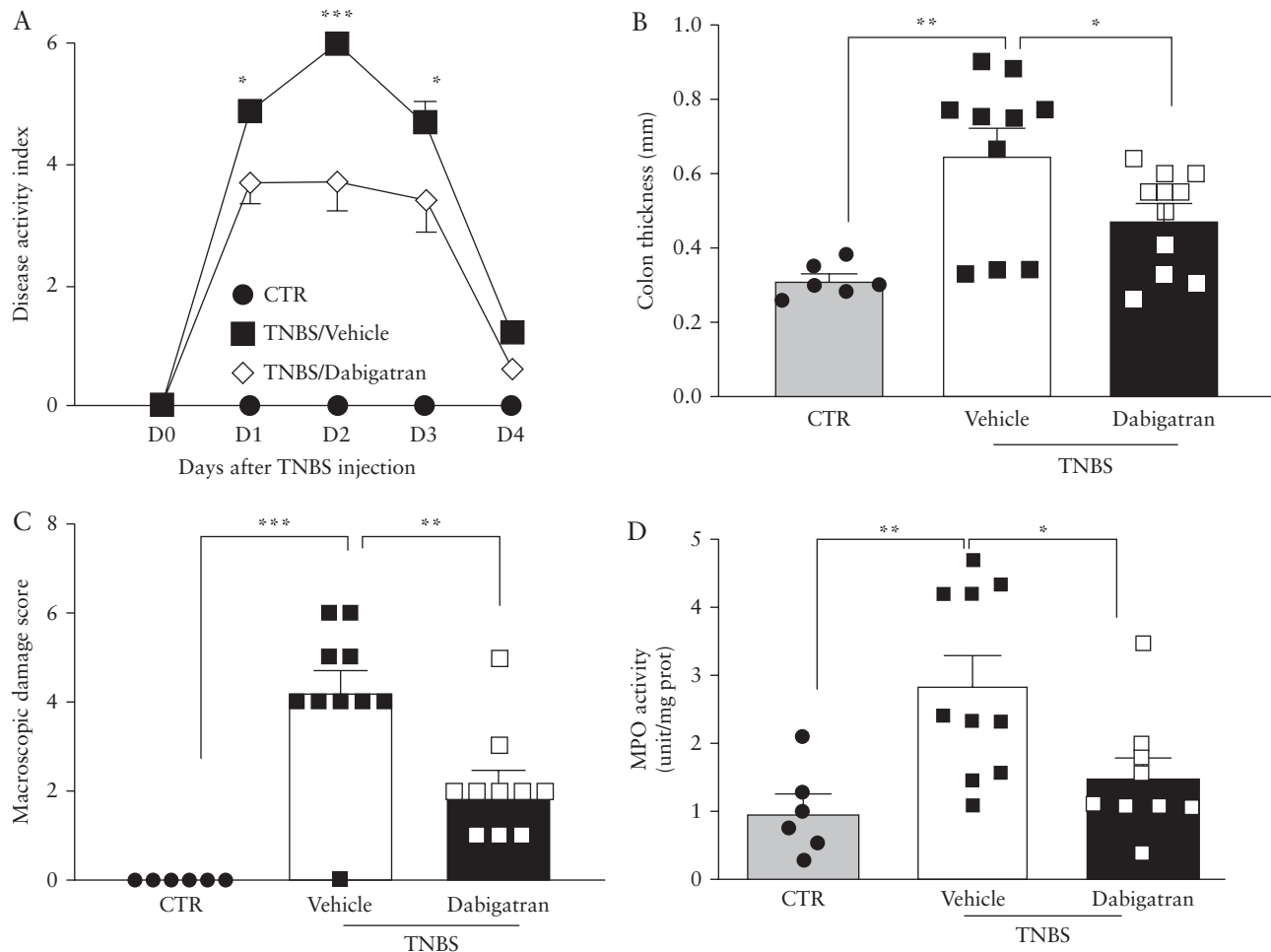
Having observed that the presence and activity of thrombin are substantially increased in colons of IBD patients and in IBD models, and that intracolonic thrombin itself can induce signs of inflammation, we next investigated the net contribution of thrombin to the generation of inflammatory signs and overall to disease in a rat model of colitis induced by the intracolonic administration of TNBS. Since we wanted to focus on the contribution of mucosal thrombin to colitis, it was important to inhibit thrombin activity locally in colonic tissues, rather than inhibiting systemic thrombin activity. Therefore, after the induction of colitis in rats by the intracolonic administration of TNBS, rats were treated daily by an intracolonic administration of the direct thrombin inhibitor dabigatran. In addition, since we aimed to investigate the contribution of thrombin to the generation of inflammatory signs, we choose to follow early inflammatory parameters [the first 4 days after TNBS colitis induction]. TNBS-induced colitis in rats caused a significant disease activity index and increased colon thickness, macroscopic damage score, and MPO activity [Figure 4]. Daily intracolonic administration of the direct thrombin inhibitor dabigatran protected rats from TNBS colitis, reducing significantly all of these inflammation parameters [Figure 4]. This result suggests that increased thrombin activity in the colon of TNBS-treated rats



**Figure 3.** Colon macroscopic damage score [A], wall thickness [B], bacterial translocation to mesenteric lymph nodes [C], myeloperoxidase [MPO] activity [D], percentage of apoptotic cells [E], and FITC-dextran passage to blood [F] in PAR1-deficient mice [PAR1<sup>-/-</sup>], PAR4-deficient mice [PAR4<sup>-/-</sup>], and littermates [wild-type] 10 days after daily intracolonic administration of saline or thrombin [50 µl of 100 U/ml in saline]. Significant differences compared with thrombin-treated mice were noted by \*\* for  $p < 0.01$  and \*\*\* for  $p < 0.005$ , ANOVA with Newman-Keuls post hoc test.

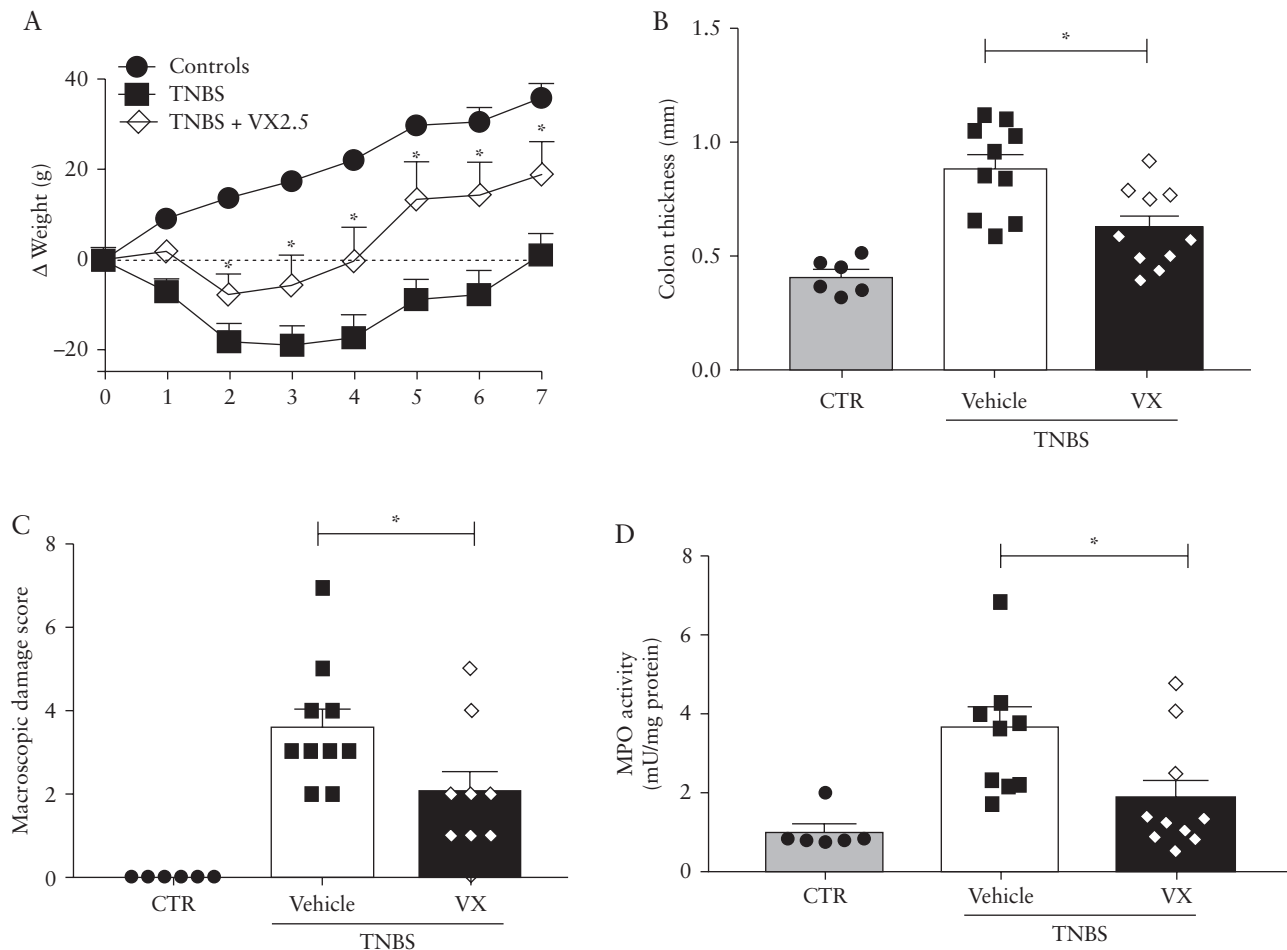
contributes to the development of intestinal inflammation. We then investigated the contribution of PAR1 to TNBS-induced colitis in rats, and its possible role in maintaining tissue damage and delaying mucosal repair. Rats in which colitis was induced by the intracolonic administration of TNBS were treated with the well-characterised PAR1 antagonist vorapaxar, at a dose previously reported to inhibit PAR1 activation *in vivo*. Weight loss, increased colon thickness and damage score, and elevated MPO activity, which are associated with colitis, were all significantly reduced by oral treatment with the PAR1 antagonist vorapaxar [Figure 5]. We also used the TNBS colitis model in mice [7 days of colitis] treated or not with the PAR1 antagonist vorapaxar. Similar to the rat model, increased wall thickness and macroscopic damage score were significantly inhibited by vorapaxar treatment [Figure 6]. However, weight loss was not modified by vorapaxar treatment in mice. PAR1 inhibition by oral treatment with vorapaxar was able to significantly inhibit TNBS-induced apoptosis, bacterial translocation of both aerobic and anaerobic bacteria, and increased permeability [Figure 6]. In terms of barrier disruption, ZO1 and claudin-1 staining were considerably degraded in colons of TNBS-treated mice [middle lower panels of Supplementary Figure 5]. Both stainings showed clusters and loss of the continuous staining

observed at the intestinal epithelial cell membrane in controls [PBS]. However, both tight junction proteins [ZO1 and claudin-1] integrity appeared to be preserved in distal colons of vorapaxar-treated mice that had also received TNBS [right lower panel of Supplementary Figure 5]. The data suggested that PAR1 activation is involved in ZO1 and claudin-1 disruption associated with TNBS. Taken together, these data demonstrate that both in rats and mice, PAR1 inhibition by the PAR1 antagonist vorapaxar treatment is protective against TNBS-induced colitis. Because there are no selective and easily bio-available PAR4 antagonists for *in vivo* use, in order to investigate the contribution of PAR4 in causing colitis, we used PAR4-deficient mice in which we induced colitis with TNBS. Seven days after receiving an intracolonic administration of TNBS, WT mice showed significant damage and increased colon thickness and MPO activity [Figure 7]. None of these inflammation-related parameters were different in PAR4-deficient mice compared with WT mice after the induction of TNBS colitis. Only weight loss 5 days after the induction of colitis was worse in PAR4-deficient mice, compared with WT. These results suggest that PAR4 inhibition does not protect from colitis and that PAR4 contributes only marginally in generating inflammation in that model [Figure 7].



**Figure 4.** Effect of daily intracolonic administration of dabigatran on TNBS-induced colitis in rats [ $n = 10$ ], compared with uninflamed controls [CTR, that have received intracolonic PBS administration,  $n = 6$ ]. A group of colitis rats [ $n = 10$ ] was treated daily with intracolonic administration of vehicle [saline]. Disease activity index was recorded daily [A], and at sacrifice, colon thickness [B], macroscopic damage score [C], and myeloperoxidase [MPO] activity [D] were measured. Significant differences compared with CTR and vehicle-treated rats were noted \* for  $p < 0.05$ , \*\* for  $p < 0.01$ , and \*\*\* for  $p < 0.001$ , two-way ANOVA with Bonferroni post hoc test in [A] and ANOVA with Newman-Keuls post hoc test for [B-D].





**Figure 5.** Effects of daily voropaxar oral treatments [2.5 mg/kg] on TNBS-induced colitis in rats, compared with uninflamed controls [receiving intracolonic PBS instead of TNBS in 50% ethanol]. Animal weight was recorded daily [A], and at sacrifice, colon thickness [B], macroscopic damage score [C], and myeloperoxidase [MPO] activity [D] were measured. Significant differences compared with vehicle-treated rats were noted by \* for  $p < 0.05$ , two-way ANOVA with Bonferroni post hoc test in [A] and ANOVA with Newman-Keuls post hoc test for [B-D].

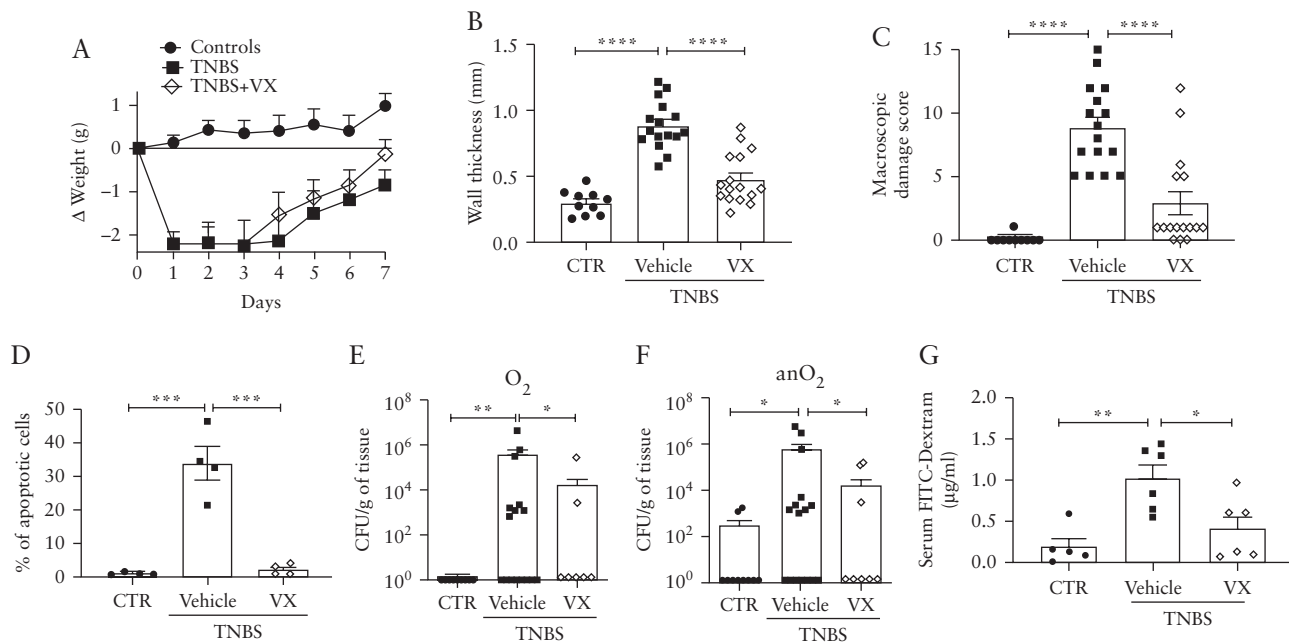
#### 4. Discussion

Although the implication of the haemostatic system in IBD has been investigated through the presence of haemostatic factors<sup>13,15,16</sup> or the effects of indirect thrombin inhibitors such as heparin on clinical and endoscopic disease parameters,<sup>17-19</sup> no study has clearly defined the role of local thrombin or other thrombosis factors in intestinal tissues. Is thrombin pro-inflammatory at the doses that are found in IBD patient tissues? What thrombin-induced signalling pathways would be involved in intestinal inflammation? Is thrombin a target for IBD treatment? Through the present study, we aimed at providing some answers to such questions.

In a previous study, we reported that thrombin activity is increased 100-fold in tissues from CD patients, compared with tissues from healthy controls.<sup>5</sup> What are the consequences for tissue homeostasis of such concentrations of active thrombin in the colon? We demonstrate here, in a murine model, that exposing colon mucosa to high thrombin activity *in vivo* causes signs of inflammation characterised by mucosal damage and increased epithelial permeability as observed by bacterial translocation. Further, we demonstrate in a rat model of colitis that thrombin activity is increased in the same proportions as in CD patient tissues [Supplementary Figure 3]. In that particular model, we demonstrated that local inhibition

of thrombin activity achieved by the intraluminal administration of the direct thrombin inhibitor dabigatran was protective, inhibiting both mucosal damage and granulocyte infiltration, and reducing the extent of intestinal inflammation [Figure 4]. Taken together, these results clearly demonstrated the deleterious effects of high doses of thrombin and reported the protection achieved by local thrombin inhibition in a model of IBD. Therefore, these results clearly point to mucosal thrombin inhibition as a possible target to treat intestinal inflammation and to reduce some inflammatory signs.

Thrombin exists under different forms. The inactive prothrombin form of ~70 kDa is proteolytically converted to active  $\alpha$ -thrombin [~32 kDa], which may be further hydrolysed to  $\beta$ - [~28 kDa] and  $\gamma$ -thrombin [~15 kDa]. In addition, a transient form of thrombin [meizothrombin, ~53 kDa] is an intermediate form of prothrombinase catalyst.<sup>29</sup> All the cleaved forms of prothrombin retain catalytic activities, and all have been demonstrated to play important physiological roles, including the activation of PARs.<sup>29-31</sup> We detected in protein extracts of human colonic biopsies prothrombin, meizothrombin,  $\alpha$ -thrombin, and  $\gamma$ -thrombin. All isoforms, including the inactive prothrombin form, were upregulated in CD patients. At this point, it is impossible to know which form of active thrombin might play a prominent role in inflammatory processes. In experiments where thrombin was administered intracolonic and induced signs of



**Figure 6.** Effects of daily voripaxar oral treatments [2.5 mg/kg] on TNBS-induced colitis in mice, compared with uninflamed controls [receiving intracolonic PBS instead of TNBS in 40% ethanol]. Animal weight was recorded daily [A], and at sacrifice, colon thickness [B], macroscopic damage score [C], percentage of apoptotic cells [D], aerobic [E] and anaerobic [F] bacteria translocated to mesenteric lymph nodes, and FITC-dextran passage to blood [G] were measured. Significant differences compared with vehicle-treated mice were noted by \* for  $p < 0.05$ , \*\* for  $p < 0.01$ , \*\*\* for  $p < 0.005$ , \*\*\*\* for  $p < 0.001$ , two-way ANOVA with Bonferroni post hoc test in [A] and ANOVA with Newman-Keuls post hoc test for [B-G].

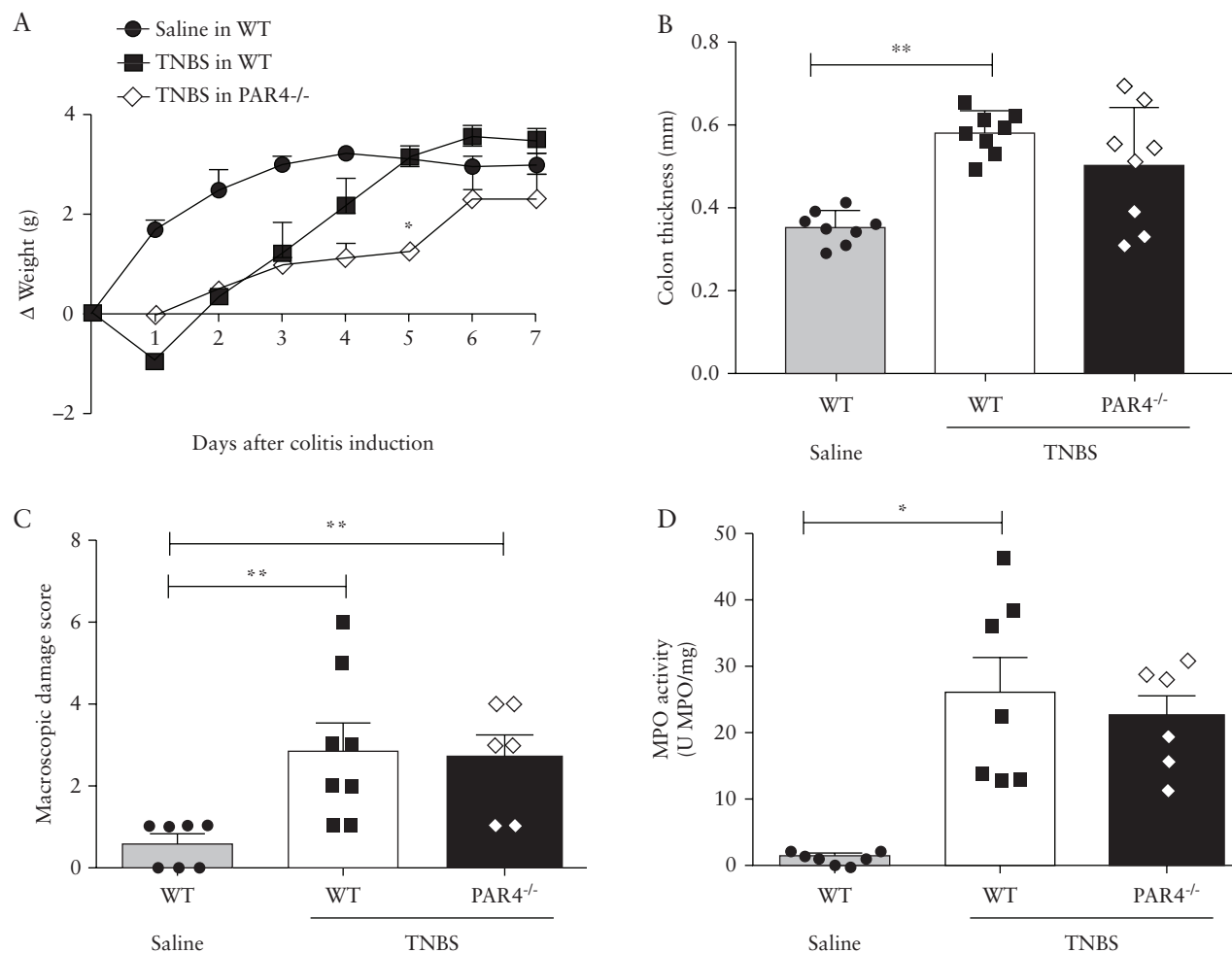
inflammation, human  $\alpha$ -thrombin was used. However, we cannot conclude that all the inflammatory signs observed were exclusively due to  $\alpha$ -thrombin, because upon its administration into the colon of mice, this form of thrombin might well undergo autolytic degradation into  $\beta$ - or  $\gamma$ -thrombin. Notwithstanding, our results demonstrated that catalytically active thrombin was involved in the generation of inflammation parameters. Indeed, inhibition of thrombin activity by local delivery of dabigatran protected from TNBS-induced colitis. The increased presence of all active forms of thrombin associated with IBD is also in favour of a role for proteolytically active thrombin in the colon of IBD patients.

Here, we also demonstrated that the pro-inflammatory effects of thrombin were mediated through the activation of both PAR1 and PAR4, acting on different parameters of inflammation. Intracolonic administration of active  $\alpha$ -thrombin provoked several inflammatory signs such as macroscopic damage, granulocyte infiltration, and increased wall thickness, all of which were significantly reduced in PAR4- but not in PAR1-deficient mice. Indeed, previous studies have reported that PAR4 activation, but not PAR1 activation, is responsible for thrombin-induced leukocyte rolling and adhesion in rat mesenteric venules.<sup>32</sup> Another report demonstrated in a model of paw inflammation, that oedema is formed as a consequence of PAR4-induced neutrophil recruitment,<sup>33</sup> thereby linking these two inflammatory parameters, oedema and leukocyte recruitment, to PAR4 activation. Our present observations are in complete agreement with these studies, as they point to a PAR4-dependent mechanism of action responsible for thrombin-induced granulocyte recruitment and increased wall thickness [most likely due to oedema]. Other thrombin-induced inflammatory signs included increased intestinal permeability, bacterial translocation, and increased epithelial apoptosis, which were all dependent on the activation of PAR1 but not PAR4. Previous reports have indeed identified that PAR1 activation in intestinal epithelial cells induced apoptosis leading to increased

intestinal permeability.<sup>24,25,34</sup> Therefore, in our study it is tempting to suggest that the thrombin-induced increased intestinal permeability and bacterial translocation were due to PAR1 activation on intestinal epithelial cells, and potentially to an overactivation of apoptotic pathways.

Using animal models of IBD, we observed that thrombin was overexpressed and overactivated, and that PAR1 inhibition appeared a better target than PAR4 to reduce colitis in this TNBS model. Several possible explanations could be proposed. In the TNBS model, other proteases such as elastase are also hyperactive,<sup>7,35</sup> which could disarm PAR4 by cleaving its N-terminal domain upstream from the canonical thrombin activation site, thereby becoming a non-signalling receptor.<sup>36-39</sup> The forms of thrombin that are released in the TNBS colitis model might have a preferred PAR1 substrate, compared with PAR4. It is known that  $\alpha$ -thrombin has a better affinity for PAR1 cleavage, and  $\beta$ - and  $\gamma$ -thrombin have a good affinity for PAR4 but not for PAR1 cleavage.<sup>30</sup> Finally, active thrombin present in colonic tissues with TNBS colitis might not be in the vicinity of PAR4-expressing cells, but rather close to PAR1-expressing cells.

The source of thrombin at mucosal surfaces is an intriguing question in the context of IBD. Tissue damage and ulcers are common features of IBD. Concomitant damage to blood vessels results from the activation of the clotting cascade and the associated on-site activation of circulating prothrombin. Part of the increased thrombin activity detected in IBD patient tissues might therefore originate from prothrombin recruitment and activation at injured sites. However, a recent study reports that intestinal epithelium is able to constitutively produce active thrombin.<sup>9</sup> In this study, the epithelial expression of thrombin was shown to be upregulated by the presence of intestinal microbes. A dysregulated epithelial production of active thrombin due to dysbiosis in the mucosal gut biofilm could well be associated with IBD. In the present study, *in situ* zymography [Supplementary Figure 2] and immunostaining



**Figure 7.** Effects of TNBS-induced colitis in wild-type [WT] and PAR4-deficient mice [PAR4<sup>-/-</sup>], compared with uninflamed controls [WT mice receiving intracolonic PBS instead of TNBS in 40% ethanol]. Animal weight was recorded daily [A], and at sacrifice, colon thickness [B], macroscopic damage score [C], and myeloperoxidase [MPO] activity [D] were measured. Significant differences compared with vehicle-treated mice were noted by \* for  $p < 0.05$ , and by \*\* for  $p < 0.01$ , two-way ANOVA with Bonferroni post hoc test in [A] and ANOVA with Newman-Keuls post hoc test for [B-D].

[Figure 1C] determined that a large amount of thrombin activity detected in tissues from CD patients was associated with the epithelium, giving credit to this hypothetical source of active thrombin in the context of IBD.

A major finding of this study is that high mucosal thrombin levels can be detrimental in IBD and can participate in inflammatory signs through the activation of PARs. Inhibition of thrombin activity could thus be considered for the treatment of IBD.<sup>17-19</sup> In agreement with our findings, previous studies have reported in tissues from IBD patients the formation of microthrombi in bowel capillaries, suggesting that prothrombotic status could be a determinant factor in IBD pathogenesis.<sup>15</sup> Increased morbidity and mortality associated with hyperthrombosis in IBD can be managed by available drugs.<sup>40</sup> However, the bleeding associated with IBD renders the guidance for anticoagulant thromboprophylaxis complicated in clinical practice.<sup>40</sup> In addition, it has recently been demonstrated that epithelial thrombin is required to preserve mucosal homeostasis, in part by maintaining spatial segregation between mucosal biofilms and host epithelium.<sup>9</sup> Although drugs are available for thrombin inhibition in humans, in the context of IBD the side effects of such approach on bleeding and on biofilm containment might be difficult to manage. Targeting downstream events

from high thrombin activity might thus be a better option for treating IBD. In the present study, we showed that PAR1 activation plays a major role in the pro-inflammatory effects of thrombin, and could therefore constitute a more appropriate target for IBD treatment. The compound we tested here [voropaxar] is a PAR1 antagonist that has been approved for human use for cardiovascular indications.<sup>41</sup> Of importance, PAR1 can be activated via many other proteinases found in inflammatory settings like IBD [e.g. tissue kallikreins/KLKs and neutrophil elastase]. Voropaxar would also block the PAR-activating inflammatory stimulus of these enzymes, along with that of thrombin. Considering our preclinical results with this compound, phase II clinical studies in IBD patients could therefore be rapidly envisioned, particularly in CD patients who seemed to present the highest levels of thrombin activity.

## Funding

This work was supported by a grant from the European Research Council [grant number ERC- 310973 PIPE] to NV, and by grants from the Canadian Institute of Health Research [to NV and MDH]. This work was also supported by an Occitanie region grant [‘contrat innovation’ reference: DEI-SYNAPSE] to CVasThera [SL, BL]. Tissue collection was originally sponsored by the

University Hospital of Toulouse for regulatory and ethical submission, and by a grant from the delegation régionale à la recherche clinique des hôpitaux de Toulouse, through the MICILIP project [NCT01990716]. The COLIC collection [DC-2015-2443] was also used in the present study. The work used the Aninfimip core facility equipment, supported by Equipex funds from the National 'Investments for the future' programme [grant number ANR-11-EQPX-0003]. JPM was funded by postdoctoral fellowships from the Alberta-Innovate Health Services [AIHS], from the EU's Seventh Framework Programme N° FP7-609398 [AgreenSkills + program], from Antibe Therapeutics and from CVasThera. Equipment acquired thanks to FEDER funding [EU and Occitanie region: Nanorgan project] was used in the present study.

## Conflict of Interest

SL and BL report employment by, and stock ownership, of CVasThera. JPM was employed in part by CVasThera over the period. All the other authors have nothing to disclose.

## Acknowledgments

We thank UMS 006 [animal care facility, histopathology core facility: F. Capilla, A. Alloy, and S. Milia] and the cellular imaging facility TRI-CPTP [D. Daviaud, Simon Labranche, and S. Allart, Toulouse].

## Author Contributions

JPM, SP, CG, KC, ADS, PR, LG, AE, DS, and CS acquired and analysed data. LA, DB, BB, LB, and CG provided human samples. JPM, CD, and NV performed study concept and design and analysis and interpretation of data. NV, CD, and JPM performed drafting of the manuscript. All the authors edited the manuscript. JPM, SL, BL, and NV obtained funding. AGB, JLW, EO, MDH, EB, SL, and BL reviewed data and provided intellectual input. NV supervised all aspects of this work. All authors had access to the study data, reviewed and approved the final manuscript.

## Supplementary Data

Supplementary data are available at *ECCO-JCC* online.

## References

- Ramos GP, Papadakis KA. Mechanisms of disease: inflammatory bowel diseases. *Mayo Clin Proc* 2019;**94**:155–65.
- Allaire JM, Crowley SM, Law HT, Chang SY, Ko HJ, Vallance BA. The intestinal epithelium: central coordinator of mucosal immunity. *Trends Immunol* 2018;**39**:677–96.
- Vergnolle N. Protease inhibition as new therapeutic strategy for GI diseases. *Gut* 2016;**65**:1215–24.
- Cenac N, Andrews CN, Holzhausen M, et al. Role for protease activity in visceral pain in irritable bowel syndrome. *J Clin Invest* 2007;**117**:636–47.
- Denadai-Souza A, Bonnart C, Tapias NS, et al. Functional proteomic profiling of secreted serine proteases in health and inflammatory bowel disease. *Sci Rep* 2018;**8**:7834.
- Rolland-Fourcade C, Denadai-Souza A, Cirillo C, et al. Epithelial expression and function of trypsin-3 in irritable bowel syndrome. *Gut* 2017;**66**:1767–78.
- Motta JP, Magne L, Descamps D, et al. Modifying the protease, antiprotease pattern by elafin overexpression protects mice from colitis. *Gastroenterology* 2011;**140**:1272–82.
- Róka R, Rosztóczy A, Leveque M, et al. A pilot study of fecal serine-protease activity: a pathophysiological factor in diarrhea-predominant irritable bowel syndrome. *Clin Gastroenterol Hepatol* 2007;**5**:550–5.
- Motta JP, Denadai-Souza A, Sagnat D, et al. Active thrombin produced by the intestinal epithelium controls mucosal biofilms. *Nat Commun* 2019;**10**:3224.
- Scalaferrri F, Lancellotti S, Pizzoferrato M, De Cristofaro R. Haemostatic system in inflammatory bowel diseases: new players in gut inflammation. *World J Gastroenterol* 2011;**17**:594–608.
- Saibeni S, Saladino V, Chantarangkul V, et al. Increased thrombin generation in inflammatory bowel diseases. *Thromb Res* 2010;**125**:278–82.
- Takeyama H, Mizushima T, Iijima H, et al. Platelet activation markers are associated with Crohn's disease activity in patients with low C-reactive protein. *Dig Dis Sci* 2015;**60**:3418–23.
- Owczarek D, Undas A, Foley JH, Nesheim ME, Jablonski K, Mach T. Activated thrombin activatable fibrinolysis inhibitor [TAFI] is associated with inflammatory markers in inflammatory bowel diseases TAFIa level in patients with IBD. *J Crohns Colitis* 2012;**6**:13–20.
- Zhang J, Guo Z, Yang W, et al. D-dimer levels are correlated with disease activity in Crohn's patients. *Oncotarget* 2017;**8**:63971–7.
- Souto JC, Martínez E, Roca M, et al. Prothrombotic state and signs of endothelial lesion in plasma of patients with inflammatory bowel disease. *Dig Dis Sci* 1995;**40**:1883–9.
- Kohoutova D, Pecka M, Cihak M, Cyrany J, Maly J, Bures J. Prevalence of hypercoagulable disorders in inflammatory bowel disease. *Scand J Gastroenterol* 2014;**49**:287–94.
- Stadnicki A. Involvement of coagulation and hemostasis in inflammatory bowel diseases. *Curr Vasc Pharmacol* 2012;**10**:659–69.
- Prajapati DN, Newcomer JR, Emmons J, Abu-Hajir M, Binion DG. Successful treatment of an acute flare of steroid-resistant Crohn's colitis during pregnancy with unfractionated heparin. *Inflamm Bowel Dis* 2002;**8**:192–5.
- Ang YS, Mahmud N, White B, et al. Randomized comparison of unfractionated heparin with corticosteroids in severe active inflammatory bowel disease. *Aliment Pharmacol Ther* 2000;**14**:1015–22.
- Vergnolle N, Coméra C, Moré J, Alvinerie M, Buéno L. Expression and secretion of lipocortin 1 in gut inflammation are not regulated by pituitary-adrenal axis. *Am J Physiol* 1997;**273**:R623–9.
- Vergnolle N, Coméra C, Buéno L. Annexin 1 is overexpressed and specifically secreted during experimentally induced colitis in rats. *Eur J Biochem* 1995;**232**:603–10.
- Hyun E, Andrade-Gordon P, Steinhoff M, Vergnolle N. Protease-activated receptor-2 activation: a major actor in intestinal inflammation. *Gut* 2008;**57**:1222–9.
- Woting A, Blaut M. Small intestinal permeability and gut-transit time determined with low and high molecular weight fluorescein isothiocyanate-dextrans in c3h mice. *Nutrients* 2018;**10**:685.
- Chin AC, Lee WY, Nusrat A, Vergnolle N, Parkos CA. Neutrophil-mediated activation of epithelial protease-activated receptors-1 and -2 regulates barrier function and transepithelial migration. *J Immunol* 2008;**181**:5702–10.
- Chin AC, Vergnolle N, MacNaughton WK, Wallace JL, Hollenberg MD, Buret AG. Proteinase-activated receptor 1 activation induces epithelial apoptosis and increases intestinal permeability. *Proc Natl Acad Sci U S A* 2003;**100**:11104–9.
- Thakur R, Chattopadhyay P, Ghosh SS, Mukherjee AK. Elucidation of procoagulant mechanism and pathophysiological significance of a new prothrombin activating metalloprotease purified from *Daboia russelii russelii* venom. *Toxicon* 2015;**100**:1–12.
- Rasmussen UB, Vouret-Craviari V, Jallat S, et al. cDNA cloning and expression of a hamster alpha-thrombin receptor coupled to Ca<sup>2+</sup> mobilization. *FEBS Lett* 1991;**288**:123–8.
- Vu TK, Wheaton VI, Hung DT, Charo I, Coughlin SR. Domains specifying thrombin-receptor interaction. *Nature* 1991;**353**:674–7.
- Stojanovski BM, Pelc LA, Zuo X, Pozzi N, Cera ED. Enhancing the anticoagulant profile of meizothrombin. *Biomol Concepts* 2018;**9**:169–75.
- Soslau G, Goldenberg SJ, Class R, Jameson B. Differential activation and inhibition of human platelet thrombin receptors by structurally distinct alpha-, beta- and gamma-thrombin. *Platelets* 2004;**15**:155–66.
- Bradford HN, Krishnaswamy S. Meizothrombin is an unexpectedly zymogen-like variant of thrombin. *J Biol Chem* 2012;**287**:30414–25.
- Vergnolle N, Derian CK, D'Andrea MR, Steinhoff M, Andrade-Gordon P. Characterization of thrombin-induced leukocyte rolling and adherence: a potential proinflammatory role for proteinase-activated receptor-4. *J Immunol* 2002;**169**:1467–73.

33. Houle S, Papez MD, Ferazzini M, Hollenberg MD, Vergnolle N. Neutrophils and the kallikrein-kinin system in proteinase-activated receptor 4-mediated inflammation in rodents. *Br J Pharmacol* 2005;146:670–8.
34. Sébert M, Denadai-Souza A, Quaranta M, et al. Thrombin modifies growth, proliferation and apoptosis of human colon organoids: a protease-activated receptor 1- and protease-activated receptor 4-dependent mechanism. *Br J Pharmacol* 2018;175:3656–68.
35. Motta JP, Bermúdez-Humarán LG, Deraison C, et al. Food-grade bacteria expressing elafin protect against inflammation and restore colon homeostasis. *Sci Transl Med* 2012;4:158ra144.
36. Oikonomopoulou K, Hansen KK, Saifeddine M, et al. Kallikrein-mediated cell signalling: targeting proteinase-activated receptors [PARs]. *Biol Chem* 2006;387:817–24.
37. Oikonomopoulou K, Hansen KK, Saifeddine M, et al. Proteinase-mediated cell signalling: targeting proteinase-activated receptors [PARs] by kallikreins and more. *Biol Chem* 2006;387:677–85.
38. Renesto P, Si-Tahar M, Moniatte M, et al. Specific inhibition of thrombin-induced cell activation by the neutrophil proteinases elastase, cathepsin G, and proteinase 3: evidence for distinct cleavage sites within the aminoterminal domain of the thrombin receptor. *Blood* 1997;89:1944–53.
39. Dulon S, Leduc D, Cottrell GS, et al. *Pseudomonas aeruginosa* elastase disables proteinase-activated receptor 2 in respiratory epithelial cells. *Am J Respir Cell Mol Biol* 2005;32:411–9.
40. Nguyen GC, Bernstein CN, Bitton A, et al. Consensus statements on the risk, prevention, and treatment of venous thromboembolism in inflammatory bowel disease: Canadian Association of Gastroenterology. *Gastroenterology* 2014;146:835–48.e6.
41. Baker NC, Lipinski MJ, Lhermusier T, Waksman R. Overview of the 2014 Food and Drug Administration Cardiovascular and Renal Drugs Advisory Committee meeting about vorapaxar. *Circulation* 2014;130:1287–94.