

# Efficacy of riboflavin/UV-A corneal phototherapy as stand-alone treatment for ulcerative keratitis in horses

ANDREA MARCHEGIANI<sup>1\*</sup>, MARILENA BAZZANO<sup>1</sup>, MARIA PAOLA CASSARANI<sup>1</sup>,  
ROLANDO ARCELLI<sup>2</sup>, CLAIRE ORZALESI<sup>2</sup>, GIUSEPPE LOMBARDO<sup>3,4</sup>,  
MARCO LOMBARDO<sup>4,5</sup>, ANDREA SPATERNA<sup>1</sup>, RODOLFO GIALLETTI<sup>2</sup>

<sup>1</sup>School of Biosciences and Veterinary Medicine, University of Camerino,  
Matelica (Macerata), Italy

<sup>2</sup>Department of Veterinary Medicine, University of Perugia, Perugia, Italy

<sup>3</sup>CNR-IPCF, Istituto per i Processi Chimico-Fisici, Messina, Italy

<sup>4</sup>Vision Engineering Italy srl, Rome, Italy

<sup>5</sup>Studio Italiano di Oftalmologia, Rome, Italy

\*Corresponding author: [andrea.marchegiani@unicam.it](mailto:andrea.marchegiani@unicam.it)

**Citation:** Marchegiani A, Bazzano M, Cassarani MP, Arcelli R, Orzalesi C, Lombardo G, Lombardo M, Spaterna A, Gialletti R (2021): Efficacy of riboflavin/UV-A corneal phototherapy as stand-alone treatment for ulcerative keratitis in horses. *Vet Med-Czech* 66, 321–329.

**Abstract:** The purpose of this study was to assess the efficacy of riboflavin/UV-A corneal phototherapy in comparison with topical antimicrobials for the treatment of corneal ulcers in horses. Nineteen horses with a diagnosis of corneal ulceration were randomised to receive either corneal phototherapy (11 horses) or topical antimicrobial therapy (8 horses). The corneal phototherapy consisted in the application of a riboflavin-enriched ophthalmic solution onto the cornea for 20 min followed by cornea UV-A irradiation at 30 mW/cm<sup>2</sup> for 3 min using a point-of-care UV-A device. A complete ophthalmological examination was performed at enrolment and then at day 1, 3, 7, 14, 21, 28, 35, 42, and 49 after treatment. The corneal ulcer was considered healed when the fluorescein staining was negative. The corneal phototherapy succeeded in the complete corneal wound healing in 91% cases (10/11 horses) by 12.7 ± 5.5 days. In the topical antimicrobial group, no horse showed improvement of the corneal ulceration (0/8; 0%) and two eyes had a corneal perforation. Six horses, due to an enlarged corneal lesion, underwent corneal phototherapy at day 14 and achieved complete wound healing by 17.2 ± 5.5 days in 83% cases (5/6). The corneal phototherapy was shown to be an effective and safe treatment for equine corneal ulcers.

**Keywords:** corneal collagen cross-linking; corneal melting; equine; photobiomodulation

Corneal ulcers are the most common type of ocular ailment in horses. The majority of equine corneal ulcers are secondary to trauma and running races have shown to be the cause in several cases (Brooks et al. 2016). Corneal ulcerations can have sight threatening consequences if not adequately

treated. Immediate medical attention and treatment are needed, since corneal ulcers may evolve quickly to serious complications, including corneal melting, which may lead to vision loss (Andrew et al. 2003; Galan et al. 2009; Wada et al. 2010; Voelter-Ratson et al. 2014; Brooks et al. 2016). Because

The research presented in the present paper and publication of the results was funded by Vision Engineering Italy srl.

<https://doi.org/10.17221/60/2020-VETMED>

of the high prevalence of corneal ulcers, equine practitioners are likely to face corneal ulcerations (Wada et al. 2010). The most frequently isolated micro-organisms from equine ulcerative keratitis include Gram negative bacteria (48%), Gram positive bacteria (42%), and fungi (8%) (Andrew et al. 1998; Wada et al. 2010).

Currently, the first-choice therapy for corneal ulceration is represented by the topical instillation of antibiotics/antimycotic agents and collagenase inhibitors, possibly delivered with a sub-palpebral lavage system, as previously described (Brooks et al. 2016). Due to the diverse flora, antibiotic combinations are, therefore, popular in the treatment of equine corneal ulcers (Brooks et al. 2016). Nevertheless, when treating corneal ulcers, the instillation frequency of an antimicrobial (or a combination of antimicrobials) is of utmost importance. Since many antibiotics are completely lost from the tear film within a few minutes post-instillation, the use of a sub-palpebral lavage system, which delivers topical liquid medication onto the surface of the equine cornea, is often preferred (Dennis et al. 2019).

There is high demand for solving the need of more effective therapies for ulcerative keratitis (Sauer et al. 2003). Riboflavin/UV-A corneal cross-linking is a procedure based on the exposure of a photosensitiser (i.e., riboflavin) to UV-A light (365 nm), whose mechanism of action is based on the generation of riboflavin triplets and reactive oxygen species (ROS). ROS are responsible for the peroxidation of lipids in cell membranes of microorganisms and the generation of additional covalent bonds between corneal stromal proteins, which, in turn, halt tissue destruction (Spoerl et al. 2007; Hayes et al. 2013; Perazzi et al. 2018a; Perazzi et al. 2018b; Perazzi et al. 2020). Former studies have shown that, at the beginning of the irradiation phase, high UV-A irradiance (30 mW/cm<sup>2</sup>) induces the rapid photodegradation of riboflavin in the corneal stroma than a lower irradiance (3 mW/cm<sup>2</sup>) (Lombardo et al. 2015; Lombardo and Lombardo 2019), and may favour a cytotoxic effect by the lipid peroxidation of cell membranes for sterilising the irradiated area, thus characterising the direct antimicrobial effect of the procedure (Cabiscol et al. 2000; Pot et al. 2014; Famose 2015). For this reason, in this manuscript, the term corneal phototherapy is preferred to corneal cross-linking, which rather emphasises the mechanism of tissue strength-

ening induced by treatment (Spoerl et al. 2004; Sondergaard et al. 2013).

There are a few reports on the safety and efficacy of the procedure in equine patients in which a corneal phototherapy has been applied as an adjunctive treatment for corneal stromal ulcers, melting ulcers and as a potential alternative to prophylactic antibiotic treatments for noninfected stromal ulcers (Gallhoefer et al. 2016; Hellander Edman et al. 2019). The present study aimed to investigate the efficacy of a riboflavin/UV-A corneal phototherapy as a stand-alone treatment in comparison with a topical medical therapy for treating corneal ulcers in horses.

## MATERIAL AND METHODS

### Patients and enrolment criteria

This prospective, randomised, controlled clinical trial has successfully been submitted to the university animal care and use committee; a written informed consent was obtained from all the owners of the participants before enrolment in the study. The enrolment criteria were the clinical diagnosis of ulcerative or melting keratitis. Exclusion criteria included corneal perforation or descemetocele. The participants were randomly allocated to receive either the corneal phototherapy or topical antimicrobials. The clinical investigators were blind to the treatment until the participant enrolment. Only one eye per participant was enrolled in the study.

Each participant underwent a complete ophthalmic examination by a board-certified ophthalmologist at enrolment and then at day 1, 3, 7, 14, 21, 28, 35, 42, and 49 after treatment. The ophthalmic examination included a slit-lamp, corneal fluorescein staining, and corneal photography. Culture and sensitivity samples were collected from all the participants at enrolment before commencing any treatment.

### Randomisation and study intervention

The participants were randomly allocated by a blocking randomisation model to receive either the corneal phototherapy alone (i.e., the study or phototherapy group) or the topical antimicrobials (i.e., the control or antimicrobial group); an author, who was completely blind to the medical examina-

<https://doi.org/10.17221/60/2020-VETMED>

tion, generated the randomisation. Per-protocol, if a case did not show any improvement, or even the worsening of the corneal lesion (i.e., widened ulcer), during the first 14 days of the follow-up, it was switched to the other group (e.g., from the control to study group or *vice versa*).

The horses randomised in the study group underwent a single application of corneal phototherapy as a stand-alone treatment; no other preoperative or postoperative medication was given. The participants who were randomised in the control group were treated with topical antimicrobials based on the culture and sensitivity testing. In the case of a negative (sterile) culture, combination antibiotics (chloramphenicol, colistimethate, tetracycline and ofloxacin or tobramycin) plus miconazole were given to the participant. A sub-palpebral lavage system was placed to deliver the topical medication onto the surface of the cornea in all the cases, thus avoiding any bias caused by the variable participants' compliance with the medication.

The corneal ulcer diameter was used to determine any improvement or worsening of the ulcerative lesion during the follow-up and to decide whether to switch the participant to either group; an improvement of less than 20% in the diameter at day 14 was defined as the threshold to switch the participant to either group. Corneal melting was diagnosed if a stromal liquefaction and malacia was present in the site of ulcer. A corneal ulcer was considered healed when no fluorescein staining was detectable.

### Corneal phototherapy

The corneal phototherapy was performed under sedation. The horses were sedated intravenously with acepromazine 0.03 mg/kg (Prequillan<sup>®</sup>; Fatro, Bologna, Italia) in association with detomidine 20 µg/kg (Domosedan<sup>®</sup>; Pfizer, Rome Italia) or xylazine 0.6 mg/kg (Rompun<sup>®</sup>; Bayer, Milan, Italia). For eyelid akinesia, the horses received a supraorbital and auriculopalpebral nerve block, using 2% lidocaine (Lidocaina 2%; Esteve, Milan, Italia). For topical anaesthesia, two drops of oxybuprocaine (Novesina<sup>®</sup>; Novartis, Origgio, Italia) were instilled after the bacterial and fungal sampling. The corneal phototherapy consisted of the application of a hypotonic 0.1% riboflavin ophthalmic solution (Visioflavin<sup>®</sup>; Vision Engineering Italy, Rome, Italy) for 20 min onto the cornea using a ring applicator and a foam. Thereafter,

a UV-A light beam generated by a point-of-care device (Vetuvir<sup>®</sup>; Vision Engineering Italy, Rome, Italy) was focused over an area of 9 mm in diameter for 3 min at a 30 mW/cm<sup>2</sup> UV-A irradiance (wavelength: 365 nm; total energy dose: 5.4 J/cm<sup>2</sup>). In the case of ulcers larger than 9 mm in diameter, the UV-A irradiation of the cornea was performed twice avoiding illuminating the same area. All the eyes received a single corneal phototherapy treatment.

### Statistical analysis

The primary efficacy outcome of the study was the complete corneal wound healing, which was determined as the negative fluorescein staining of the corneal epithelium. All the data were reported as the mean ± standard deviation. The differences in the complete corneal wound healing and time to healing between the groups were evaluated using the Wilcoxon rank sum (Mann-Whitney *U*) test for unpaired data. All the statistical analyses were run with GraphPad Prism for Windows v8 (GraphPad Software, San Diego, CA, USA).

### RESULTS

Nineteen (19) horses were enrolled in the study and all of them completed the follow-up. Eleven (11) and eight (8) participants were randomised to the study and control group, respectively. All the horses were diagnosed with a corneal ulceration and no melting was highlighted at enrolment nor during the follow-up. No reflex uveitis was present at enrolment. The corneal ulcer size at enrolment did not significantly statistically differ between groups, being  $17.3 \pm 7.7$  mm<sup>2</sup> and  $17.9 \pm 10.5$  mm<sup>2</sup> ( $P = 0.89$ ) in the study and control group, respectively. At enrolment, all the ulcers were deeper than 50% of the stromal thickness. The location of the corneal ulcer (central or peripheral) and degree of neovascularisation (none, mild, high) in the study and control groups are reported in Tables 1 and 2, respectively. In the study group (Table 1 and Figures 1 and 2), eight out of eleven eyes were positive for a microbial culture; four eyes were positive to *Aspergillus* spp. and the others to bacteria (*Streptococcus pyogenes*, *Pseudomonas aeruginosa*, *Staphylococcus* spp., *E. coli*). Ten out of eleven horses (10/11; 91%) achieved complete corneal wound healing

<https://doi.org/10.17221/60/2020-VETMED>

Table 1. Isolated microorganisms, ulcer size, localisation, and degree of neovascularisation at enrolment, days to healing and the clinical outcome in the horses that underwent a single corneal phototherapy treatment (study group)

Code	Isolated microorganisms	Ulcer size at enrolment (mm <sup>2</sup> )	Ulcer location at enrolment	Degree of neovascularisation at enrolment	Days to healing	Outcome
A1	Negative	21.98	central	none	7	healed
A2	<i>Aspergillus</i> spp.	16.49	peripheral	none	15	healed
A3	<i>Streptococcus pyogenes</i>	18.84	peripheral	none	5	healed
A4	Negative	23.55	central	none	21	healed
A5	Negative	11.78	peripheral	mild	14	healed
A6	<i>Aspergillus</i> spp.	15.70	peripheral	none	12	healed
A7	<i>Aspergillus</i> spp.	9.42	central	high	–	perforation at day 21
A8	<i>Aspergillus</i> spp.	9.42	central	mild	13	healed
A9	<i>Pseudomonas aeruginosa</i> , <i>Aspergillus</i> spp.	35.33	peripheral	none	20	healed
A10	<i>Pseudomonas aeruginosa</i> , <i>Aspergillus</i> spp.	10.99	central	mild	14	healed
A11	<i>Staphylococcus</i> spp., <i>Pseudomonas</i> spp.	16.49	peripheral	high	6	healed

Table 2. Isolated microorganisms, ulcer size, localisation, and degree of neovascularisation at enrolment and at switching (day 14) to the corneal phototherapy, days to healing and the clinical outcome in the horses of control group

Code	Isolated microorganisms	Ulcer size at enrolment (mm <sup>2</sup> )	Ulcer location at enrolment	Degree of neovascularisation at enrolment	Ulcer size at switching (mm <sup>2</sup> )	Ulcer location at switching	Degree of neovascularisation at switching	Days to healing after switching to VET-CXL	Outcome
C1	<i>Aspergillus</i> spp., <i>Alternaria</i> spp.	27.48	central	high	–	–	–	–	perforation at day 7
C2	<i>Aspergillus</i> spp., <i>Alternaria</i> spp., <i>Enterobacter</i> spp., <i>E. coli</i>	7.07	central	high	9.42	central	high	21	healed by corneal phototherapy
C3	Negative	28.26	central	none	35.33	central	none	21	healed by corneal phototherapy
C4	<i>Aspergillus</i> spp.	27.48	central	none	27.48	central	none	21	healed by corneal phototherapy
C5	<i>Pseudomonas aeruginosa</i> , <i>Aspergillus</i> spp.	6.28	central	none	–	central	–	–	perforation at day 10
C6	<i>Pseudomonas aeruginosa</i> , <i>Aspergillus</i> spp.	9.42	central	none	9.42	central	none	–	perforation at day 28
C7	<i>Streptococcus beta haemolytic</i>	27.48	central	high	32.97	central	high	14	healed by corneal phototherapy
C8	Sterile	9.42	central	mild	43.96	central	mild	9	healed by corneal phototherapy

VET-CXL = veterinary corneal cross-linking developed by Vision Engineering Italy

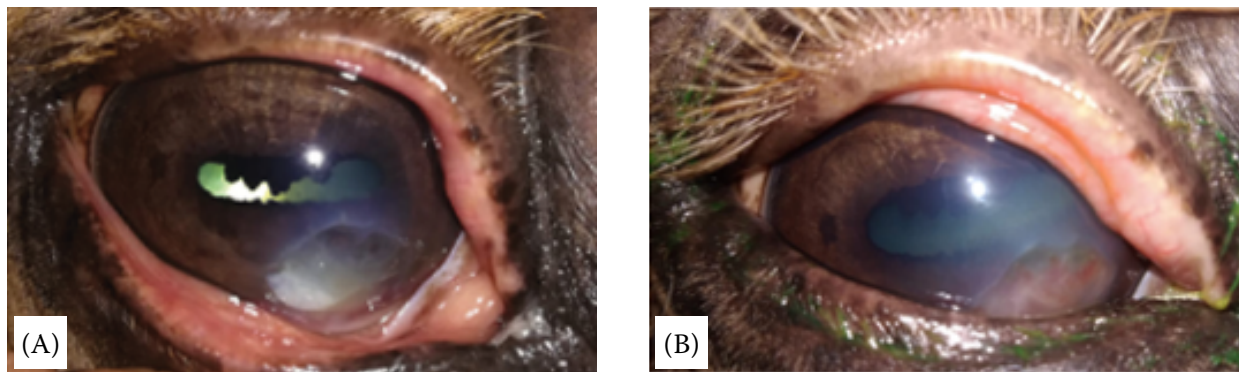


Figure 1. (A) Photograph of the cornea of a horse (A3) before the riboflavin/UV-A corneal phototherapy. The culture and sensitivity analysis revealed the presence of *Streptococcus pyogenes*. (B) At day 5, the corneal ulcer was filled with granulation tissue and the fluorescein staining was negative. The corneal tissue surrounding the lesion was clear

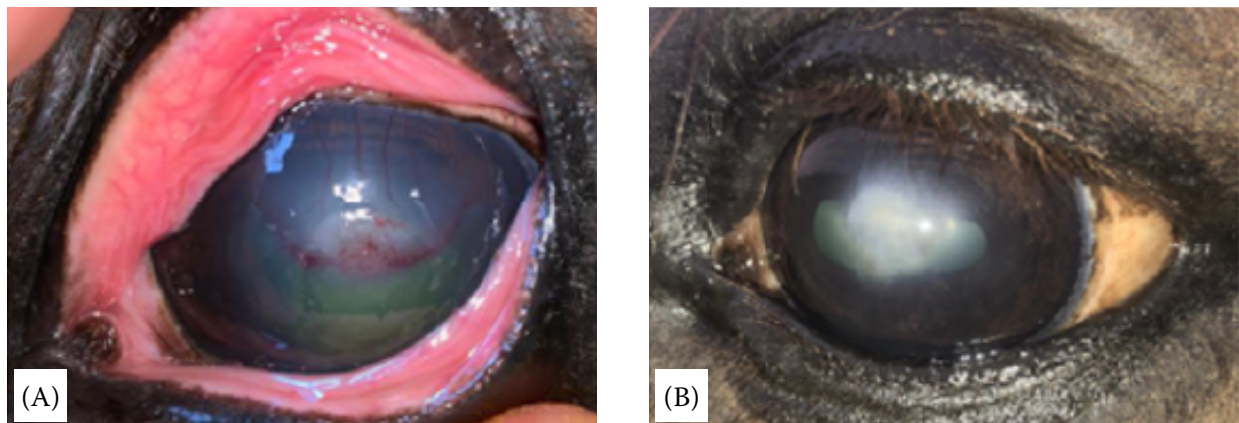


Figure 2. (A) Photograph of the cornea of a horse (A11) before the riboflavin/UV-A corneal phototherapy. The culture and sensitivity analysis revealed the presence of *Staphylococcus* spp. and *Pseudomonas* spp. (B) At day 6, the fluorescein staining was negative; the corneal opacity is visible

by  $12.7 \pm 5.5$  days after the corneal phototherapy; one horse (A7; *Aspergillus* spp.) had a corneal perforation at day 21 and underwent conjunctival flap recovery surgery.

A decrease in inflammatory signs including blepharospasm, eyelid swelling and aqueous flare in the anterior chamber was observed in almost all eyes 24 h after the corneal phototherapy. Corneal neo-angiogenesis, even in cases that were not present at enrolment, was found by 24 h after treatment and stromal loss was also stopped by 24 h after treatment in most cases. No corneal endothelial photodamage was found in any case of the study group. No recurrence was observed during the follow-up.

In the control group (Table 2 and Figures 3 and 4), six out of eight eyes were positive for a microbial culture; four eyes were positive to *Aspergillus* spp. and the other two eyes to bacteria (*Bacillus* spp. and beta haemolytic *Streptococcus*); two cases (C1 and C3) were positive both to *Aspergillus* spp. and *Alternaria*

spp. and two cases (C5 and C6) were positive both to *Pseudomonas aeruginosa* and *Aspergillus* spp.

No horse in the control group showed any clinical improvement of the corneal ulcer during the first 14 days from the enrolment; two participants had a corneal perforation (C1 at day 7 and C7 day 10) and underwent conjunctival flap recovery surgery, which permitted one to rescue the globe. The remaining six participants were switched to the corneal phototherapy at day 14 achieving complete wound healing by  $17.2 \pm 5.5$  days after treatment in five out of six cases (83%); the remaining case had a corneal perforation at day 28 (C6; *Pseudomonas aeruginosa* and *Aspergillus* spp.+). Topical ofloxacin was added to case C2 (who was positive to *Aspergillus flavus*; *Alternaria* spp., *Enterobacter*, *E. coli* and haemolytic *E. coli* before enrolment) at day 14 after the corneal phototherapy and the participant achieved complete corneal wound healing by day 21 after the corneal phototherapy (Figure 3).

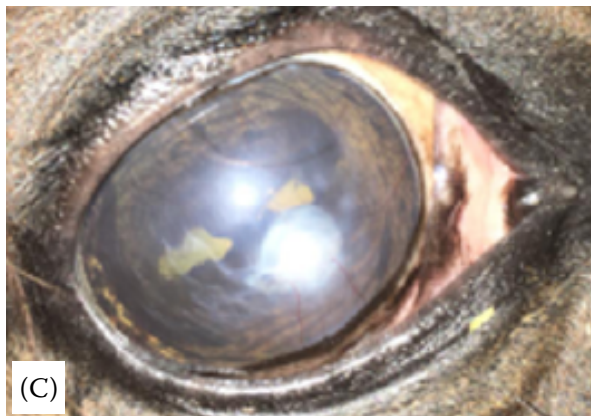
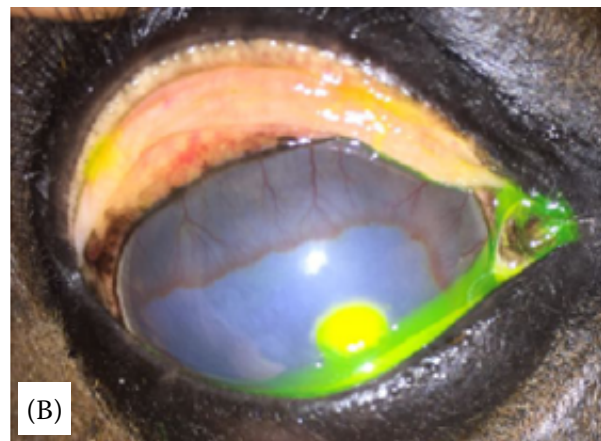
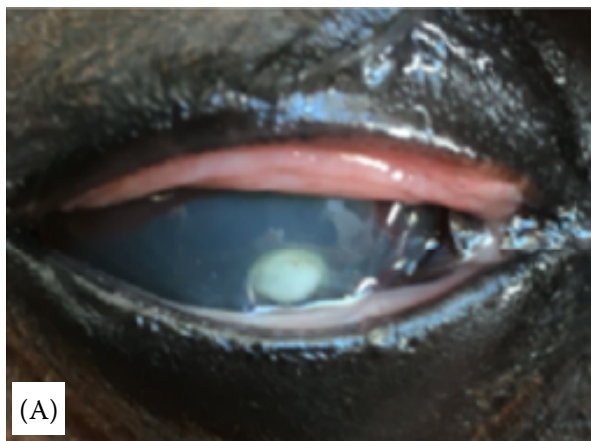

Figure 3. (A) Photograph of the cornea of a horse (C2) before starting the topical therapy. The culture and sensitivity analysis revealed the presence of *Aspergillus* spp., *Alternaria* spp., *Enterobacter* spp., and *E. coli*. (B) After 14 days of the antimicrobial topical therapy, the ulcer enlarged from 7.07 mm<sup>2</sup> to 9.42 mm<sup>2</sup>. In the same day, the horse underwent a corneal phototherapy and topical medications were discontinued. (C) 21 days after the corneal phototherapy, the defect was filled with granulation tissue and the neovascularisation had almost disappeared

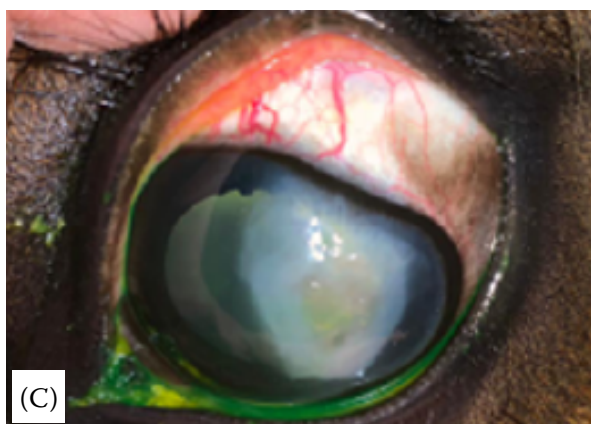
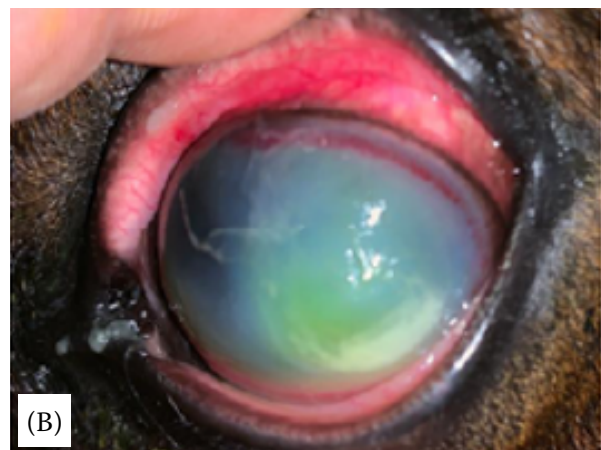
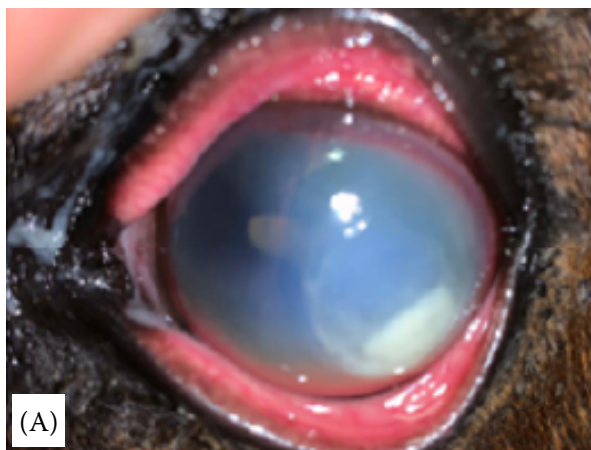


Figure 4. (A) Photograph of the cornea of a horse (C7) before starting the antimicrobial topical therapy; The culture and sensitivity analysis revealed the presence of *Streptococcus* beta-haemolytic. (B) After 14 days of the antimicrobial topical therapy, the ulcer enlarged from 27.48 mm<sup>2</sup> to 39.97 mm<sup>2</sup>. On the same day, the horse underwent a corneal phototherapy and the topical medications were discontinued. (C) 21 days after the corneal phototherapy, the defect was filled with granulation tissue and the neovascularisation disappeared

## DISCUSSION

This is the first available randomised controlled clinical trial comparing the efficacy of a stand-alone riboflavin/UV-A corneal phototherapy and topical antimicrobials for the treatment of corneal ulcers in horses.

In the present study, the riboflavin/UV-A corneal phototherapy was shown to provide a successful treatment outcome for treating corneal ulcers in horses. The horses treated by the corneal phototherapy had a clinically significant better outcome than those receiving medical treatment using a sub-palpebral lavage system. Even when performed two weeks after the enrolment in the control participants, due to the inefficacy of the topical medical therapy, the corneal phototherapy was shown to restore the corneal integrity in most cases. No corneal endothelial damage was observed during the follow-up, confirming the safety of the specific treatment protocol (30 mW/cm<sup>2</sup> for 3 min delivering a total energy dose of 5.4 J/cm<sup>2</sup>). The UV-A irradiance protocol used in this clinical study has been shown to be safe in pre-clinical settings (Perazzi et al. 2018a; Perazzi et al. 2018b; Perazzi et al. 2020). The full enrichment of the corneal stroma with riboflavin prior to the UV-A irradiation, as was performed in the present study, has been shown to be the most important factor for treatment success and safety (Lombardo and Lombardo 2019). The high safety profile of corneal cross-linking (CXL) with a 5.4 J/cm<sup>2</sup> UV-A energy dose has been widely demonstrated in human applications; the risk of direct severe complications, which occur immediately after treatment, is rare (Dhawan et al. 2011; Meek and Hayes 2013). In this study, corneal perforation occurred in four horses (one in the study group and three in the control group; in the latter group, one case had a corneal perforation 14 days after the corneal phototherapy). This complication was deemed to be related to the virulence of the *Aspergillus*, which was isolated in all these cases (Reed et al. 2013). Five participants (three in the study group and two in the control group) had a negative corneal culture and it was not possible to assess whether such findings may have influenced the treatment outcome in either group. Unfortunately, negative cultures are a common occurrence (> 30% incidence) in clinical practice (Suter et al. 2018). A cytological investigation of the corneal lesions was not performed in this study. However, a cytological examination of the ulcerative

lesion may play an important role in the evaluation of the number of bacteria or fungi in the infected tissue as well as for evaluating the degree of the corneal immune response (Brooks et al. 2016).

Previous clinical studies have assessed the effect of a riboflavin/UV-A therapy on corneal infections in horses (Hellander-Edman et al. 2013; Gallhoefer et al. 2016). Hellander-Eldam et al. (2013) performed corneal cross-linking in horses using 3.0 mW/cm<sup>2</sup> for 30 min (5.4 J/cm<sup>2</sup>) obtaining a successful outcome in seven out of nine horses and no corneal endothelial photodamage in any case. The average time of the complete corneal healing after the corneal phototherapy treatment in the present study was shorter than those of the medical treatments reported by Wada et al. (2010), Brooks et al. (2000), and Andrew et al. (1998), who measured 39-, 45- and 48-days, respectively.

Corneal cross-linking has been also used by Hellander-Edman et al. (2019) as an adjunct treatment for melting ulcers in horses in order to minimise the antibiotics, using the same protocol previously described. The authors concluded that corneal cross-linking could be potentially useful as an adjunct treatment for melting corneal ulcers and could be considered as an alternative to a prophylactic antibiotic treatment for noninfected stromal ulcers. In the present study, corneal phototherapy was investigated as a stand-alone therapy in order to assess its efficacy to treat corneal ulcerative diseases in horses. Only in one case (C2), which was positive for four microorganisms, a topical antibiotic was added after the corneal phototherapy, in order to achieve healing of the septic corneal ulcer. Previous investigators have used UV-A irradiance (3 mW/cm<sup>2</sup> for 30 min) lower than this study. Our UV-A irradiation protocol (30 mW/cm<sup>2</sup> for 3 min) has been validated in the laboratory (Lombardo et al. 2015; Lombardo et al. 2016; Perazzi et al. 2018a; Perazzi et al. 2018b; Lombardo and Lombardo 2019; Perazzi et al. 2020) showing to represent a valid therapeutic opportunity for treating corneal ulcerative lesions, while maintaining the safety of the procedure (the total energy dose remains 5.4 J/cm<sup>2</sup>).

In addition, the treatment protocol used in this clinical study has been specifically developed, as a VET-CXL (veterinary corneal cross-linking) protocol, for the application in veterinary patients (Perazzi et al. 2018a; Perazzi et al. 2018b; Perazzi et al. 2020).

Corneal phototherapy is opening a new area of therapeutics in veterinary medicine, in which chemo-physical methods and not biological molecules, are used to treat corneal infections. The procedure is based on a photo-chemical mechanism of action aimed at eradicating the infection, halting the tissue destruction and supporting the corneal structure; in addition, the mechanism of action is not selective and does not induce resistance (Pot et al. 2015). The ability of the corneal phototherapy to stop disease progression and promote corneal wound healing obtained in the horses of the present study is in agreement with previous studies conducted in dogs (Spoerl et al. 2004; Kamaev et al. 2012; Famose 2016). The hypothesis is that the procedure induces a direct cytotoxic effect by the peroxidation of the cell lipid membranes, thus directly killing the microorganisms (Kumar et al. 2004; Lombardo et al. 2015; Tabibian et al. 2015).

In addition, the procedure contributes to an increased corneal mechanical strength and resistance to proteases, as previously discussed (Sondergaard et al. 2013; Pot et al. 2015; Famose 2016; Perazzi et al. 2018a; Perazzi et al. 2018b; Kim et al. 2019).

Further clinical studies are needed in order to confirm the efficacy of the riboflavin/UV-A corneal phototherapy in treating corneal ulcers in horses and establish whether it may represent a first therapeutic option for the management of these severe eye diseases. It would be desirable to understand the exact mechanism of the infection eradication and healing processes in equine ulcerative diseases treated by corneal phototherapy.

The clinical outcomes of the present randomised controlled trial have shown that a riboflavin/UV-A corneal phototherapy may represent an effective therapeutic option for ulcerative keratitis in horses.

### Acknowledgement

The authors thank Vision Engineering Italy srl for providing the medical devices used in this work. They also thank Domenico Arigò, Roberto Caruso, Giuseppe Lupò, and Giuseppe Spinella (Consiglio Nazionale delle Ricerche, Istituto per i processi Chimico Fisici, Messina, Italy) for their technical support on the medical devices used in the present work.

### Conflict of interest

Giuseppe Lombardo and Marco Lombardo are co-founders and shareholders of Vision Engineering Italy srl.

### REFERENCES

- Andrew SE, Brooks DE, Smith PJ, Gelatt KN, Chmielewski NT, Whittaker CJ. Equine ulcerative keratomycosis: Visual outcome and ocular survival in 39 cases (1987–1996). *Equine Vet J.* 1998 Mar;30(2):109-16.
- Andrew SE, Nguyen A, Jones GL, Brooks DE. Seasonal effects on the aerobic bacterial and fungal conjunctival flora of normal thoroughbred brood mares in Florida. *Vet Ophthalmol.* 2003 Mar;6(1):45-50.
- Brooks DE, Andrew SE, Biros DJ, Denis HM, Cutler TJ, Strubbe DT, Gelatt KN. Ulcerative keratitis caused by beta-hemolytic *Streptococcus equi* in 11 horses. *Vet Ophthalmol.* 2000;3(2-3):121-5.
- Brooks DE, Matthews A, Clode AB. Diseases of the cornea. In: Gilger BC, editor. *Equine ophthalmology.* New York, NY: John Wiley & Sons; 2016. p. 252-368.
- Cabiscol E, Tamarit J, Ros J. Oxidative stress in bacteria and protein damage by reactive oxygen species. *Int Microbiol.* 2000 Mar;3(1):3-8.
- Dennis DA, Pinard CL, Kenney DG, Salcedo RJ, Trout DR. Normograde nasolacrimal placement of an ocular-lavage system for treatment of equine eye diseases. *Can Vet J.* 2019 Jul;60(7):744-8.
- Dhawan S, Rao K, Natrajan S. Complications of corneal collagen cross-linking. *J Ophthalmol.* 2011;2011:869015.
- Famose F. Evaluation of accelerated collagen cross-linking for the treatment of melting keratitis in ten cats. *Vet Ophthalmol.* 2015 Mar;18(2):95-104.
- Famose F. Evaluation of accelerated corneal collagen cross-linking for the treatment of bullous keratopathy in eight dogs (10 eyes). *Vet Ophthalmol.* 2016 May;19(3):250-5.
- Galan AE, Martin-Suarez M, Gallardo JM, Molleda JM. Clinical findings and progression of 10 cases of equine ulcerative keratomycosis (2004–2007). *Equine Vet Edu.* 2009;21(5):236-42.
- Gallhoefer NS, Spiess BM, Guscetti F, Hilbe M, Hartnack S, Hafezi F, Pot SA. Penetration depth of corneal cross-linking with riboflavin and UV-A (CXL) in horses and rabbits. *Vet Ophthalmol.* 2016 Jul;19(4):275-84.
- Hayes S, Kamma-Lorger CS, Boote C, Young RD, Quantock AJ, Rost A, Khatib Y, Harris J, Yagi N, Terrill N, Meek KM. The effect of riboflavin/UVA collagen cross-linking therapy on the structure and hydrodynamic behaviour



<https://doi.org/10.17221/60/2020-VETMED>

- of the ungulate and rabbit corneal stroma. *PLoS One*. 2013;8(1):e52860.
- Hellander-Edman A, Makdoui K, Mortensen J, Ekesten B. Corneal cross-linking in 9 horses with ulcerative keratitis. *BMC Vet Res*. 2013 Jun 26;9(1):1-10.
- Hellander-Edman A, Strom L, Ekesten B. Corneal cross-linking (CXL) – A clinical study to evaluate CXL as a treatment in comparison with medical treatment for ulcerative keratitis in horses. *Vet Ophthalmol*. 2019 Jul;22(4):552-62.
- Kamaev P, Friedman MD, Sherr E, Muller D. Photochemical kinetics of corneal cross-linking with riboflavin. *Invest Ophthalmol Vis Sci*. 2012 Apr 30;53(4):2360-7.
- Kim J, Ji DB, Takiyama N, Bae J, Kim MS. Corneal collagen cross-linking following superficial keratectomy as treatment for corneal endothelial cell dystrophy in dogs: Preliminary clinical study. *Vet Ophthalmol*. 2019 Jul;22(4):440-7.
- Kumar V, Lockerbie O, Keil SD, Ruane PH, Platz MS, Martin CB, Ravanat JL, Cadet J, Goodrich RP. Riboflavin and UV-light based pathogen reduction: extent and consequence of DNA damage at the molecular level. *Photochem Photobiol*. 2004 Jul-Aug;80(1):15-21.
- Lombardo M, Pucci G, Barberi R, Lombardo G. Interaction of ultraviolet light with the cornea: Clinical implications for corneal crosslinking. *J Cataract Refract Surg*. 2015 Feb;41(2):446-59.
- Lombardo G, Micali NL, Villari V, Serrao S, Lombardo M. All-optical method to assess stromal concentration of riboflavin in conventional and accelerated UV-A irradiation of the human cornea. *Invest Ophthalmol Vis Sci*. 2016 Feb;57(2):476-83.
- Lombardo M, Lombardo G. Noninvasive real-time assessment of riboflavin consumption in standard and accelerated corneal crosslinking. *J Cataract Refract Surg*. 2019 Jan;45(1):80-6.
- Meek KM, Hayes S. Corneal cross-linking – A review. *Ophthalmic Physiol Opt*. 2013;33(2): 78-93.
- Perazzi A, Gomiero C, Iacopetti I, Corain L, Grisan E, Lombardo M, Lombardo G, Salvalaio G, Patruno M, Martinello T, Peruffo A. Assessment of uv-a/riboflavin corneal cross-linking efficacy for the treatment of experimentally induced corneal lesions in an ex vivo animal model. *LXXII SISVET Conference, Italy; 2018a*. 167 p.
- Perazzi A, Peruffo A, Gomiero C, Contin R, Corain L, Grisan E, Lombardo M, Lombardo G, Salvalaio G, Patruno M, Iacopetti I, Martinello T. Assessment of uv-a/riboflavin corneal cross-linking efficacy for the treatment of experimentally induced. *International CXL experts meeting, Switzerland; 2018b*. p 2014-5.
- Perazzi A, Gomiero C, Corain L, Iacopetti I, Grisan E, Lombardo M, Lombardo G, Salvalaio G, Contin R, Patruno M, Martinello T, Peruffo A. An assay system to evaluate riboflavin/UV-A corneal phototherapy efficacy in a porcine corneal organ culture model. *Animals (Basel)*. 2020 Apr 23;10(4):730.
- Pot SA, Gallhofer NS, Matheis FL, Voelter-Ratson K, Hafezi F, Spiess BM. Corneal collagen cross-linking as treatment for infectious and noninfectious corneal melting in cats and dogs: Results of a prospective, non-randomized, controlled trial. *Vet Ophthalmol*. 2014 Jul;17(4):250-60.
- Pot SA, Gallhofer NS, Walser-Reinhardt L, Hafezi F, Spiess BM. Treatment of bullous keratopathy with corneal collagen cross-linking in two dogs. *Vet Ophthalmol*. 2015 Mar;18(2):168-73.
- Reed Z, Thomasy SM, Good KL, Maggs DJ, Magdesian KG, Pusterla N, Hollingsworth SR. Equine keratomycoses in California from 1987 to 2010 (47 cases). *Equine Vet J*. 2013 May;45(3):361-6.
- Sauer P, Andrew SE, Lassaline M, Gelatt KN, Denis HM. Changes in antibiotic resistance in equine bacterial ulcerative keratitis (1991–2000): 65 horses. *Vet Ophthalmol*. 2003 Dec;6(4):309-13.
- Sondergaard AP, Ivarsen A, Hjortdal J. Reduction of stromal swelling pressure after UVA-riboflavin cross-linking. *Invest Ophthalmol Vis Sci*. 2013 Mar 5;54(3):1625-34.
- Spoerl E, Mrochen M, Sliney D, Trokel S, Seiler T. Safety of UVA-riboflavin cross-linking of the cornea. *Cornea*. 2007 May;26(4):385-9.
- Spoerl E, Wollensak G, Seiler T. Increased resistance of crosslinked cornea against enzymatic digestion. *Curr Eye Res*. 2004 Jul;29(1):35-40.
- Suter A, Voelter K, Hartnack S, Spiess BM, Pot SA. Septic keratitis in dogs, cats, and horses in Switzerland: Associated bacteria and antibiotic susceptibility. *Vet Ophthalmol*. 2018 Jan;21(1):66-75.
- Tabibian D, Richoz O, Hafezi F. PACK-CXL: Corneal cross-linking for treatment of infectious keratitis. *J Ophthalmic Vis Res*. 2015 Jan-Mar;10(1):77-80.
- Voelter-Ratson K, Monod M, Unger L, Spiess BM, Pot SA. Evaluation of the conjunctival fungal flora and its susceptibility to antifungal agents in healthy horses in Switzerland. *Vet Ophthalmol*. 2014 Jul;17(Suppl 1):31-6.
- Wada S, Hobo S, Niwa H. Ulcerative keratitis in thoroughbred racehorses in Japan from 1997 to 2008. *Vet Ophthalmol*. 2010 Mar;13(2):99-105.

Received: March 14, 2020

Accepted: March 3, 2021