

Cook Zenith Alpha Endograft: A Protocol to Minimise Limb Graft Occlusion

Rodolfo Pini ^{a,b,*}, Claudio Bianchini Massoni ^c, Gianluca Faggioli ^{a,b}, Stefania Caputo ^b, Gemmi Sufali ^b, Stefano Ancetti ^a, Andrea Vacirca ^{a,b}, Enrico Gallitto ^{a,b}, Paolo Perini ^c, Antonio Freyrie ^c, Mauro Gargiulo ^{a,b}

^a Vascular Surgery Unit, IRCCS University Hospital Policlinico S. Orsola, Bologna, Italy

^b Vascular Surgery, University of Bologna, DIMEC, Bologna, Italy

^c Vascular Surgery Unit, Azienda Ospedaliero-Universitaria di Parma, Università di Parma, Parma, Italy

WHAT THIS PAPER ADDS

In the literature, many experiences with different rates of limb graft occlusion (LGO) in endovascular aortic aneurysm repair (EVAR) are reported. Some authors have identified the Cook Zenith Alpha endograft as an independent risk factor for LGO. The present study analysed the rate of LGO according to a standard protocol for minimising limb complications. With a mean follow up of 44 months, four LGOs occurred in 233 Zenith Alpha grafts (1.7%) resulting in a 97% freedom from LGO at five years, with no differences compared with other types of endograft. Two independent risk factors associated with LGO were identified with Cook Zenith Alpha endograft: the external iliac artery distal landing zone and the use of a large main body (ZIMB 32 – 36).

Objective: Numerous articles have reported an increased incidence of limb graft occlusion (LGO) with the Cook Zenith Alpha endograft compared with other endografts in endovascular aortic aneurysm repair (EVAR). The present study aimed to assess the rate of LGO after EVAR in particular with the Cook Zenith Alpha device when adhering to a standardised protocol designed to prevent limb related complications.

Methods: This was a non-sponsored retrospective study performed in two university vascular surgery centres employing the same protocol for limb complication prevention during EVAR from 2016 to 2019. The protocol encompassed: (1) angioplasty of any common or external iliac artery with > 50% stenosis before endograft navigation; (2) proximal sealing zone of limbs at the same level of the flow divider with minimum overlap, which is more restrictive than the Cook Zenith Alpha instructions for use; (3) semi-compliant kissing ballooning of limbs; (4) limb stenting for any residual tortuosity, kinking, or stenosis; and (5) adjunctive common and external iliac stenting for residual stenosis or dissection after EVAR. Patients enrolled in this study were treated with standard aortobi-iliac EVAR. Follow up was performed by clinical visit and duplex ultrasonography at discharge, six months, and yearly thereafter. The primary endpoint was to evaluate the LGO rate with different EVAR devices (Cook Zenith Alpha, Gore C3, and Medtronic Endurant) and to determine potential risk factors for LGO associated with the Zenith Alpha.

Results: In the study period, 547 EVARs were considered: 233 (42.6%) Cook Zenith Alpha, 196 (35.8%) Gore Excluder, and 118 (21.6%) Medtronic Endurant. The mean follow up was 44 ± 23 months, and the five year freedom from LGO was $97 \pm 3\%$, without differences between groups ($97 \pm 2\%$, $95 \pm 3\%$, and 100% with Cook Zenith Alpha, Medtronic Endurant, and Gore Excluder, respectively; $p = .080$). In the Zenith Alpha group, intra-operative adjunctive iliac artery angioplasty, iliac artery stenting, or iliac limb stenting was performed in 8%, 3.4%, and 9.7% of cases, respectively. Analysis of potential risk factors for LGO identified external iliac artery distal landing and large main bodies (ZIMB 32 – 36) to be independently associated with LGO during follow up (hazard ratio [HR] 18, 95% confidence interval [CI] 3 – 130, $p = .004$; and HR 12, 95% CI 1.2 – 130, $p = .030$, respectively).

Conclusion: The present experience with a protocol for limb complication prevention allows achievement of a low rate of LGO at five years with Zenith Alpha endografts similar to other endografts. Specific risk factors for the Cook Zenith Alpha endograft are external iliac artery distal landing and the use of a large main body (ZIMB 32 – 36).

Keywords: Cook Alpha, EVAR, Follow up, Iliac limb occlusion, Prevention

Article history: Received 8 December 2023, Accepted 19 June 2024, Available online 25 June 2024

© 2024 The Author(s). Published by Elsevier B.V. on behalf of European Society for Vascular Surgery. This is an open access article under the CC BY license (<http://creativecommons.org/licenses/by/4.0/>).

* Corresponding author. Vascular Surgery Unit, IRCCS University Hospital Policlinico S. Orsola, Via Massarenti 9, Bologna 40138, Italy.

E-mail address: rudyypini@gmail.com (Rodolfo Pini).

1078-5884/© 2024 The Author(s). Published by Elsevier B.V. on behalf of European Society for Vascular Surgery. This is an open access article under the CC BY license (<http://creativecommons.org/licenses/by/4.0/>).

<https://doi.org/10.1016/j.ejvs.2024.06.036>

INTRODUCTION

Endovascular aortic aneurysm repair (EVAR) is in widespread use for the treatment of abdominal aortic aneurysms (AAAs), with ongoing advances in endograft design aimed at reducing the delivery system diameter and enhancing the configuration of limbs at flow divider level. Nevertheless, the flip side of these modifications lies in the potential adverse impact on long term fatigue and overall patency of the system. In addition to the risk of high flow endoleaks, one of the most prevalent complications encountered during follow up after EVAR is limb graft occlusion (LGO). Although its overall incidence is typically low, often around 5% in various series, it necessitates prompt re-intervention in most instances.^{1,2}

Certain anatomical risk factors, such as peripheral arterial disease or distal landing in the external iliac artery (EIA), have been identified as independent contributors to LGO.^{2,3} However, a recent study by Bogdanovic *et al.* introduced the use of a Zenith Alpha endograft as an additional independent risk factor for LGO,² rated up to 12%. Their study analysed data from five vascular surgery centres in Sweden spanning the years 2012 – 2018. Notably, in 2020 the manufacturer of the Zenith Alpha endograft (Cook Medical) revised the instructions for use (IFU) for the delivery of Zenith Alpha endograft limbs, prompted by an urgent field safety notice (Fig. 1).⁴

Previously, this group had published findings from EVAR procedures conducted in adherence to a comprehensive protocol aimed at mitigating iliac limb related complications, yielding a notably low LGO incidence during follow up.⁵ Nevertheless, this series included a heterogeneous mix of various endografts and distinct types of Cook iliac limbs. Notably, the protocol diverges from the Zenith Alpha IFU by

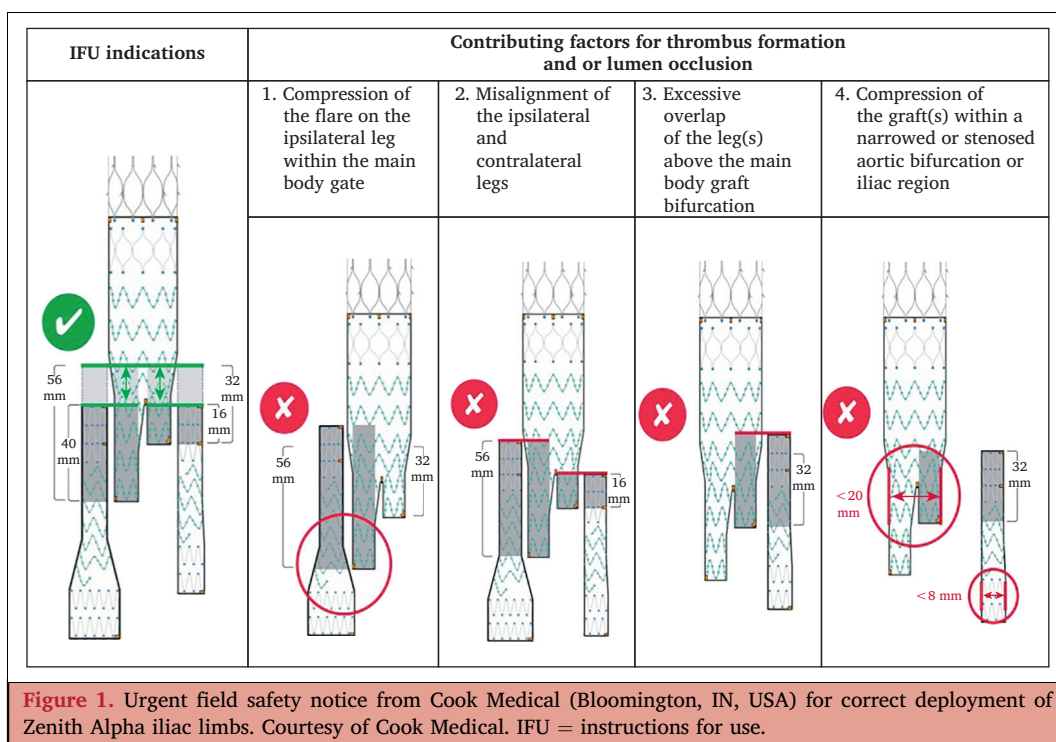
advocating the deployment of both iliac limbs at the same level of the endograft main body flow divider, deliberately circumventing deployment above the specified minimum limb overlap. This particular approach has been an integral component of the protocol since the inception of this experience with Zenith Alpha.

Hence, the primary endpoint of this study was to assess the rate of LGO specifically within the Zenith Alpha devices compared with other endografts, while employing a standardised protocol designed to prevent limb related complications. Additionally, the study aimed to identify potential risk factors associated with LGO within the Zenith Alpha—Zenith Iliac Limb System (ZILS).

MATERIALS AND METHODS

Study design and inclusion criteria

This was a non-sponsored retrospective multicentre study (Vascular Surgery Unit, IRCCS University Hospital, Policlinico S. Orsola, Bologna, Italy; and Vascular Surgery Unit Azienda Ospedaliero-Universitaria di Parma, Parma, Italy). The study focused on patients who were treated for a AAA in accordance with the European Society for Vascular Surgery (ESVS) guidelines. Three types of endograft (main body and dedicated limb extensions) were used: Zenith Alpha (Cook Medical, Bloomington, IN, USA), Excluder (W.L. Gore & Associates Inc, Flagstaff, AZ, USA), and Endurant (Medtronic Inc., Minneapolis, MN, USA).⁶ The study exclusively included standard EVAR cases, aiming to ensure treatment homogeneity and to enable analysis of the impact of different endografts on the occurrence of LGO. Cases involving non-standard techniques such as aorto-uni-iliac and femorofemoral bypass, or those employing iliac branch devices,



were excluded. Patients who experienced hypogastric artery occlusion and those with iliac limb landing in both the common iliac artery (CIA) and EIA were included in the study.

Patient enrolment started in 2016, contemporaneously with the beginning of the experience of the participating centres with Zenith Alpha endografts, and continued until December 2019. All centres adhered to an identical protocol for preventing complications related to iliac limbs. All patients provided written informed consent for their data inclusion in the database. The study was performed in accordance with the rules of the ethics review board of the various institutions.

Patient characteristics

Clinical and anatomical characteristics were entered into a database prospectively for each patient and were analysed retrospectively: sex, hypertension (systolic blood pressure > 140 mmHg and or diastolic > 90 mmHg, or specific therapy), dyslipidaemia (total cholesterol > 200 mg/dL or low density lipoprotein > 120 mg/dL, or specific therapy), diabetes mellitus (treated with oral hypoglycaemic drugs or insulin), current smoking, coronary artery disease, chronic obstructive pulmonary disease, chronic renal failure (estimated glomerular filtration rate < 60 mL/min/1.73m²), chronic haemodialysis treatment, chronic limb threatening ischaemia (CLTI), atrial fibrillation, American Society of Anesthesiologists (ASA) risk score, dual antiplatelet therapy, and oral anticoagulant therapy. For every patient, a thin slice (1 mm) computed tomography angiogram (CTA) was used to define the characteristics of the AAA maximum diameter and the aortic neck morphology. Aortic and iliac anatomy was evaluated using dedicated software for vessel analysis (3mensio; Vascular Imaging, Bilthoven, The

Netherlands). Biplanar and 3D analysis of CTAs were used to define the pre-operative characteristics. Centre lumen line evaluation was used to measure the diameter of the distal aorta and the CIA. The presence and percentage of parietal calcification (severe > 75% and moderate 50 – 75% iliac calcification) and angulation and tortuosity of the CIA (severe tortuosity with the iliac angle, i.e., the most acute angle in the pathway between the common femoral artery and the aortic bifurcation, < 90°) were all identified using the classification of Chaikof *et al.*⁷ Similar characteristics were detailed for the EIA. Large main bodies (≥ 32 mm) and flared limbs (≥ 16 mm) were considered for the analysis.

Protocol for limb complication prevention

Each patient was treated according to the steps of the following protocol for CIA and EIA management, regardless of the type of endograft used (Fig. 2).⁵ (1) For > 50% CIA or EIA morphological stenosis on the pre-operative CTA, a semi-compliant balloon angioplasty was performed before endograft navigation. (2) Iliac limbs were deployed proximally at the same level of the main body flow divider, even if the endograft IFU allowed a more proximal deployment. Implantation and deployment of the aortobi-iliac endograft was performed over extra stiff guidewires (Lunderquist Extra-Stiff Wire Guide; Cook Aortic Interventions, Bloomington, IN, USA). (3) After moulding ballooning of the proximal fixation of the endograft, a kissing semi-compliant ballooning was performed at the level of the docking zone between the iliac limbs and the main body of the endograft. Both iliac limbs were ballooned along their entire length and, for a flared iliac limb, the distal segment of the limb was dilated with a compliant balloon. (4) For residual stenosis (> 50%) or kinking of the iliac limb, a self expandable bare metal stent was deployed. (5) Before removing the

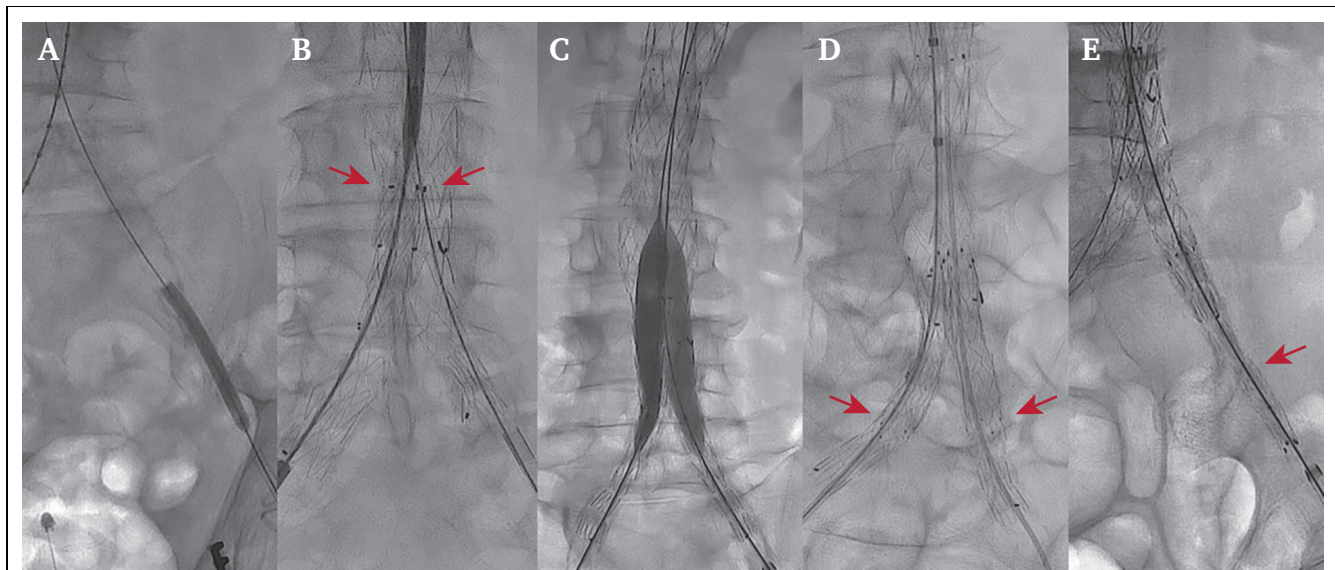


Figure 2. Technical aspects of the protocol for iliac limb complication prevention. (A) Iliac limb ballooning pre-endograft iliac navigation. (B) Deployment of both iliac limbs at the same level of the flow divider (arrows). (C) Kissing ballooning of iliac limbs with semi-compliant balloons. (D) Stenting of iliac limbs (arrows). (E) Stenting of external iliac artery (arrow).

devices from the femoral arteries, three projection angiography⁸ of the EIAs was performed with a floppy guide-wire, and for dissections or residual stenosis, a self expandable stent was implanted.

Post-operative medical therapy

Following the EVAR procedure, all patients typically received ongoing treatment with single antiplatelet therapy and prophylactic low molecular weight heparin (LMWH) until they regained their regular physical activity. Those who underwent adjunctive stenting of the iliac arteries or iliac limbs were subjected to dual antiplatelet therapy for a duration of three months, after which a single antiplatelet regimen was maintained indefinitely. For individuals who were taking oral anticoagulants prior to the surgery, the EVAR procedure was performed after bridging with LMWH, with the resumption of oral anticoagulant therapy after discharge. In these specific cases, patients were treated with a single antiplatelet agent.

Imaging follow up

Duplex ultrasound examination was always performed before discharge. For severe obesity or any other condition hampering duplex ultrasound evaluation, CTA was performed before discharge.

Follow up included duplex ultrasonography at six and 12 months, and yearly thereafter, with an accurate evaluation of possible endoleaks, sac diameter, and shrinkage (defined as a decrease > 5 mm between pre-operative aneurysm maximum diameter and that at the latest follow up). Iliac limbs and EIAs were evaluated to identify thrombosis or $> 50\%$ stenosis. Ankle brachial index was assessed for claudication or CLTI cases. If iliac limb, other endograft complications, or any other condition hampering duplex ultrasound evaluation were suspected a CTA was performed yearly.

Outcomes

The primary outcome of this study was to assess the occurrence of LGO, which was defined as complete occlusion of the lumen across the entire length or a segment of the limb, or a stenosis that required invasive treatment due to thrombus formation ($> 50\%$ reduction in lumen diameter) during the follow up period. This assessment included the various types of endografts employed throughout the analysed timeframe. Possible risk factors associated with LGO with the Zenith Alpha were also investigated.

Statistical analysis

Continuous variables were expressed as mean \pm standard deviation, and categorical variables as number (percentage). Comparison between categorical variables was performed using the χ^2 test and analysis of variance for continuous variables. Kaplan–Meier analysis with log rank test was used to estimate the five year LGO rate. Cox linear regression was used for univariable analysis, with factors

having statistical significance ($p < .050$) in the univariable analysis entered into a Cox multivariable model reporting hazard ratio (HR) and 95% confidence interval (CI). A p value of $< .050$ (two tailed) was considered statistically significant. Statistical tests were performed using IBM SPSS Statistics for Mac OS Version 21.0 (IBM Corp., Armonk, NY, USA).

RESULTS

Overall limb graft occlusion

In the period under examination, of a total of 669 AAA treatments, 122 (18.2%) were open repairs for infrarenal aneurysms and 547 (81.8%) were standard EVARs, which were included in the study. Among these, there were 233 (42.6%) Cook Zenith Alpha, 196 (35.8%) Gore Excluder, and 118 (21.6%) Medtronic Endurant cases.

Adjunctive iliac procedures (limb stenting, iliac artery stenting, and angioplasty) were performed in 40 (9.3%) for Cook Alpha, 24 (7.2%) for Gore Excluder, and 12 (10.5%) for Medtronic Endurant ($p = .320$).

The mean follow up was 44 ± 23 months. During this period there were eight LGOs (1.2%): four (1.7%) with Zenith Alpha and four (3.4%) with Medtronic Endurant; there were none in the Gore Excluder group. Analysing LGO for limbs (excluding iliac branches devices), the LGO rate was 0.9% (4/444) in Zenith Alpha limbs, 1.7% (4/236) in Medtronic Endurant limbs, and 0% (0/352) in Gore Excluder.

The five year freedom from LGO was similar between groups: $97 \pm 2\%$ for Zenith Alpha, $95 \pm 3\%$ for Medtronic Endurant, and 100% for Gore Excluder; $p = .080$ (Fig. 3).

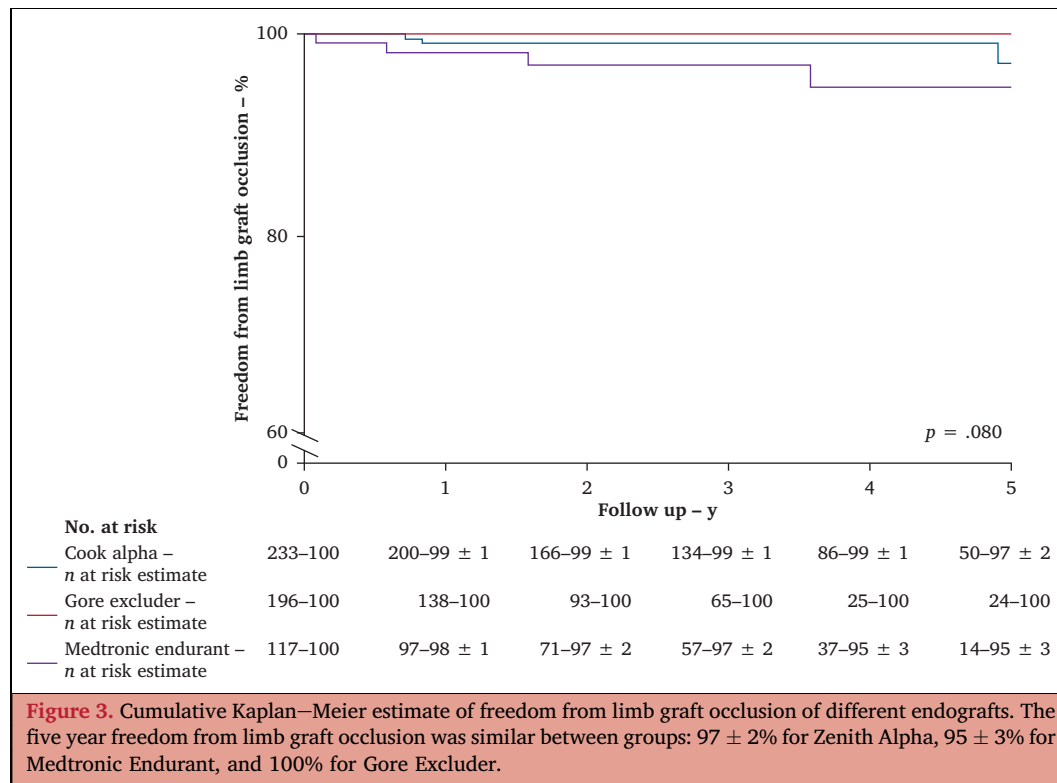
Analysis of Zenith Alpha endograft outcome

Patient clinical characteristics and anatomical features are reported in Tables 1 and 2. Specifically, the mean age was 77 ± 7 years and 10% of patients were female. Severe calcification occurred in 12% of CIAs and 2.7% of EIAs ($> 75\%$). EIA limb landing was performed in 25 (5.7%) limbs and in all cases was planned pre-operatively.

The overall EVAR technical success was 98%, with three type Ia endoleaks and two type Ib endoleaks successfully treated with secondary interventions.

As reported in Table 3, pre-EVAR angioplasty of the iliac axis was necessary in 7.5% of limbs, endograft limb stenting for kinking or stenosis was performed in 3.1% of limbs, and iliac artery stenting below the iliac limb landing zone was performed in 9.0% of limbs. No peri-operative (30 day) death or LGO occurred in that period.

The mean follow up was 44 ± 30 months, with a five year survival of $58 \pm 4\%$. Four patients experienced a late LGO, all in a single endograft limb. One case occurred nine months after EVAR as a consequence of CLTI progression in the EIA (at the end of procedure no stenosis, kinking, or dissection was identified and no adjunctive procedures were necessary) and was left untreated due to negligible symptoms. In the second case, the LGO occurred 10 months after EVAR in an active smoker patient with haematological disease (lymphoma treated with chemotherapy) and



without iliac limb defects at the end of EVAR. The remaining two cases of LGO occurred in iliac limbs with an EIA distal landing zone 59 months and 69 months after EVAR implantation, respectively. Both patients were treated with a femorofemoral bypass. The overall LGO for patient was 1.7% and, by Kaplan–Meier analysis, the estimated five year freedom from LGO was 97 ± 2%.

Analysis of possible risk factors associated with LGO ([Supplementary Material](#)) identified that EIA landing was significantly associated with LGO (HR 17, 95% CI 1.54 – 188, $p = .020$) with a lower estimated five year freedom from LGO of 75 ± 9% compared with landing in the CIA of 99 ± 0.4% ([Fig. 4](#)). The Kaplan–Meier curve shows that < 10 patients were censored after 3 years of follow up in

Table 1. Demographic characteristics of patients ($n = 547$) treated with different endografts for endovascular aortic aneurysm repair.

Characteristic	Zenith Alpha ($n = 233$)	Gore Excluder ($n = 196$)	Medtronic Endurant ($n = 118$)	<i>p</i> value
Age – y	77.3 ± 7	74 ± 6	77.2 ± 7	.010
Male	211 (90.4)	176 (89.9)	111 (94.4)	.41
Hypertension	207 (88.7)	170 (86.9)	95 (80.7)	.10
Dyslipidaemia	150 (64.8)	132 (67.3)	73 (61.5)	.60
Diabetes mellitus	51 (21.7)	23 (11.5)	18 (15.3)	.020
Smoking	122 (52.2)	118 (60.3)	65 (55.4)	.26
COPD	89 (38.3)	74 (37.6)	36 (30.7)	.32
Coronary artery disease	80 (34.3)	61 (31.1)	36 (30.7)	.69
Atrial fibrillation	37 (16.1)	22 (11.1)	20 (17.3)	.27
Occlusive PAD	32 (13.9)	8 (4.3)	7 (5.9)	.001
Chronic kidney disease	80 (34.3)	82 (42.0)	52 (44.2)	.13
ASA score				.030
II	16 (6.9)	20 (10.2)	18 (15.3)	
III	152 (65.1)	123 (62.8)	81 (68.6)	
IV	65 (27.9)	53 (27.0)	19 (16.1)	
Single antiplatelet therapy*	205 (87.8)	177 (90.1)	104 (88.5)	.72
Double antiplatelet therapy*	15 (6.6)	15 (7.9)	4 (3.8)	.31
Oral anticoagulant therapy*	41 (17.8)	19 (9.5)	23 (19.2)	.030

Data are presented as mean ± standard deviation or n (%). COPD = chronic obstructive pulmonary disease; PAD = peripheral arterial disease; ASA = American Society of Anesthesiologists.

* Medical therapy after endovascular aortic aneurysm repair.

Table 2. Anatomical features of patients (n = 547) treated with different endografts for endovascular aortic aneurysm repair.

Feature	Zenith Alpha (n = 233)	Gore Excluder (n = 196)	Medtronic Endurant (n = 118)	p value
Aneurysm diameter – mm	57.0 ± 15	56.9 ± 12	57.9 ± 13	.55
Infrarenal neck diameter – mm	22.9 ± 6	23.4 ± 5	23.7 ± 5	.32
Infrarenal neck length – mm	23 ± 4	27 ± 5	26.6 ± 4	.001
Aortic bifurcation diameter – mm	28.4 ± 9	27.2 ± 8	27.1 ± 9	.45
Aortic bifurcation <20 mm	35 (15.0)	22 (11.1)	20 (17.3)	.27
Common iliac artery diameter – mm	14.4 ± 5.8	17.5 ± 7	14.2 ± 6	.12
External iliac artery diameter – mm	8.9 ± 2	9.4 ± 3	8.8 ± 2	.15
<i>Common iliac artery calcification</i>				<.001
Moderate, 50–75%	82 (35.4)	22 (11.4)	12 (10.5)	
Severe, >75%	28 (11.9)	8 (4.1)	4 (3.3)	
<i>External iliac artery calcification</i>				<.001
Moderate, 50–75%	17 (7.5)	6 (3)	2 (2)	
Severe, >75%	6 (2.7)	20 (1)	0 (0)	
Iliac axis angle – °	22 ± 11	23 ± 18	22 ± 12	.54
Pre-operative hypogastric artery occlusion	20 (4.8)	7 (3.5)	5 (4.1)	.060
Large main body, ZIMB 32–36	41 (17.6)	39 (20.1)	22 (18.6)	.83
Flared limb, ≥16 mm	101 (43.5)	100 (51.0)	61 (51.7)	.18

Data are presented as mean ± standard or n (%).

the EIA landing group. At the three year follow up, the freedom from LGO was 100% vs. 99 ± 0.4%, respectively.

The use of a large main body endograft (ZIMB 32 – 36) was associated with higher rate of LGO than a smaller main body (HR 11.8, 95% CI 1.22 – 144, $p = .030$; Kaplan–Meier five year estimation of freedom from LGO, 99 ± 0.3% vs. 94 ± 5%, $p = .001$, respectively) (Fig. 4). Cox regression analysis confirmed an independent association of EIA landing and large main body with LGO during the follow up (HR 18, 95%, CI 3 – 130, $p = .004$; and HR 12, 95% CI 1.2 – 130, $p = .030$, respectively).

DISCUSSION

The present study reports a large multicentre experience with the Zenith Alpha endograft with a distinct protocol designed to prevent limb related complications, which notably differs from the official IFU. This protocol has

been published previously, focusing on a single centre experience and revealing a low incidence of LGO (1%). The present study aimed to evaluate this particular protocol with Zenith Alpha devices, since there are some experiences reporting a high rate of LGO, up to 12%, with this specific endograft during follow up. Patients were selected from 2016 – 2019 in two university centres in order to reach a sufficiently long follow up, with the protocol for limb complication prevention already in use. The prevention protocol comes from long experience with adjunctive procedures to avoid iliac limb complications,⁵ including kissing ballooning of iliac limbs, multiplanar angiography to identify stenosis,⁸ iliac stenting in the aortic bifurcation,⁹ evaluation of the landing zone of flared limbs,¹⁰ and management of severe atherosclerotic disease of the iliac arteries.¹¹

Regarding the deployment of iliac limbs, it is important to note that the protocol diverges from the recent IFU for Zenith Alpha limbs.⁴ Specifically, this distinctive approach involves the precise deployment of both limbs at the same level as the main body's flow divider (Fig. 5). In contrast, the Zenith Alpha IFU permits the deployment of limbs above the flow divider. However, such deployment is not appropriate owing to the potential mismatch between the diameters of the iliac limbs and the main body. It is believed that this mismatch could result in turbulent flow patterns and an increased risk of thrombosis.

The current analysis reaffirmed favourable outcomes across all endograft types, demonstrating a high five-year rate of freedom from LGO of 97%. Patients treated with different type of endograft presented different pre-operative features; for example, Cook Zenith Alpha patients were more affected by diabetes and occlusive peripheral arterial disease and had a higher rate of iliac artery calcifications and shorter neck length.

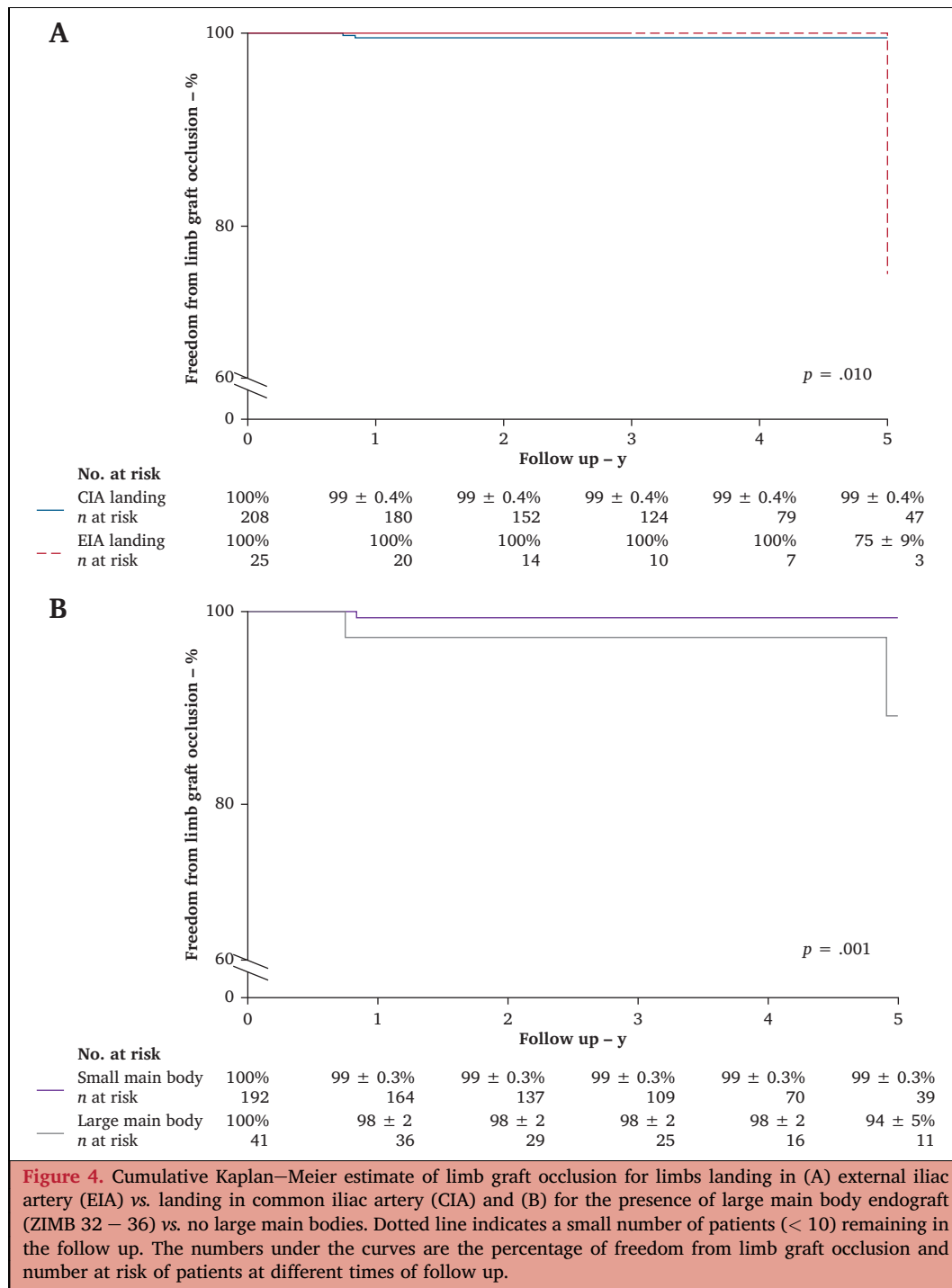
This selection bias is due to the common approach of choosing the Cook Zenith Alpha endograft for patients with

Table 3. Peri-operative adjunctive procedure and outcomes with Cook Zenith Alpha endograft.

Variable	n (%)
Iliac axis angioplasty*	33 (7.5)
Iliac leg stenting*	14 (3.1)
External iliac artery stenting*	40 (9.0)
External iliac artery landing*	25 (5.7)
Femoral artery endarterectomy*	4 (1.7)
Percutaneous EVAR†	57 (24.3)
Procedure time – min†	143.3 ± 72.1
Xray time – min†	27.7 ± 18.8
Iodinate contrast used – mL†	80.7 ± 40.5
Technical success†	228 (98)
30 day type Ia/b endoleak‡	5 (2.1)
30 day iliac limb occlusion*	0 (0)

* Data for Zenith Alpha limbs (total 444, excluding iliac branches devices).

† Data for Zenith Alpha endografts (total 233). Data are presented as n (%) or mean ± standard deviation. EVAR = endovascular aortic aneurysm repair.



hostile (calcified and small arteries) iliac arteries and a short neck.

Following this protocol for limb complication prevention in Zenith Alpha, four cases of late LGO were identified, leading to a five year freedom from LGO of 97%. This is a low rate of LGO but in line with data previously reported on different types of endograft.⁵

Bogdanovic *et al.* have recently documented an increased LGO rate of 12.4% in patients treated with Alpha limbs.² Likewise, Broda *et al.* conducted a focused analysis of the Zenith Alpha experience, affirming an LGO rate of 11%.¹²

The disparities in LGO rates between these studies and the current case series underscore the rationale of employing a standard protocol to prevent limb related complications. This protocol emphasises the meticulous proximal deployment of limbs, precisely aligned with the flow divider of the main body (Fig. 5B). Broda *et al.* conducted an analysis of potential LGO risk factors in their cohort of patients treated with Zenith Alpha limbs.¹² Interestingly, their study did not identify any LGO predictors. Notably, violations of the Zenith Alpha IFU, including instances such as deploying the flared limb within

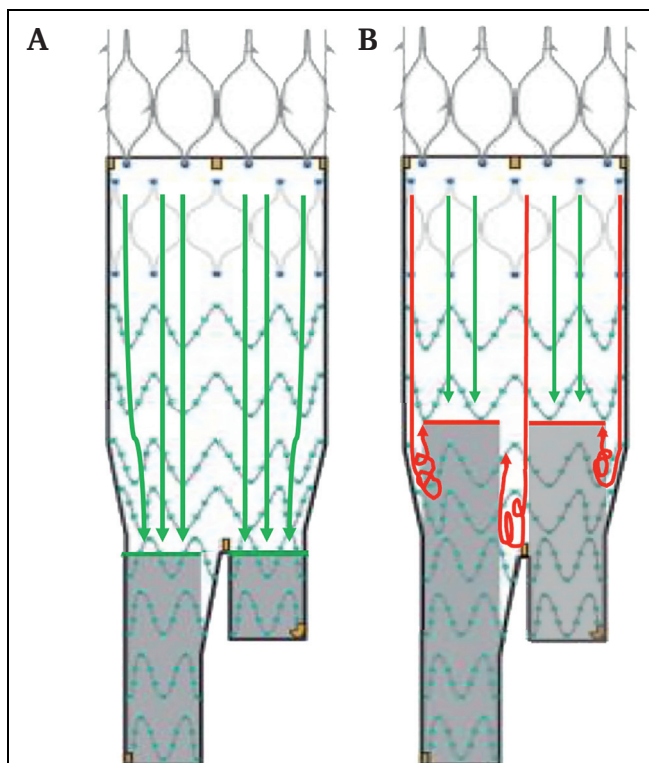


Figure 5. Hypothesis of blood flow according to limb deployment inside the main body of Cook Zenith Alpha endograft. (A) Iliac limb deployment proximally at the same level of the main body flow divider allows for linear blood flow (green arrows) from the main body to the iliac limbs. (B) Iliac limb deployment, even if aligned, above the main body flow divider creates turbulent blood flow (red arrows) between the main body and iliac limbs.

the main body's ipsilateral limb or misaligning the limbs within the main body, were not found to be associated with LGO.

However, in a more recent study by Ulsaker *et al.*, a significant association emerged between Zenith Alpha and an increased LGO rate compared with the Medtronic Endurant by Kaplan—Maier analysis (5.9% vs. 2.3% at four year follow up, respectively). This association was attributed to the compression of a flared limb within the main body gate.¹³

In the present study, the high rate of adjunctive iliac stenting increased iliac limb patency as suggested by Marques de Marino *et al.*¹⁴ reporting a 36 month primary patency of 99% in patients with primary iliac stenting. Similarly, Wen *et al.* reported a higher rate of limb stenting in patients with a narrow aortic bifurcation, but with similar limb patency during the follow up (3.6% vs. 2.6%).¹⁵

Draper *et al.*¹⁶ conducted an analysis of iliac thrombotic events following EVAR, revealing a non-significantly higher rate of thrombus formation in Alpha limbs than in other devices ($p = .070$). Similarly, Bianchini Massoni *et al.*¹⁷ investigated the incidence of intra-prosthetic graft thrombus, identifying specific risk factors, larger neck size and longer length of the main body, characteristics distinct to the Zenith Alpha main body. Notably, a higher ratio between the area of the main body and the gate areas correlated with thrombus formation.

Given these findings, the unique combination of a larger main body, increased thrombus formation propensity, and misalignment of iliac limbs positioned above the level of the flow divider could collectively contribute to the promotion of LGO in Zenith Alpha limbs.

Other possible factors associated with LGO can be identified from the flow inside the iliac limbs, particularly in severe iliac tortuosity, limb kinking, and outflow in the hypogastric or EIA (i.e., hypogastric occlusions, stenosis, or EIA calibre < 10 mm).

Moreover, like other experiences reported in the literature, in the present paper landing in the EIA (even if planned) was associated with a higher rate of LGO during follow up.⁵ However, it should be underlined that the number of patients reaching the five year follow up in the group landing in the EIA is low (< 10), with a possible effect on the log rank results of the Kaplan—Meier analysis. Nevertheless, both uni- and multivariable Cox analyses show a statistically significant difference.

The present study suffers from some limitations. The retrospective design of a multicentre experience can be associated with heterogeneity in iliac treatment; however, the protocol for iliac limb complication prevention was the same in the two centres of the study.

In conclusion, in this paper the role of a protocol for iliac limb occlusion prevention has been analysed in patients undergoing EVAR with the Zenith Alpha abdominal endograft. Through this protocol, it is possible to achieve a low rate of LGO, similar to other endografts.

CONFLICTS OF INTEREST

G.F., E.G., and M.G. are clinical proctors for Cook Zenith fenestrated endograft.

FUNDING

None.

APPENDIX A. SUPPLEMENTARY DATA

Supplementary data to this article can be found online at <https://doi.org/10.1016/j.ejvs.2024.06.036>.

REFERENCES

- 1 Hammond A, Hansrani V, Lowe C, Asghar I, Antoniou SA, Antoniou GA. Meta-analysis and meta-regression analysis of iliac limb occlusion after endovascular aneurysm repair. *J Vasc Surg* 2018;**68**:1916–24.
- 2 Bogdanovic M, Stackelberg O, Lindström D, Ersryd S, Jonsson M, Roy J, et al. Limb graft occlusion following endovascular aneurysm repair for infrarenal abdominal aortic aneurysm with the Zenith Alpha, Excluder, and Endurant devices: a multicentre cohort study. *Eur J Vasc Endovasc Surg* 2021;**62**:532–9.
- 3 Catanese V, Sangiorgi G, Sotgiu G, Saderi L, Settembrini A, Donelli C, et al. Clinical and anatomical variables associated in the literature to limb graft occlusion after endovascular aneurysm repair compared to the experience of a tertiary referral center. *Minerva Chir* 2020;**75**:51–9.
- 4 Cook Medical. Urgent field safety notice Zenith Alpha Spiral-Z Endovascular Leg. 2020 2020-01-14. Report No.: 2020FA0001.

Available at: <https://laegemiddelstyrelsen.dk/da/udstyr/sikkerhedsmeddelelser/2020/01/william-cook-europe-fremhaever-specifikke-punkter-i-brugsanvisningen-af-zenith-alpha-spiral-z-endovascular-leg-/~~/media/A9F12E26EFBF4A7AB89074FD03AF44E3.ashx> [Accessed 12 June 2024].

- 5 Wacirca A, Faggioli G, Pini R, Spath P, Gallitto E, Mascoli C, et al. The efficacy of a protocol of iliac artery and limb treatment during EVAR in minimising early and late iliac occlusion. *Eur J Vasc Endovasc Surg* 2020;**60**:663–70.
- 6 Wanhainen A, Van Herzele I, Bastos-Goncalves F, Bellmunt-Montoya S, Berard X, Boyle JR, et al. Editor's choice: European Society for Vascular Surgery (ESVS) 2024 Clinical Practice Guidelines on the Management of Abdominal Aorto-iliac Artery Aneurysms. *Eur J Vasc Endovasc Surg* 2024;**67**:192–331.
- 7 Chaikof EL, Fillinger MF, Matsumura JS, Rutherford RB, White GH, Blankensteijn JD, et al. Identifying and grading factors that modify the outcome of endovascular aortic aneurysm repair. *J Vasc Surg* 2002;**35**:1061–6.
- 8 Bianchini Massoni C, Gargiulo M, Giovanetti F, Freyrie A, Faggioli G, Gallitto E, et al. Adjunctive stenting of endograft limbs during endovascular treatment of infrarenal aortic and iliac aneurysms according to 3-projection completion angiography. *J Endovasc Ther* 2011;**18**:585–90.
- 9 Bianchini Massoni C, Gargiulo M, Freyrie A, Gallitto E, Mascoli C, Stella A. Abdominal aortic bifurcation anatomy and endograft limb size affect the use of adjunctive iliac stenting after bifurcated endograft deployment for abdominal aortic aneurysm. *J Cardiovasc Surg (Torino)* 2018;**59**:237–42.
- 10 Pini R, Faggioli G, Indelicato G, Gallitto E, Mascoli C, Abualhin M, et al. Anatomical predictors of flared limb complications in endovascular aneurysm repair. *J Endovasc Ther* 2019;**26**:550–5.
- 11 Gallitto E, Gargiulo M, Faggioli G, Pini R, Mascoli C, Freyrie A, et al. Impact of iliac artery anatomy on the outcome of fenestrated and branched endovascular aortic repair. *J Vasc Surg* 2017;**66**:1659–67.
- 12 Broda M, Eiberg J, Taudorf M, Resch T. Limb graft occlusion after endovascular aneurysm repair with the Cook Zenith Alpha abdominal graft. *J Vasc Surg* 2023;**77**:770–8.e2.
- 13 Ulsaker H, Lam M, Herje ML, Seternes A, Manstad-Hulaas F. A retrospective evaluation of intra-prosthetic thrombus formation after endovascular aortic repair in Cook Zenith Alpha and Medtronic Endurant II patients. *Eur J Vasc Endovasc Surg* 2023;**66**:644–51.
- 14 Marques de Marino P, Ibraheem A, Gafur N, Mufty H, Schubert N, Verhoeven EL, et al. Limb occlusion rate after EVAR with individualized graft limb selection and a liberal protocol of primary relining. *Ann Vasc Surg* 2021;**75**:445–54.
- 15 Wen W, Mufty H, Katsargyris A, Maleux G, Daenens K, Houthoofd S, et al. The influence of narrow aortic bifurcation on limb graft patency: a two-center retrospective study. *J Cardiovasc Surg (Torino)* 2022;**63**:708–15.
- 16 Draper K, Choi SHJ, Fung A, Baxter K, Taylor D, Chen JC, et al. Evaluation of factors associated with limb thrombus formation after endovascular aortic aneurysm repair. *J Vasc Surg* 2023;**77**:440–5.
- 17 Bianchini Massoni C, Ucci A, Perini P, Azzarone M, Mariani E, Bramucci A, et al. Prevalence, risk factors and clinical impact of intraprosthetic thrombus deposits after EVAR. *J Cardiovasc Surg (Torino)* 2020;**61**:729–37.

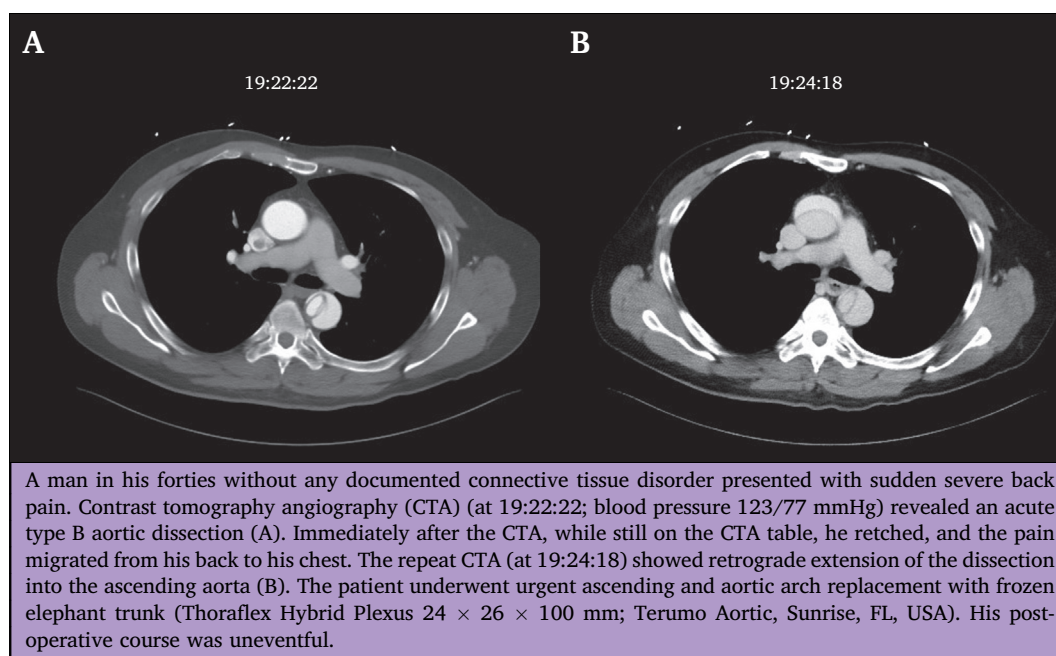
Eur J Vasc Endovasc Surg (2024) 68, 736

COUP D'OEIL

Retrograde Extension of Type B Acute Aortic Dissection on the CT Scan Table

Hisato Takagi*

Department of Cardiovascular Surgery, Shizuoka Medical Centre, Shizuoka, Japan



* Corresponding author. Department of Cardiovascular Surgery, Shizuoka Medical Centre, 762-1 Nagasawa, Shimizu-cho, Sunto-gun, Shizuoka 411-8611, Japan. E-mail address: kfgh973@ybb.co.jp (Hisato Takagi).

1078-5884/© 2024 European Society for Vascular Surgery. Published by Elsevier B.V. All rights are reserved, including those for text and data mining, AI training, and similar technologies.

<https://doi.org/10.1016/j.ejvs.2024.09.014>