

UNIVERSITA' DEGLI STUDI DI PARMA

Dottorato di ricerca in
“Diagnostica per immagini avanzata con tecniche
tridimensionali ad indirizzo interventistico”

Ciclo XX

**EVALUATION OF CORONARY ATHEROSCLEROSIS BY MULTISLICE
COMPUTED TOMOGRAPHY IN PATIENTS WITH ACUTE MYOCARDIAL
INFARCTION AND WITHOUT SIGNIFICANT CORONARY ARTERY STENOSIS:
A comparative study with quantitative coronary angiography**

Coordinatore:
Chiar.mo Prof. Umberto Squarcia

Tutor
Chiar.mo Prof. Ettore Astorri

Dottorando: Dr. Alberto Menozzi

Anno 2009

Introduction

Acute myocardial infarction (AMI) is due to coronary artery thrombosis complicating an atherosclerotic coronary plaque usually in the presence of obstructive coronary artery disease. However, it is known that an acute myocardial infarction may occur even in patients without significant coronary artery stenosis at coronary angiography, as it may be due to the disruption of mildly stenotic “vulnerable” plaques, which are undetectable by conventional coronary angiography and may lead to thrombotic complications [1, 2]. It has been reported that 9-31% of women and 4-14% of men with AMI have a normal coronary angiogram [3-6]. Coronary angiography is the reference method for assessing coronary artery disease, but, intravascular ultrasound and pathological studies indicate that it underestimates the extent of coronary atherosclerosis, especially in case of mild disease [7, 8]. Moreover, it is known that coronary angiography may not detect early stage atherosclerosis, because of the outward remodeling of atherosclerotic plaques [9]. Intravascular ultrasound, which is the current standard of reference for the assessment of coronary plaque volume and morphology, can only be used to study coronary lesions in the proximal segments of major vessels [10].

Multislice computed tomography (MSCT) is an emerging technique that allows the non-invasive detection of coronary artery stenosis and atherosclerotic plaques. A number of studies have shown that MSCT can reliably quantify plaque volumes *in vivo* and identify the major morphological features of atherosclerotic lesions [11-13].

The aim of this study was to evaluate the accuracy of quantitative 64-slice CT (CT-QCA) in identifying and quantifying atherosclerotic coronary lesions in comparison

with quantitative coronary angiography (CA-QCA) in a population of patients with AMI without significant coronary artery stenosis.

Methods

Patient selection. We evaluated 30 consecutive AMI patients with normal coronary arteries or non-significant coronary stenosis at coronary angiography. Myocardial infarction was defined as: 1) typical chest pain lasting >20 minutes; 2) persistent electrocardiographic changes; and 3) increased cardiac enzymes (Troponin I > 99th percentile and CK MB levels to > twice the upper normal limit).

The study exclusion criteria were: 1) The presence of any coronary stenosis causing a $\geq 50\%$ reduction in lumen diameter, as evaluated by quantitative coronary angiography; 2) a history of previous myocardial infarction or cardiomyopathy; 3) creatinine clearance <30 ml/min; and 4) an allergic reaction after contrast administration during coronary angiography. The localization of myocardial infarction was based on wall motion abnormalities detected by means of left ventriculography and transthoracic echocardiography. All of the patients gave their written informed consent to the study protocol, which was approved by the Institutional Review Board. The authors had full access to and take full responsibility for the integrity of the data. All authors have read and agree to the manuscript as written.

Study protocol. Patients with AMI without significant coronary artery stenosis at coronary angiography were asked to undergo 64-slice CT within three days of coronary angiography.

Coronary angiography and CA-QCA

Selective conventional coronary angiography was performed using standard techniques (Innova 2000 GE, General Electric, Milwaukee, US). Standard multiple projections were recorded for left and right coronary arteries, and 0.2 mg intracoronary nitrates were administered before contrast injection for the projections used for QCA analysis. Left ventriculography was performed in the right oblique projection. The coronary angiograms were analysed using an off-line computer-based software (MEDIS CMS version 6.0; MEDIS Imaging Systems, Leiden, The Netherlands) with an automatic edge-contour detection algorithm following standard and previously validated qualitative and quantitative parameters and definitions [14-16]. The angiograms were analysed by an independent and experienced operator unaware of the results of MSCT. The automatic edge detection program determines the vessel contours by assessing brightness along scan lines perpendicular to the vessel center. In order to achieve the best filling with contrast medium of the arterial segment, an image was selected from the second or third cardiac cycle after contrast administration. The software was calibrated using the outer diameter of the contrast-filled catheter. CT-QCA measurements were performed in all coronary segments, according to the 15-segment American Heart Association classification [17]. For each coronary segment, an end-diastolic frame was selected in a perpendicular projection with minimal foreshortening and branch overlap. In the presence of a coronary lesion, the frame that best showed the stenosis at its most severe degree was selected for analysis. The following parameters were calculated: 1) proximal and distal

reference vessel diameter (RVD); 2) minimal lumen diameter (MLD); and 3) percent diameter stenosis (DS), calculated as $100 (1 - \text{MLD}/\text{RVD})$.

MSCT data acquisition

All of the MSCT examinations were performed using a 64-slice CT scanner (Sensation 64 Cardiac, Siemens, Forchheim, Germany). First, an unenhanced scan was made using standardised parameters: 64 (32x2) slices per rotation, 0.6 mm detector collimation, gantry rotation time 330 ms, table feed 3.84 mm/rotation, tube voltage 120 kV, tube current 150 mAs and prospective X-ray tube modulation. This was followed by the CT angiographic acquisition using the following parameters: 64 (32x2) number of slices per rotation, 0.6 mm detector collimation, gantry rotation time 330 msec, effective temporal resolution 165 msec, spatial resolution 0.4 mm³, tube voltage 120 kV, tube current 900 mAs. Sublingual nitroglycerin 0.3 mg were administered to all patients before the examination. When heart rate was >65 beats/min, intra-venous beta-blocker (atenolol 5-10 mg) was administered. Between 80 and 100 ml of non ionic contrast material (Iomeron 400, Bracco, Milan, Italy) were administered in the antecubital vein at a flow rate of 4-6 ml/s followed by a 50 ml saline chaser. A bolus tracking technique was used to synchronise the arrival of the contrast in the coronary arteries, and the scan was started once contrast attenuation in a pre-selected region of interest in the ascending aorta reached a predefined threshold of +100 Hounsfield Units (HU). All of the images were acquired during an inspiratory breath hold of approximately 10-12 sec, with the simultaneous recording of the patient's electrocardiogram.

MSCT data analysis

The CT data set was analysed by two independent and experienced readers unaware of the CA-QCA using an off-line workstation software package (Leonardo, Siemens Medical Solutions, Forchheim, Germany). To obtain optimal image quality, datasets of the reconstructed coronary vessels were created at least at two points of the cardiac cycle using a retrospective ECG gating algorithm (one diastolic cardiac phase usually at -350 msec from the R waves and one end-systolic phase at +300 msec). In the presence of motion artefacts, additional reconstructions were made at different time points of the R-R interval.

The analysis was performed using multiplanar reconstruction (MPR) of the original axial images of the coronary arteries. As for in the case of quantitative coronary angiography, all coronary segments were analysed according to the AHA classification. Each coronary segment was delimited by identifiable side-branches in both image modalities.

Any discernible structure that could be assigned to the coronary artery wall, had a CT density less than the contrast-enhanced coronary lumen and greater than the surrounding epicardial fat tissue, and could be identified in at least two independent planes, was considered as a non calcified coronary atherosclerotic plaque. Any structure with a density of ≥ 130 HU that could be visualised separately from the contrast-enhanced coronary lumen (because it was “embedded” within a non calcified plaque or because its density was above the contrast-enhanced lumen), could be assigned to the coronary artery wall, and could be identified in at least two independent planes, was considered a calcified atherosclerotic plaque (12).

The display settings used for the lumen and plaque analysis were manipulated in order to achieve optimal separation between the vessel lumen, wall and surrounding tissue.

For each coronary segment a cross-sectional image was created perpendicular to the centerline of the vessel, and the vessel area at the proximal tract and 5 mm from the proximal point of measurement was calculated, with the corresponding diameters. The mean of the diameters was used as the reference vessel diameter for comparison with quantitative coronary angiography. In the presence of coronary plaque, the vessel area at the plaque site, the plaque area, the minimum lumen diameter and the percent stenosis were determined as was the remodeling index. Positive vessel remodeling was defined as a vessel area at plaque site/reference vessel area ratio of >1.05 . Plaque attenuation was measured and plaques were classified as calcified if $HU > 130$, non-calcified if < 130 HU, or mixed in the presence of areas with densities both > 130 HU and < 130 HU.

Statistical analysis

The quantitative data are presented as mean values \pm standard deviation. Spearman's correlation coefficient and Bland–Altman analysis were used to compare the vessel diameter measurements and the CT and CA quantifications of lesion severity and a p value < 0.01 was considered significant. The continuous variables were compared by means of the *t* test and categorical variables were compared by means of the χ^2 test. Statistical analysis was performed with SPSS version 12.0 (SPSS Inc., Chicago, USA).

Results

Thirty patients were enrolled in the study and underwent MSCT after coronary angiography. Their clinical characteristics are shown in Table 1. Multislice CT was obtained 6.5 ± 4.1 days after acute myocardial infarction and 4.6 ± 3.8 days after coronary angiography. Forty-seven (10.4%) of the 450 coronary segments were not assessable by MSCT because of motion artefacts or small size (mean diameter 1.25 ± 0.50 mm); all of the non assessable segments were distal coronary tracts or side branches (Table 2).

Coronary diameter analysis

The mean proximal reference diameter was 2.65 ± 0.90 mm at CA-QCA and 2.88 ± 0.75 mm at CT-QCA. The overall correlation between the CT-QCA and CA-QCA for quantification of coronary diameters was $r_s = 0.77$, $p < 0.001$ (Figure 1). CT-QCA tended to overestimate coronary size, with a systematic error of +8.6% (Figure 2). The mean minimal lumen diameter was 2.24 ± 0.87 mm at CA-QCA and 2.69 ± 0.87 mm at CT-QCA ($r_s = 0.72$, $p < 0.001$).

Coronary stenosis analysis

The mean percent stenosis was $14.4 \pm 8.0\%$ at CA-QCA and $4.0 \pm 11.0\%$ at CT-QCA ($r_s = 0.11$, $p = 0.03$). In the coronary segments with atherosclerotic plaques the mean percent stenosis was $34.0 \pm 11\%$ at CT-QCA and $16.8 \pm 9\%$ at CA-QCA ($r_s = 0.11$, $p = 0.37$). (Figure 3). The mean plaque area at CT-QCA was 4.7 ± 2.1 mm². Mean Agatston coronary calcium score was 106.6 ± 258.5 (range 0-1325, median 13.4). CT-QCA revealed the presence of 50 plaques (19 non calcified, 12 mixed, 19 calcified), of which only 11 were also detected by CA-QCA. In four patients CT-QCA showed the complete absence of coronary plaques. The coronary plaque

distribution is shown in Table 2. Positive remodeling was present in 38 lesions (76%) (mean remodeling index 1.2 ± 0.3). In particular positive remodeling was present in as many as 32 of the 39 plaques (82.1%) identified by CT but not visualised by CA-QCA, and in only 6 of the 11 plaques identified also by CA-QCA (54.5%).

Infarct-related artery analysis

CT-QCA identified 25 plaques in infarct-related arteries (IRA) in 19 patients, of which 17 were located in proximal segments and 8 in mid-segments, while CA-QCA identified 8 plaques in infarct-related arteries, with 6 plaques in proximal segments and 2 in mid-segments. Fourteen plaques in infarct-related arteries were non calcified, 5 were mixed and 6 were calcified; in non infarct-related arteries, 14 plaques were calcified, 5 were non calcified and 6 were mixed. The mean percent stenosis and remodeling index were not significantly different between infarct-related and non infarct-related arteries plaques (1.20 ± 0.20 vs 1.21 ± 0.19 , $p=0.92$)(Table 3).

Discussion

Our findings highlight the differences in evaluating coronary atherosclerosis between conventional coronary angiography and 64-slice CT: although the two methods correlate well in terms of coronary diameter analysis, the correlation in detecting non significant coronary artery stenosis is limited.

We found that 64-slice CT, given its almost isotropic voxel resolution can accurately measure and quantitatively analyse coronary arteries, showing a good

correlation with CA-QCA ($r_s=0.77$). Only a few studies have systematically compared the accuracy of measuring coronary artery lumen diameters by means of CT and CA [18, 19]. A previous study by Cury et al. [19] showed only a moderate correlation ($r=0.48$) between 16-slice CT and quantitative coronary angiography. The tendency of CT to overestimate coronary artery size is probably due to its more limited spatial resolution in comparison with CA, which does not allow an exact definition of outer vessel boundaries, and the use of image display settings focused on plaque detection.

In the case of non significant coronary artery disease, there are substantial differences in coronary stenosis quantification between CT-QCA and CA-QCA. In our study, CT-QCA detected a significant number of coronary plaques that were not seen by CA-QCA, and was capable of characterising the composition of coronary plaques on the basis of their density, distinguishing between calcified and non calcified plaques. Moreover, in segments with coronary plaques mean percent stenosis calculated by CT-QCA was significantly higher in comparison to CA-QCA ($34.0\pm 11.0\%$ vs $16.8\pm 9.0\%$).

MSCT directly identifies coronary plaques, whereas conventional coronary angiography images the lumen contour of coronary vessels but does not provide any information concerning the vessel wall, plaque volume and may therefore underestimate the atherosclerotic burden and possible vulnerable plaques leading to acute myocardial infarction.

Intracoronary ultrasound (IVUS) is the gold standard for plaque detection and quantification of non-critically stenotic lesions, but it is invasive and time-consuming, and can not be used extensively in all coronary arteries, but only in

selected proximal coronary segments. Its clinical applicability is therefore usually limited to assessing a few coronary segments, while in the clinical setting of angiographically normal coronary arteries an extensive analysis is needed. Multislice computed tomography has the advantage of allowing a non invasive evaluation of the complete coronary artery tree.

Preliminary studies have also shown that CT can assess the morphology and composition of culprit lesions in patients with acute coronary syndrome [20, 21], which show a higher prevalence of non calcified plaque and positive remodeling index [22, 23].

In our population of patients with acute myocardial infarction, CT-QCA revealed the presence of 25 plaques in infarct-related artery compared to only 8 plaques detected by CA-QCA; most of the coronary plaques in infarct-related arteries were non calcified.

Moreover in our study, CT identified positive remodeling in a large number of plaques (76%), with a much higher prevalence in the group of plaques detected only by CT-QCA (82.1% vs 54.5%). This finding confirms that coronary angiography identifies mainly negatively remodeled plaques and it has limitation in the evaluation of positive remodeled coronary plaques.

In four patients CT-QCA showed the complete absence of any coronary plaque; a different diagnosis may therefore be hypothesized in this subgroup, such as possible myocarditis or embolic myocardial infarction.

In patients with acute myocardial infarction, demonstrating the absence of significant coronary stenosis at coronary angiography may challenge the diagnosis. However it is known that the prognosis of these patients is similar to that of

patients with AMI and significant coronary disease. The use of CT-CA may confirm the diagnosis of myocardial infarction on an atherosclerotic basis and therefore may support the use of optimal antithrombotic therapy and secondary prevention therapy.

In seven patients, it was not possible to define the infarct-related artery clearly, because of the absence of wall motion abnormalities. Left ventriculography and transthoracic echocardiogram are the most widely used techniques to evaluate the localization and extent of myocardial infarction, but they have a limited sensitivity in identifying small areas of necrosis. Cardiac magnetic resonance with gadolinium enhancement can detect areas of myocardial fibrosis and differentiate *in vivo* myocardial scarring due to ischemic aetiology or myocarditis, and it may have an incremental role over standard imaging techniques in this setting. Multislice computed tomography is an attractive non invasive method for the analysis of coronary plaques, but it is limited by radiation exposure, which vary from 15 to 21 mSV (24) per examination, although the introduction of the prospective gating technique has the potential to reduce radiation exposure to 1.1-3.0 mSV (25).

In conclusion, CT-CA may be a valuable noninvasive imaging method of assessing overall plaque burden and may complement coronary angiography in patients with acute myocardial infarction without significant coronary stenosis, although it is still limited in identifying culprit lesions in this population.

Table 1: Population characteristics

No of patients	30
Age (years \pm SD; range)	62 \pm 16 (37-85)
Male	9 (30%)
Female	21 (70%)
Risk factors	
Family history	10 (30%)
Hypertension	21 (70%)
Dyslipidemia	14 (46,6%)
Smoking	6 (20%)
Diabetes mellitus	1 (3%)
Obesity	3 (10%)
Clinical presentation	
NSTEMI	29 (96.6%)
STEMI	1 (3.4%)
Mean CK MB peak value (ng/ml)	22,2 \pm 26,5
Mean Troponin I peak value (ng/ml)	4.2 \pm 9.3
Location of AMI	
Anterior	14
Inferior	4
Lateral	2
Normal kinesis	10
Mean ejection fraction	55% \pm 8% (Median 55%)

Abbreviations: AMI = acute myocardial infarction; SD = standard deviation;

NSTEMI = non-ST elevation myocardial infarction; STEMI = ST-elevated myocardial infarction.

Table 2: Distribution of coronary plaques at CT-QCA.

Seg.	Name	Atherosclerotic plaque types				NA seg.
		Non calcified	Mixed	Calcified	Total	
1	RCA prox	3	2	3	8	0
2	RCA m	2	1	0	3	0
3	RCA d	0	1	0	1	1
4	PDA	0	0	0	0	6
5	LM	1	1	2	4	0
6	LAD prox	9	5	3	17	0
7	LAD m	3	1	5	9	0
8	LAD d	0	0	0	0	0
9/10	D1/D2	0	0	0	0	21
11	CFX p	0	1	3	4	0
12	OM1	0	0	1	1	0
13	CFX m	1	0	1	2	0
14	OM2	0	0	1	1	13
15	CFX d	0	0	0	0	6
Tot		19	12	19	50	47

Abbreviations: Seg. = segment; NA = not assessable; CA-QCA = quantitative coronary angiography based on coronary angiography; CT-QCA = quantitative coronary angiography based on computed tomography; RCA=right coronary artery; PDA=posterior descending artery; LM = left main coronary artery; LAD = left anterior descending artery; D1/D2 = first and second diagonal branches; CFX = circumflex coronary artery; OM1/2 = obtuse marginal branches; prox = proximal tract; m = medium tract; d =distal tract

Table 3: Characteristics of infarct-related artery plaques and non infarct-related artery plaques

	Infarct-related artery plaques (n=25)	Non infarct-related artery plaques (n=25)	<i>P</i> value
Non calcified (%)	14 (28%)	5 (10%)	
Mixed (%)	5 (10%)	6 (12%)	0.02
Calcified (%)	6 (12%)	14 (28%)	
Remodeling index	1.20±0.20	1.21±0.19	0.92
Mean % stenosis	34±9	32±13	0.49

Abbreviations: LM = left main coronary artery; LAD = left anterior descending artery; CFX = circumflex coronary artery; RCA=right coronary artery

Figure 1: The correlation between CT-QCA and CA-QCA in terms of coronary reference diameter was $r_s=0.77$, $p<0.001$.

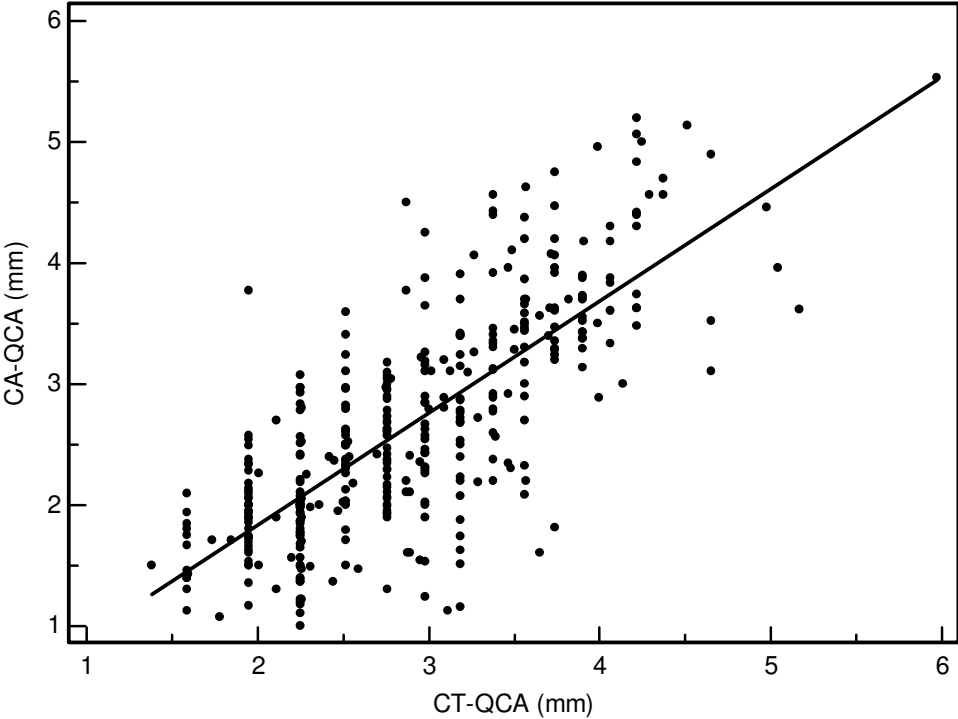


Figure 2: Bland-Altman analysis of CT-QCA versus CA-QCA demonstrated that CT-QCA slightly overestimated coronary reference diameter compared to CA-QCA (correlation coefficient $r=0.28$, $p<0.001$).

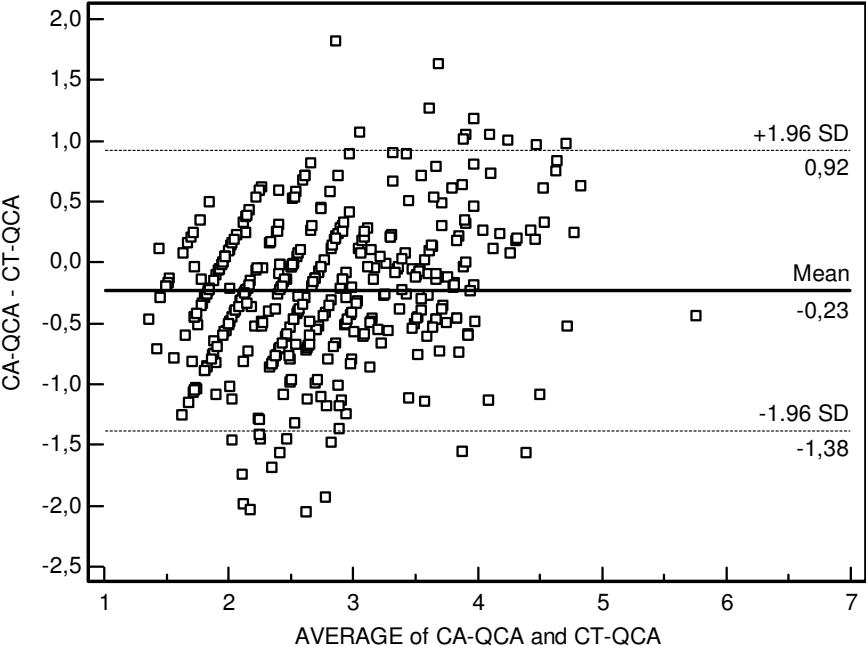


Figure 3 : Comparison of stenosis quantification by CT-QCA and CA-QCA in coronary plaques identified by CT-QCA.

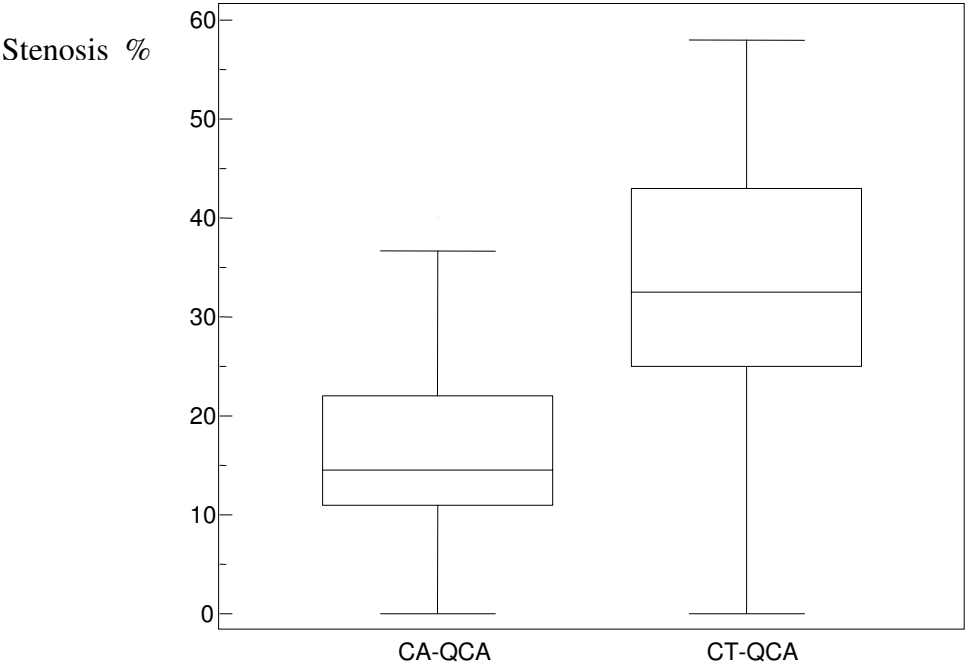


Figure 4: Case of a 55-yo patient with AMI, with a hypokinetic lateral wall, peak CK MB mass value of 55 ng/ml. **Panel A** Mixed atherosclerotic plaque at proximal left circumflex coronary artery detected by 64 -CT; **Panel B:** Cross section of MPR reconstruction at coronary plaque level: the calcified (898 HU) and the non calcified components (78 HU) are well demarcated; **Panel C:** Coronary vessel and plaque area measures. **Panel D:** Coronary angiography showing normal CFX lumen

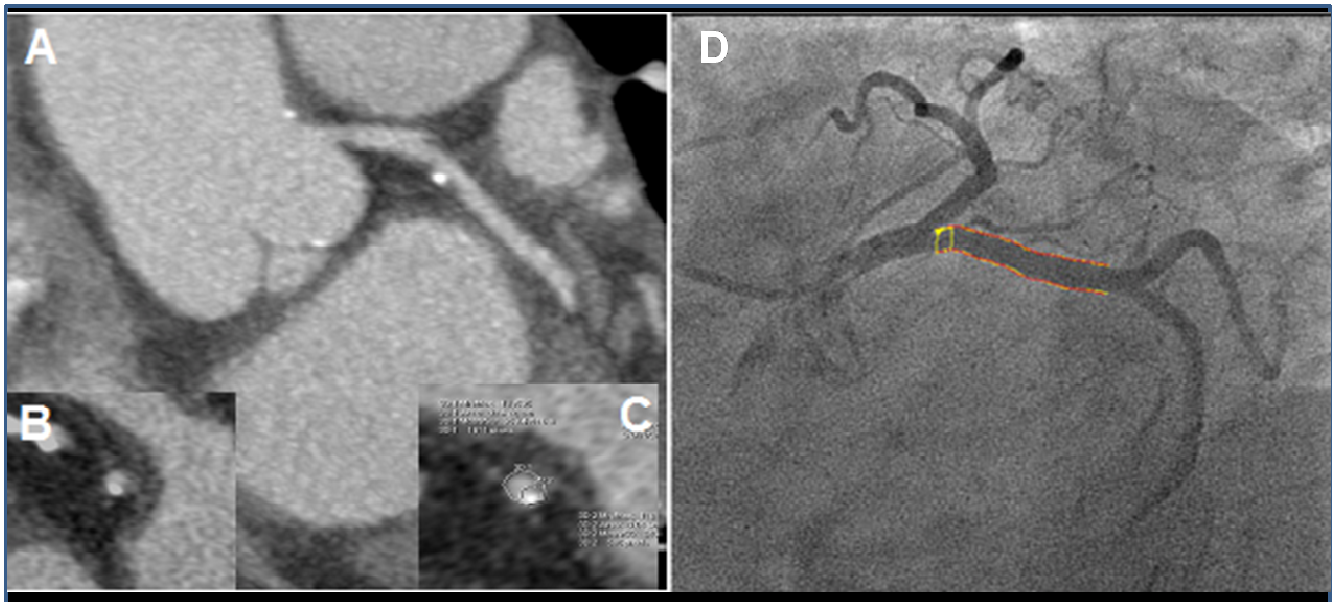

Figure 5: Coronary plaque characteristics in a 62-year-old women with anterior AMI.

Panel A: CA-QCA of medium tract of LAD; **panel B:** MIP reconstruction of LAD; **panel C:** MPR reconstruction of LADm; **panel D:** axial image at plaque level. CA-QCA showed a 14% stenosis in the first tract of LADm; CT-QCA showed multiple plaques, with a proximal calcified plaque (HU 789) corresponding to the stenosis detected by CA and a more distal mixed eccentric plaque (79 HU non calcified component, 535 HU calcified spot), remodeling index= 1.1, 28% stenosis (arrowhead).

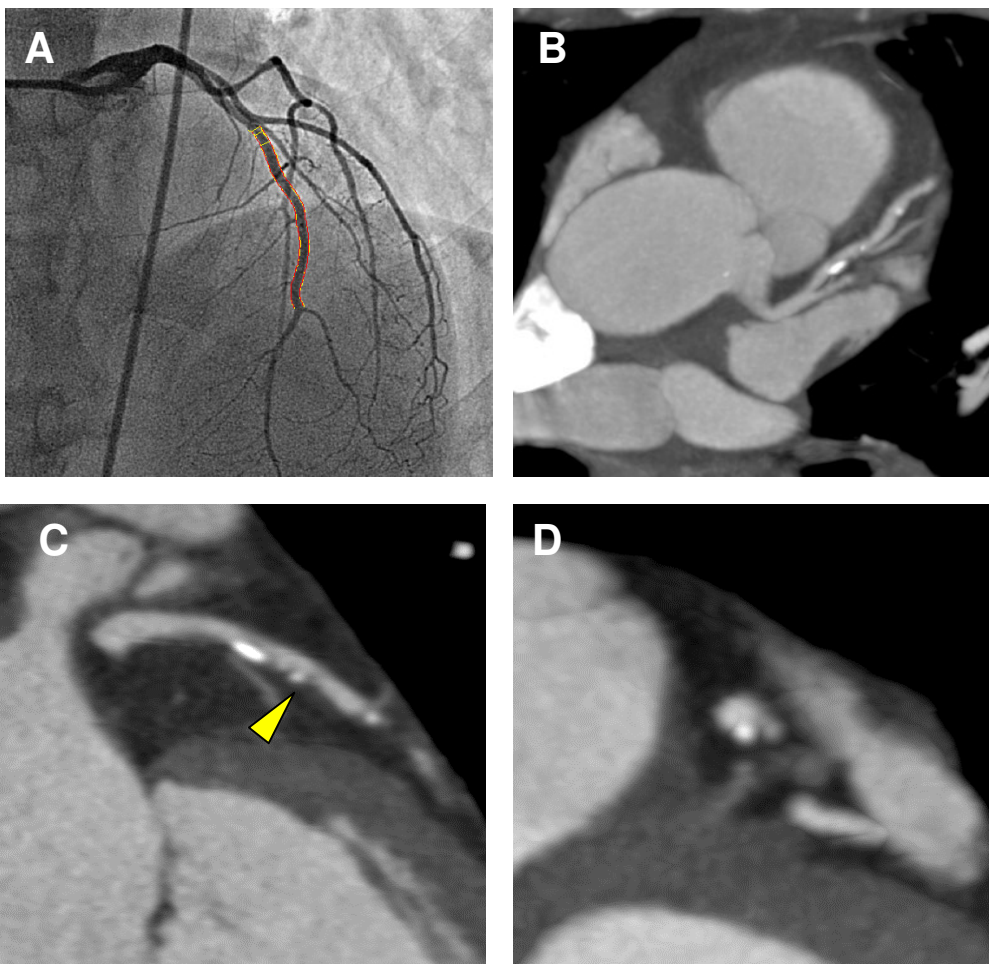


Figure 1: The correlation between CT-QCA and CA-QCA in terms of coronary reference diameter was $r_s=0.77$, $p<0.001$.

Figure 2: Bland-Altman analysis of CT-QCA versus CA-QCA demonstrated that CT-QCA slightly overestimated coronary reference diameter compared to CA-QCA (correlation coefficient $r=0.28$, $p<0.001$).

Figure 3 : Comparison of stenosis quantification by CT-QCA and CA-QCA in coronary plaques identified by CT-QCA.

Figure 4: Case of a 55-yo patient with AMI, with a hypokinetic lateral wall, peak CK MB mass value of 55 ng/ml. **Panel A** Mixed atherosclerotic plaque at proximal left circumflex coronary artery detected by 64 -CT; **Panel B:** Cross section of MPR reconstruction at coronary plaque level: the calcified (898 HU) and the non calcified components (78 HU) are well demarcated; **Panel C:** Coronary vessel and plaque area measures. **Panel D:** Coronary angiography showing normal CFX lumen

Figure 5: Coronary plaque characteristics in a 62-year-old women with anterior AMI.

Panel A: CA-QCA of medium tract of LAD; **panel B:** MIP reconstruction of LAD; **panel C:** MPR reconstruction of LADm; **panel D:** Axial image at plaque level. CA-QCA showed a 14% stenosis in the first tract of LADm; CT-QCA showed multiple plaques, with a proximal calcified plaque (HU 789) corresponding to the stenosis detected by CA and a more distal mixed eccentric plaque (79 HU non calcified

component, 535 HU calcified spot), remodeling index= 1.1, 28% stenosis (arrowhead).

Bibliography:

1. Mann JM, Davies MJ. Vulnerable plaque. Relation to degree of stenosis in human coronary arteries. *Circulation*. 1996; 94: 928-31.
2. Libby P, Theroux P. Pathophysiology of coronary artery disease. *Circulation*. 2005; 111: 3481-88.
3. Zimmerman F, Cameron A, Fisher LD, Ng G. Myocardial infarction in young adults: angiographic characterization, risk factor and prognosis (CASS Registry). *J Am Coll Cardiol*. 1995; 26: 654-61.
4. Bugiardini R, Bairez Merz GM. Angina with normal coronary arteries: a changing philosophy. *JAMA*. 2005; 293:477-484.
5. Bugiardini R, Manfrini O, De Ferrari GM. Unanswered questions for management of acute coronary syndrome: risk stratification of patients with minimal disease or normal findings on coronary angiography. *Arch Internal Medicine*. 2006; 166: 1391-5.
6. Germing A, Lindstaedt M, Ulrich S, Grewe P, Bojara W, Lawo T, von Dryander S, Jager D, Machraoui A, Mugge A, Lemke B. Normal Angiogram in acute coronary syndrome - preangiographic risk stratification, angiographic finding and follow-up. *Int Journal Card*. 2005; 99: 19-23.
7. Alfonso F, Macaya C, Goicolea J, Iniguez A, Hernandez R, Zamorano J, Perez-Vizcayne MJ, Zarco P. Intravascular ultrasound imaging of angiographically normal coronary segments in patients with coronary artery disease. *Am Heart J*. 1994; 127: 536-544.
8. Nissen SE, Gurley JC, Grines CL, Booth DC, McClure R, Berk M, Fischer C, DeMaria AN. Intravascular ultrasound assessment of lumen size and wall

- morphology in normal subjects and patients with coronary artery disease. *Circulation*. 1991; 84: 1087-1099.
9. Glagov S, Weisenberg E, Zarins CK, Stankunavicius R, Kolettis GJ. Compensatory enlargement of human atherosclerotic coronary arteries. *N Engl J Med*. 1987; 316: 371-75.
 10. Mintz GS, Painter JA, Pichard AD, Kent KM, Satler LF, Popma JJ, Chuang YC, Bucher TA, Sokolowicz LE, Leon MB. Atherosclerosis in angiographically "normal" coronary artery reference segments: an intravascular ultrasound study with clinical correlations. *J Am Coll Cardiol*. 1995; 25: 1479-85.
 11. Achenbach S, Moselewski F, Ropers D, Ferencik M, Hoffmann U, MacNeill B, Pohle K, Baum U, Anders K, Jang IK, Daniel WG, Brady TJ. Detection of calcified and noncalcified coronary atherosclerotic plaque by contrast-enhanced, submillimeter multidetector spiral computed tomography: a segment-based comparison with intravascular ultrasound. *Circulation*. 2004; 109: 14-7.
 12. Schroeder S, Kuettner A, Leitritz M, Janzen J, Kopp AF, Herdeg C, Heuschmid M, Burgstahler C, Baumbach A, Wehrmann M, Claussen CD. Reliability of differentiating human coronary plaque morphology using contrast-enhanced multislice spiral computed tomography: a comparison with histology. *J Comput Assist Tomogr*. 2004; 28: 449-54.
 13. Moselewski F, Ropers D, Pohle K, Hoffmann U, Ferencik M, Chan RC, Cury RC, Abbara S, Jang IK, Brady TJ, Daniel WG, Achenbach S. Comparison of measurement of cross-sectional coronary atherosclerotic

- plaque and vessel areas by 16-slice multidetector computed tomography versus intravascular ultrasound. *Am J Cardiol.* 2004; 94: 1294-7.
14. Kirkeeide RL, Gould.KL, Parsel L. Assessment of coronary stenoses by myocardial perfusion imaging during Pharmacologic Coronary Vasodilatation. Validation of Coronary flow reserve as a single integrated functional measure of stenosis severity reflecting all its geometric dimensions. *J Am Coll Cardiol.* 1986; 7: 103-13.
 15. Popma JJ, LanskyAJ, Yeh W, Kennard ED, Keller MB, Merritt AJ, DeFalco RA, Desai A, Pacera JH, Schnabel JF, Niedermeyer V, Baim DS, Detre KM. Reliability of the quantitative angiographic measurements in the New Approaches to Coronary Intervention (NACI) registry: a comparison of clinical site and repeated angiographic core laboratory readings. *Am J Cardiol.* 1997; 80: 19K-25K.
 16. Berry C, L'Allier PL, Gregoire J, Lesperance J, Levesque S, Ibrahim R, Tardif JC. Comparison of Intravascular Ultrasound and Quantitative Coronary Angiography for the assessment of coronary artery disease progression. *Circulation.* 2007; 115: 1851-57.
 17. Austen WG, Edwards JE, Frye RL, Gensini GG, Gott VL, Griffith LS, McGoon DC, Murphy ML, Roe BB. A reporting system on patients evaluated for coronary artery disease. Report of the Ad Hoc Committee for grading of Coronary Artery Disease, Council on Cardiovascular Surgery, American Heart Association. *Circulation.* 1975; 51: 5-40.
 18. Sinha AM., Mahnken AH, Borghans A, Kruger S, Koos R, Dedden K, Wildberger JE, Hoffmann R. Multidetector-row computed tomography vs.

- angiography and intravascular ultrasound for the evaluation of the diameter of proximal coronary arteries. *Int J Cardiol.* 2006; 110: 40-5.
19. Cury RC, Ferencik M, Achenbach S, Pomerantsev E, Nieman K, Moselewski F, Abbara S, Jang IK, Brady TJ, Hoffmann U. Accuracy of 16-slice multi-detector CT to quantify the degree of coronary artery stenosis: assessment of cross-sectional and longitudinal vessel reconstructions. *Eur J Radiol.* 2006; 57: 345-50.
 20. Hoffmann U, Moselewski F, Nieman K, Jang I, Ferencik M, Rahman AM, Cury RC, Abbara S, Joneidi-Jafari H, Achenbach S, Brady TJ. Noninvasive Assessment of Plaque Morphology and Composition in Culprit and Stable Lesions in Acute Coronary Syndrome and Stable Lesions in Stable Angina by Multidetector Computed Tomography. *J Am Coll Cardiol.* 2006; 47: 1655-62.
 21. Leber AW, Knez A, White CW, Becker A, von Ziegler F, Muehling O, Becker C, Reiser M, Steinbeck G, Boekstegers P. Composition of coronary atherosclerotic plaques in patients with acute myocardial infarction and stable angina pectoris determined by contrast-enhanced multislice computed tomography. *Am J Cardiol.* 2003; 91: 714-8.
 22. Achenbach S, Ropers D, Hoffmann U, MacNeill B, Baum U, Pohle K, Brady T, Pomerantsev E, Ludwig J, Flachskampf FA, Wicky S, Jang I, Daniel WG. Assessment of coronary remodeling in stenotic and nonstenotic coronary atherosclerotic lesions by multidetector spiral computed tomography. *J Am Coll Cardiol.* 2004; 43: 842-7.

23. Motoyama S, Kondo T, Sarai M, Sugiura A, Harigaya H, Sato T, Inoue K, Ohumura M, Ishii J, Anno H, Virmani R, Ozaki Y, Hishida H, Narula J. Multislice computed tomography characteristics of coronary lesions in acute coronary syndromes. *J Am Coll Cardiol.* 2007; 50: 319-26.
24. Mollet NR, Cademartiri F, van Mieghem CA, Runza G, McFadden EP, Baks T, Serruys PW, Krestin GP, de Feyter PJ. High resolution spiral computed tomography coronary angiography in patients referred for diagnostic conventional coronary angiography. *Circulation.* 2005; 112: 2318–2323
25. Husmann L, Valenta I, Gaemperli O, Adda O, Treyer V, Wyss CA, Veit-Haibach P, Tatsugami F, von Schulthess GK, Kaufmann P. Feasibility of low-dose coronary CT angiography: first experience with prospective ECG-gating. *Eur Heart J.* 2008; 29: 153-4.