


Traumatic and iatrogenic sciatic nerve injury in 38 dogs and 10 cats: Clinical and electrodiagnostic findings

Diletta Dell'Apa¹ | Luigi Auletta²  | Samuel Okonji³ | Alberto Cauduro⁴ |
 Maurizio Dondi¹ | Mauro Opreni⁴ | Gualtiero Gandini³ | Ezio Bianchi¹

¹Department of Veterinary Science, University of Parma, Parma, Italy

²Department of Veterinary Medicine and Animal Sciences (DIVAS), University of Milan, Milan, Italy

³Department of Veterinary Medical Science, University of Bologna, Bologna, Italy

⁴Neurovet, Milan, Italy

Correspondence

Luigi Auletta, Department of Veterinary Medicine and Animal Sciences (DIVAS), University of Milan, Milan, Italy.
 Email: luigi.auletta@unimi.it

Abstract

Background: Reports describing sciatic nerve injuries (SNI) and their outcome are scarce in veterinary medicine.

Hypothesis: Describe the causes of traumatic and iatrogenic SNI and evaluate which clinical and electrodiagnostic findings predict outcome.

Animals: Thirty-eight dogs and 10 cats with confirmed SNI referred for neurologic and electrodiagnostic evaluation.

Methods: Clinical and electrodiagnostic examination results, including electromyography (EMG), motor nerve conduction studies, muscle-evoked potential (MEP), F-waves, sensory nerve conduction studies, and cord dorsum potential (CDP), were retrospectively evaluated. Quality of life (QoL) was assessed based on owner interviews.

Results: Surgery (42%) and trauma (33%) were the most common causes of SNI; in dogs, 24% were caused by bites from wild boars. Ability to flex and extend the tarsus was significantly associated with positive outcome in dogs. Mean time from onset of clinical signs until electrodiagnostic evaluation was 67 ± 65 (range, 7-300) days and 65 ± 108 (range, 7-365) days for dogs and cats, respectively. A cut-off amplitude of 1.45 mV for compound motor action potentials (CMAP) was predictive of positive outcome in dogs ($P = .01$), with sensitivity of 58% and specificity of 100%.

Conclusions and Clinical Importance: Clinical motor function predicts recovery better than sensory function. Electrodiagnostic findings also may play a role in predicting the outcome of SNI. Application of the proposed CMAP cut-off amplitude may assist clinicians in shortening the time to reassessment or for earlier suggestion of salvage procedures. Owners perceived a good quality of life (QoL), even in cases of hindlimb amputation.

KEYWORDS

axonotmesis, electrodiagnostics, motor nerve conduction studies, neurology, neurotmesis, peripheral nervous system disorders

Abbreviations: CDP, cord dorsum potential; CMAP, compound motor action potentials; EDX, electrodiagnostic tests; EMG, electromyography; MEP, muscle evoked potentials; MNCS, motor nerve conduction studies; QoL, quality of life; SNI, sciatic nerve injury; SPA, spontaneous pathologic activity.

This is an open access article under the terms of the [Creative Commons Attribution-NonCommercial](https://creativecommons.org/licenses/by-nc/4.0/) License, which permits use, distribution and reproduction in any medium, provided the original work is properly cited and is not used for commercial purposes.

© 2024 The Authors. *Journal of Veterinary Internal Medicine* published by Wiley Periodicals LLC on behalf of American College of Veterinary Internal Medicine.

1 | INTRODUCTION

Peripheral nerve injuries are common in dogs and cats. Sciatic nerve injury (SNI) in dogs and cats has been reported in association with traumatic events involving pelvic and femoral fractures or crush injuries, penetrating wounds, and iatrogenic insults.^{1,2} The sciatic nerve is formed by the tibial and common peroneal nerves closely bound together; the 2 branches divide variably at any point from the coxofemoral joint to the popliteal space.³ Depending on the location of the injury, 1 or both branches may be affected. Lesions affecting the sciatic nerve trunk or both the tibial and common peroneal nerve have been reported to have the worst prognosis.²

Regardless of the location and extent of the lesion, the outcome of peripheral nerve injury is influenced by the severity of the functional consequences of the damage.⁴ In particular, neurotmesis, involving transection of axons and perineural connective tissue, has the poorest prognosis. On the other hand, the prognosis is variable in axonotmesis, which is characterized by damage to a certain number of axons with preserved perineural connective tissue and focal demyelination. Finally, in the presence of neurapraxia, the functional consequences of the damage are transient because little or no structural damage has occurred, usually consisting only of focal demyelination, and such patients usually recover spontaneously in a few days.^{5,6} However, depending on the distance from the nerve lesion to the muscle to be reinnervated, several weeks to months may be required to see the eventual beneficial effects of axonal regrowth.^{7,8}

An estimate of the functional damage to nerve fibers can be provided by an accurate neurological examination and the application of electrodiagnostic tests (EDX).^{9,10} Clinical and EDX results have been investigated as prognostic indicators in traumatic brachial plexus injuries.^{4,11} Only a few studies have been published on SNI in dogs and cats.^{1,2,12} The ability of neurological examination and EDX to predict the long-term outcome of these patients has never been specifically investigated. Moreover, information regarding the quality of life (QoL) of injured animals and owner perception is lacking.

Our primary aim was to describe the causes of SNI and the clinical and EDX findings in dogs and cats referred for SNI. In addition, the results of neurological examination and EDX tests were evaluated to understand whether they were predictive of clinical outcome. Finally, the QoL of the affected patients and owner perception was investigated.

2 | MATERIALS AND METHODS

2.1 | Animals

Privately owned dogs and cats referred or presented with naturally occurring hind limb monoparesis or monoplegia were considered eligible for inclusion in our cohort study. All clinical and diagnostic procedures were performed in agreement with best practice standards of veterinary practice. All owners signed written informed consent, agreeing to all procedures and the use of all data for scientific purposes.

2.2 | Sample and clinical evaluation

The medical databases of the 3 different veterinary hospitals (Department of Veterinary Science of the University of Parma, Department of Veterinary Medical Science of the University of Bologna, and Neurovet Milano) were searched to identify dogs and cats diagnosed with suspected SNI during the period 2006 to 2020. Inclusion criteria were a medical record including all signalment data, information about the affected limb and the date at which the neurological signs first appeared, results of a neurological and EDX evaluation, history of hyperacute or acute paresis or paralysis of the sciatic nerve confirmed by neurological and EDX evaluations, and follow-up of at least 12 months.

Exclusion criteria were nerve dysfunction secondary to neoplasia (eg, peripheral nerve sheath tumor) or vascular disease (eg, ischemic neuromyopathy) and evidence of concomitant sacral trauma (eg, luxation or fractures, suspected cauda equina involvement as evidenced by the presence of urinary retention, decreased or absent perineal reflex, decreased or absent anal tone, decreased or absent perineal and tail nociception and tail paresis or paralysis).

Data extracted from the medical records included species, breed, body weight, age, sex, affected limb, cause of the injury, days elapsed between the onset of neurological signs and clinical examination and EDX, diagnostic imaging used, results of clinical and EDX evaluations. The neurological examination findings recorded were: ability to actively extend and flex the stifle and hock during ambulation and spinal reflexes assessment; proprioception, evaluated with proprioceptive placing, hopping, and, in small dogs, visual or tactile placing response tests; presence or absence of sensation in the autonomous zones of the tibial and peroneal nerves; and, the presence of a root signature (ie, lifting of the affected limb).¹³⁻¹⁵

The distribution of the lesion to the tibial nerve, the peroneal nerve or the common trunk of the sciatic nerve was defined according to the functional consequences ascertained at the clinical evaluation. In particular, a drop of the hock on weight bearing and hypoalgesia or analgesia of the caudal aspect of the leg region and plantar surface of the paw were present in lesions mostly involving the tibial nerve.^{1,13} Lesions mainly affecting the peroneal nerve were characterized by knuckling of the metatarsophalangeal joint, hyperextension of the hock, with decreased or absent flexion of the hock during withdrawal reflex, and hypoalgesia or analgesia of the dorsal and lateral aspects of the leg region and dorsal aspect of the paw.^{1,13} Finally, when both the tibial and peroneal nerves were similarly affected (ie, in lesions of the common trunk of the sciatic nerve), all of the previously reported clinical signs were present, associated with a decreased or absent ability to flex the leg if the lesion was proximal to the ramus muscularis of the sciatic nerve.^{1,13}

2.3 | Electrodiagnostic studies

The EDX were performed on all animals at least 7 days after the onset of clinical signs using 2 commercially available electrodiagnostic

devices (Myoquick, Micromed, Treviso, Italy; NeMus 2, EB Neuro S. p.A., Firenze, Italy), with the animal under general anesthesia. Rectal temperature was monitored. If necessary, heating pads were used to maintain patient temperature between 37°C and 38°C. The EDX recordings were performed by 2 experienced veterinary neurologists (E.B., Dip. ECVN, with over 10 years' experience in EDX, who performed 46/48 recordings and A.C., Dip. ECVN, with 5 years' experience in EDX, who performed 2/48 recordings).

Concentric needle electrodes were used (disposable concentric EMG needle electrode, Spes Medica s.r.l., Genova, Italy) for electromyography (EMG) recording. Monopolar needle electrodes (disposable monopolar needle electrode, Spes Medica s.r.l., Genova, Italy) were used for electrical stimulation and recording for the other EDX tests. For EMG, the ground electrode was placed on a bony prominence, whereas for the other EDX tests, it was placed between the stimulating and recording electrodes. For EMG, the recording needle was inserted into 3 to 5 different areas at 2 different depths. The following muscles of the affected limb were tested by EMG: the epaxial muscles innervated by the dorsal branches of the lumbar spinal nerves, the *quadriceps femoris* muscle innervated by the femoral nerve, the *semitendinosus* muscle innervated directly by the sciatic nerve via the ramus muscularis, the *tibialis cranialis* muscle innervated by the peroneal nerve, and the *gastrocnemius* and *plantar interossei* muscles innervated by the tibial nerve. Normal EMG recordings consisted of a brief burst of insertional activity due to stimulation of the muscle fibers by the needle during insertion, followed by the absence of spontaneous electrical activity except for physiological endplate potentials.^{9,16,17} Abnormal EMG was considered if spontaneous pathological activity (SPA) occurred, consisting mainly of fibrillation potentials, positive sharp waves and occasionally complex repetitive discharges (Figure 1).^{9,16,17} The SPA was graded from 0 to +4 for each muscle.¹⁶

After EMG, motor nerve conduction studies (MNCS) were performed on the sciatic-tibial and sciatic-peroneal nerves of the affected limb. Compound muscle action potential (CMAP) was recorded after supramaximal stimulation of the sciatic-tibial and sciatic-peroneal nerves with rectangular pulses of 0.1 ms. For the sciatic-tibial nerve, the active recording needle was placed in the *plantar interossei* muscle and the reference needle was placed SC distally on the plantar surface of the hind paw. For the sciatic-peroneal nerve, the active recording electrode was placed in the *tibialis cranialis* muscle and the reference electrode on its distal tendon.¹⁸⁻²⁰ Proximal stimulation of the sciatic-tibial and sciatic-peroneal MNCS was performed at the level of the trochanteric fossa.¹⁸⁻²⁰ Distal stimulation of the sciatic-tibial MNCS was performed by positioning the 2 electrodes over the tarsus.¹⁸⁻²⁰ Distal stimulation of the sciatic-peroneal MNCS was performed by positioning the stimulating needles at the stifle.¹⁸⁻²⁰ The 2 electrodes were placed 10 to 20 mm apart, with the cathode distal to the anode. The CMAP represents the sum of the action potentials of the fibers activated by the nerve impulse, and it is normally displayed as a single biphasic waveform with both a positive and a negative deflection (Figure 2A).¹⁸⁻²⁰ When recordable, CMAP amplitudes were measured from the highest negative peak to the highest positive peak. If CMAP was polyphasic and prolonged, pathological temporal dispersion was recorded (Figure 2B).¹⁸⁻²⁰ Conduction block was recorded if there was a decrease of >50% in the proximal-to-distal CMAP amplitude (Figure 2B).⁹ Motor nerve conduction velocity (MNCV) was calculated by dividing the distance between the proximal and distal stimulation points (in mm) by the difference between the proximal and distal CMAP latency (in ms; ie, the time between stimulus and first deflection of CMAP).²⁰

Tibial nerve F-wave assessments on the affected limb were performed in some patients and their presence or absence was recorded

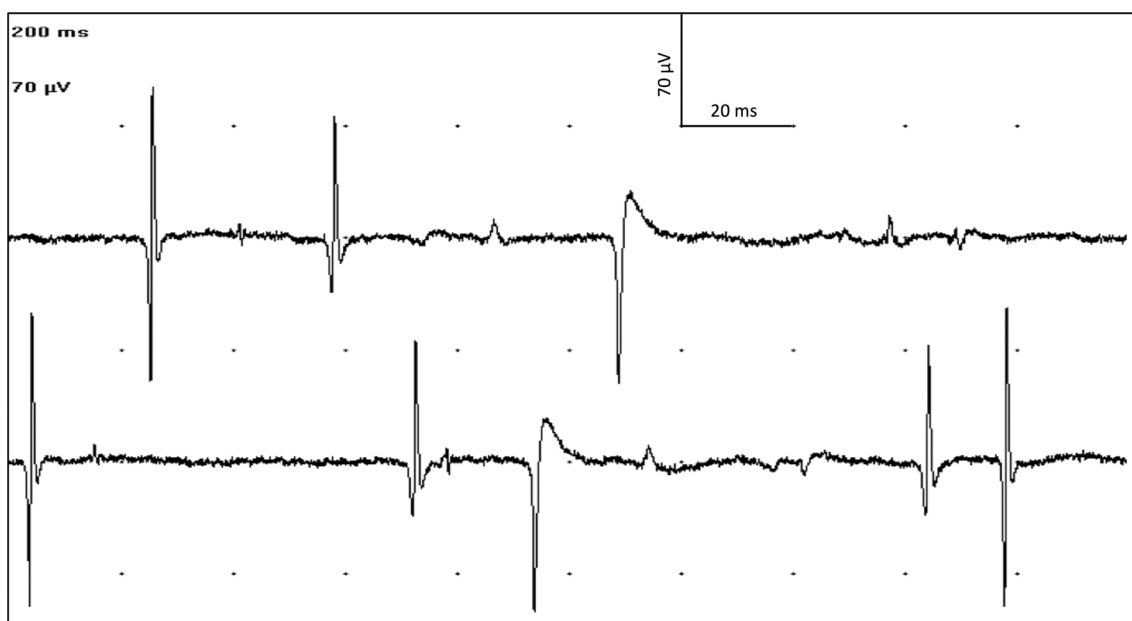


FIGURE 1 Electromyography (EMG) of the *tibialis cranialis* muscle of dog N. 7 showing 6 fibrillation potentials and 2 positive sharp waves.

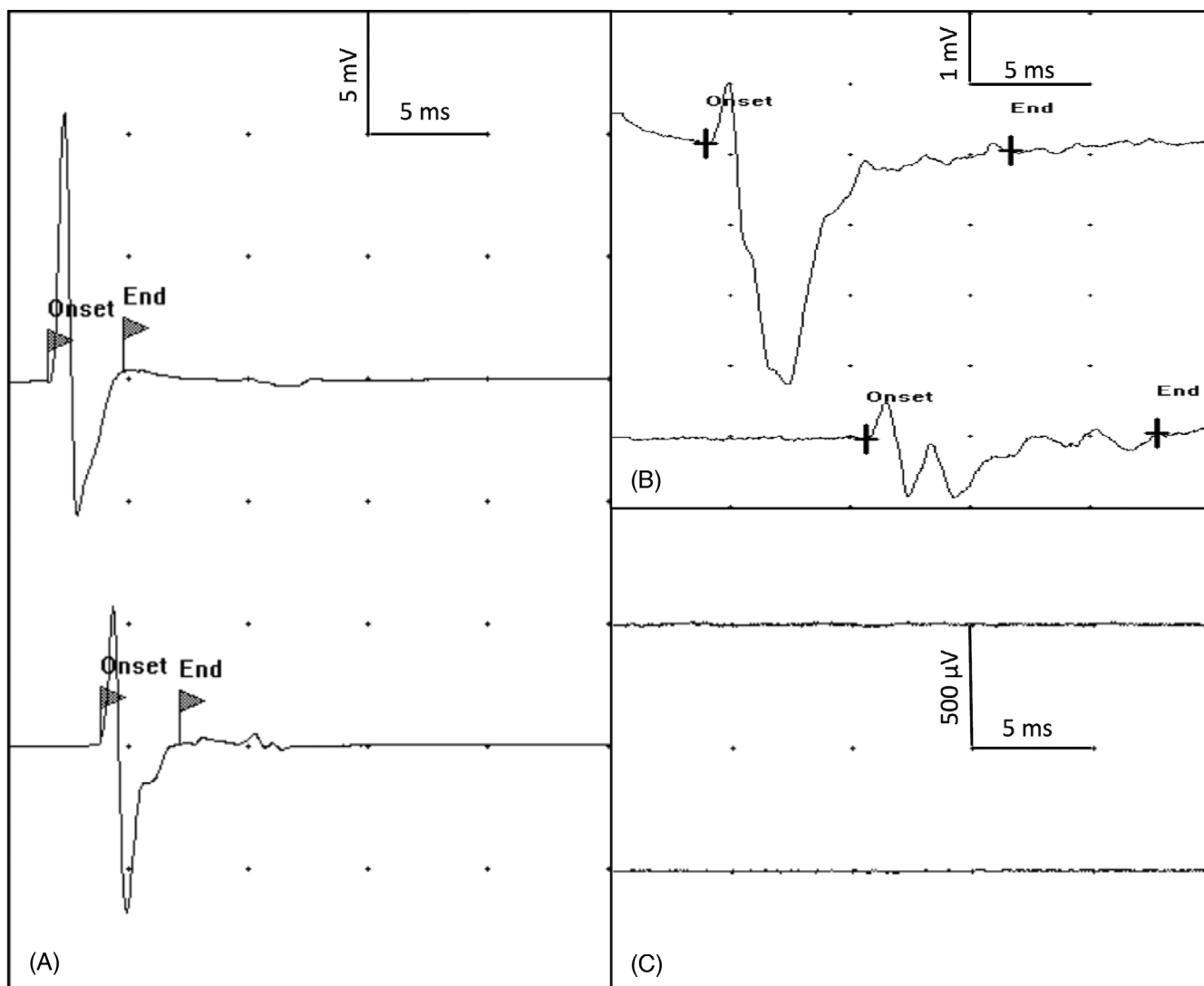


FIGURE 2 Motor nerve conduction studies (MNCS) of sciatic-tibial nerve. Upper tracing: stimulation at the hock; lower tracing: stimulation at the trochanteric fossa. In A, MNCS of a normal dog, conduction velocity (CV): 65.9 m/s. In B, MNCS of dog N. 30 showing reduced compound muscle action potential (CMAP) amplitudes, and the presence of conduction block and temporal dispersion, CV: 54.5 m/s. In C, MNCS of dog N. 15 showing absent CMAP.

(Figure 3).^{10,21} Specific details on the execution and recording of the F-waves are reported in File S1.

Sensory nerve conduction studies (SNCS) of the tibial and peroneal nerves of the affected limb were performed,²² and their presence (Figure 4A) or absence (Figure 4B) was recorded. The stimulating needles were inserted SC in the autonomous sensory area of the tibial nerve (plantar surface of the paw) or of the superficial branch of the peroneal nerve (dorsal surface of the paw). For recording SNCS of both nerves, the needles were left in the same position as for distal stimulation of MNCS.²² The stimulation intensity was set as high as possible without provoking muscle artifact. Recordings were digitally averaged until a sensory nerve action potential (SNAP) characterized by an initial small positive wave followed by a larger negative wave was detected (Figure 4A). If a potential indicative of a SNAP was obtained, the test was repeated to check the reproducibility of the potential.²²

The cord dorsum potential (CDP) was elicited in some patients and its presence (Figure 5A) or absence (Figure 5B) was recorded.²³ When performed, the presence (Figure 6A) or absence (Figure 6B) of motor-evoked potentials (MEP) was reported.¹⁰ Specific details on the execution and recording of both CDP and MEP are reported in File S1.

2.4 | Questionnaire

Owners were interviewed by telephone to obtain follow-up information at least 6 months after the trauma. The questionnaire included questions about the type of trauma, signs of neuropathic pain, treatment (physiotherapy, surgery, amputation) and outcome. We also collected information on owner perception of the animals' quality of life (QoL; File S2).

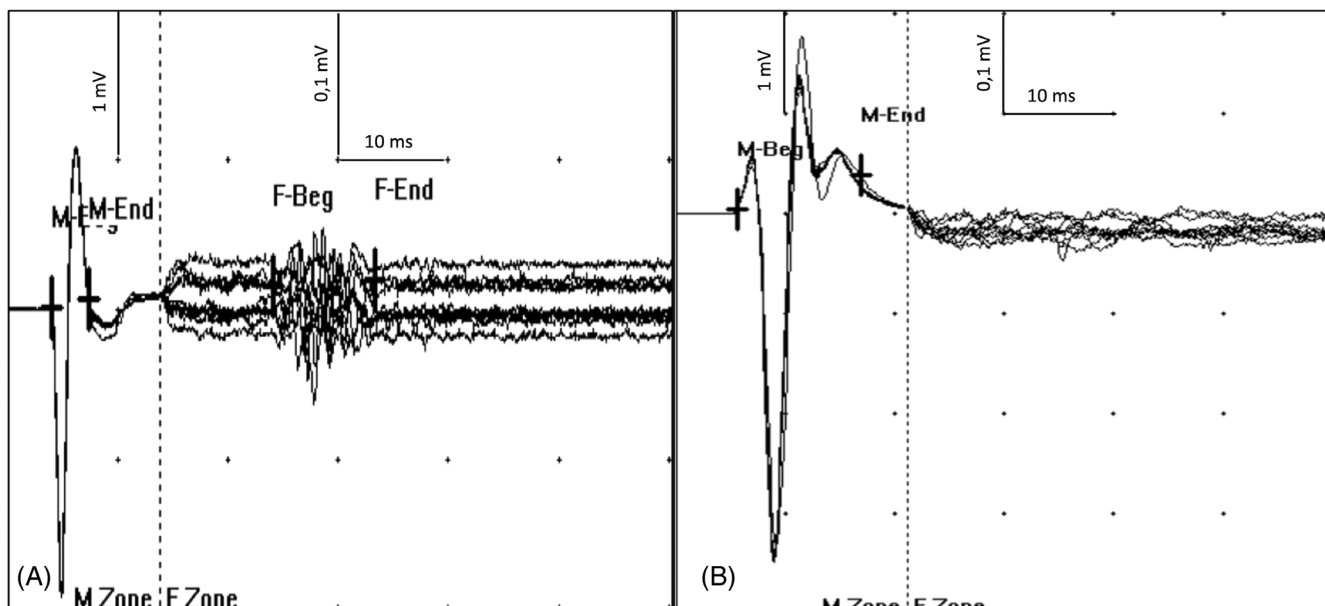


FIGURE 3 F-waves. In A, F-waves of the tibial nerve of dog N. 32 showing the presence of F-waves. In B, absence of F-waves in the tibial nerve of cat N. 5.

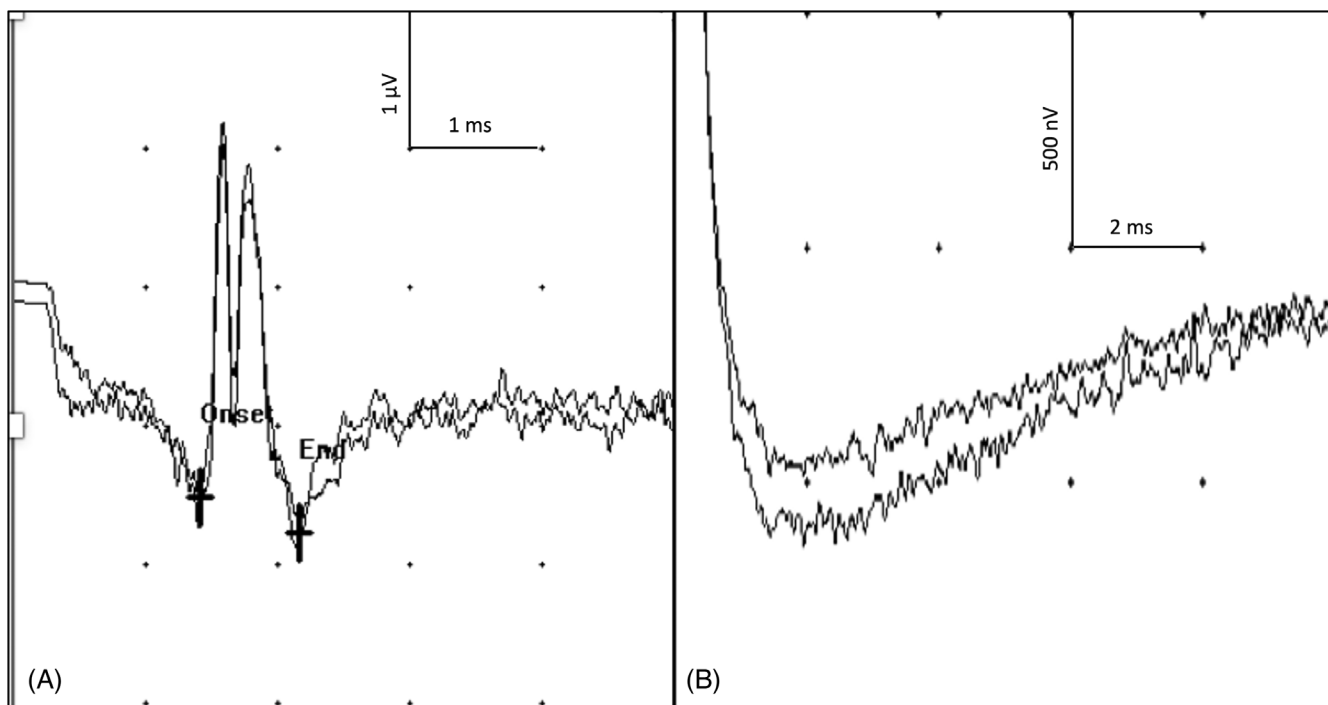


FIGURE 4 Sensory nerve conduction study (SNCS). In A, SNCS of the tibial nerve of cat N. 1: a sensory nerve action potential (SNAP) is present. In B, SNCS of the peroneal nerve of dog N. 18: no SNAP is recordable.

2.5 | Outcome

Outcome information was based on neurological reassessment and questionnaires. If the owner was unable to bring the animal for re-examination, a video of the patient's gait was requested if necessary to clarify limb functionality. The outcome was defined as negative if patients did not recover from SNI in terms of motor

function, leading to 1 of the following: (a) arthrodesis as a limb-salvaging procedure; (b) amputation of the affected limb; or (c) euthanasia on request of the owner because of inability to manage the pet with the condition or suggested by the clinician because of the severity of secondary lesions. In all other cases, the outcome was deemed positive even if limb function was improved rather than fully restored.

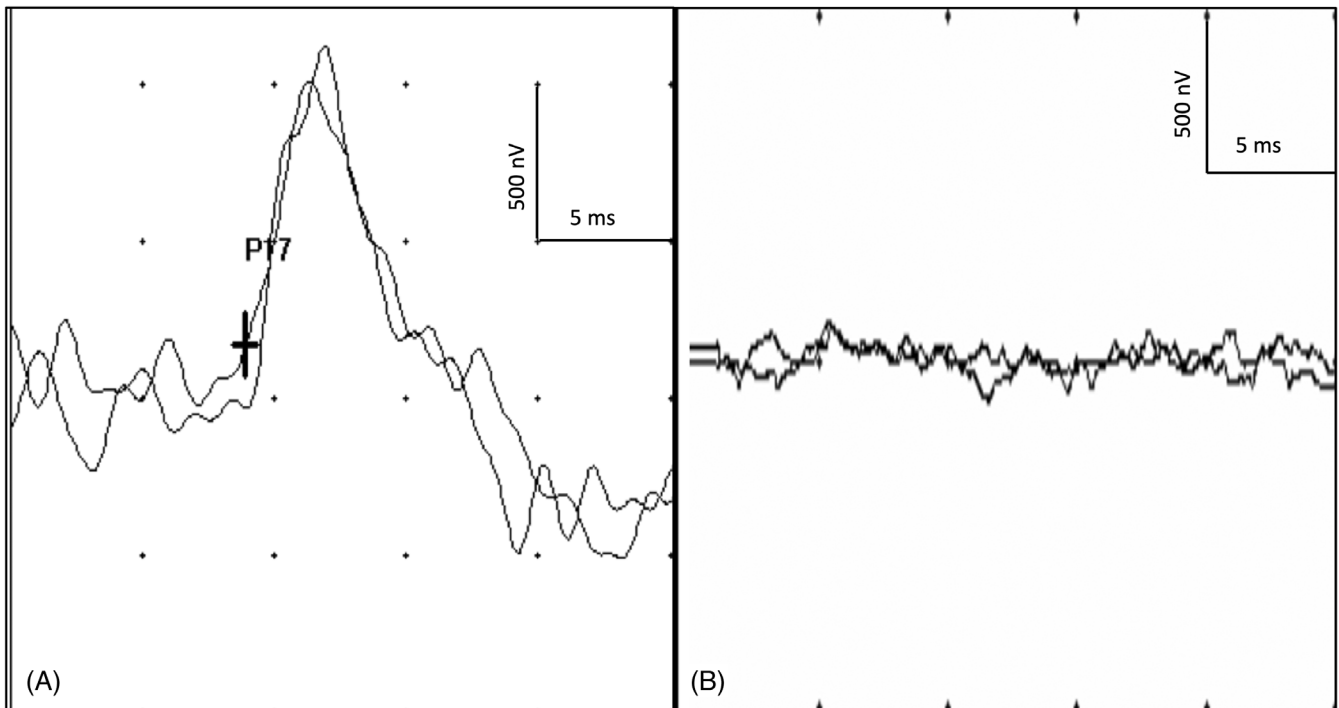


FIGURE 5 Cord dorsum potential (CDP) recordings. In A, a cord dorsum potential recorded in dog N. 7. In B, no cord dorsum potential recordable in dog N. 10.

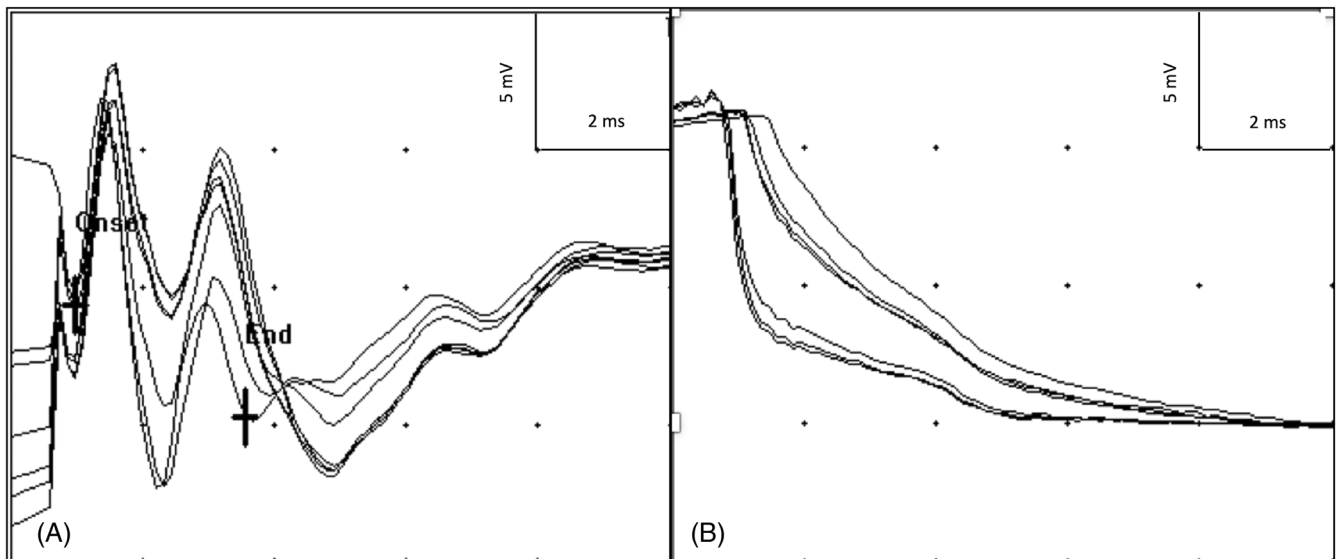


FIGURE 6 Motor-evoked potentials (MEP) of the *tibialis cranialis* muscle after stimulation of the sciatic nerve. In A, normal potentials in the normal limb of cat N. 3. In B, absence of potentials in the affected limb in the same cat.

2.6 | Statistical analysis

All data were recorded on an electronic spreadsheet (Microsoft Excel© for MAC, v. 16.58, Albuquerque, New Mexico) before being imported into dedicated software for statistical analysis (Prism 8 for MacOS, v. 8.2.0, GraphPad Software Inc., La Jolla, California; JMP Pro, v. 16.0, SAS Institute, Cary, North Carolina; IBM SPSS, v. 26.0, IBM,

Endicott, New York). Continuous data were tested for normality using the Shapiro-Wilk's *W* test. Signalment and clinical data are reported as number (percentage) and mean \pm SD or median (range), depending on the categorical or continuous nature of the variables described and whether or not they were parametric.

The 2 species were pooled together because of the small number of cats in the sample, but the analysis was repeated within each

species because differences in CMAP values have been reported between the 2 species.^{24,25} Each clinical and EDX variable was tested as predictive of the outcome using a nominal logistic model and included in the subsequent stepwise multivariate model if $P < .10$. A stepwise procedure then was used to assess which variable could explain the outcome, as previously defined, using an automated procedure. Post hoc, receiver operating characteristic (ROC) curves were evaluated for continuous variables, considering the area under the curve (AUC) and the relative 95% confidence interval (CI) and evaluating the optimal cut-off value based on the Youden's index J . Sensitivity, specificity, and positive and negative predictive values (PPV and NPV, respectively) also were reported. In addition, a Mann-Whitney's U test was used to evaluate differences between the 2 sub-groups (ie, positive vs negative outcome).

A chi-squared test was used for categorical variables. Contingency tables and Cohen's kappa agreement were applied to study the correlation between clinical and EDX localization.

Finally, for dogs, we tested whether the days elapsed were significantly different between the outcomes for CMAP = 0 and again for the CMAP cut-off amplitude identified, using a pooled Student's t test or a Mann-Whitney U test, according to data distribution.

3 | RESULTS

3.1 | Sample population and clinical evaluation

Forty-eight patients were included in the study, of which 38 (79%) were dogs and 10 (21%) were cats. Breeds of dog are recorded in Figure S1. Cats were mostly European Shorthair (8, 80%) and 1 each (10%) of Chartreux and British Shorthair. No statistics were applied to the breed distributions, which were considered consistent with the breeds commonly seen at the included institutions.

Dogs were 52 ± 44 (range, 4-192) months old and weighed 22.3 ± 11.4 (range, 4.9-49.1) kg; cats were 73 ± 46 (range, 12-156) months old and weighed $3.8 \pm .4$ (range, 3.0-4.5) kg. There were 18 (47%) female dogs and 20 (53%) male dogs; there were 7 (70%) female cats and 3 (30%) male cats.

In dogs the right hind limb was affected in 21 (55%) cases and the left in 17 (45%); in cats the distribution was even between the right and left hind limbs. The reported causes of the clinical signs are summarized in Table 1. Diagnostic imaging tests were not performed or were not available in 4 (8%) patients, 2 dogs, both with lesions caused by bites, and 2 cats, 1 with signs caused by bite lesions and the other because of an IM injection. Of the remaining patients (44), 26 (59%) had plain radiographs taken, 10 (23%) had both radiography and ultrasonography performed, 3 (7%) had ultrasonography, 3 (7%) had magnetic resonance imaging, and 2 (4%) underwent all 3 imaging modalities.

Results of the neurological examination for the 2 species are summarized in Table 2. For dogs, the mean time from the onset of clinical signs until EDX evaluation was 67 ± 65 (range, 7-300) days; in cats, it was 65 ± 108 (range, 7-365) days. The EMG and MNCS of the sciatic-

TABLE 1 Causes of sciatic nerve injury recorded in the 2 species.

Injury	Dog	Cat
Trauma involving the pelvis	6 (16%)	5 (50%)
Bites	9 (24%)	1 (10%)
Surgery	7 (18%)	
TPLO		
Modified retinacular imbrication		
Removal intramedullary pin		
TPO		
DPO		
Surgery for femoral fracture	5 (13%)	2 (20%)
Trauma involving the limb	5 (13%)	
Surgery for pelvic fracture	3 (8%)	
Surgery for pelvic and femoral fracture	3 (8%)	
Intramuscular injection		2 (20%)

Abbreviations: DPO, double pelvic osteotomy; TPLO, tibial plateau leveling osteotomy; TPO, triple pelvic osteotomy.

tibial and sciatic-peroneal nerves were performed in all patients. All animals had SPA on EMG in at least 1 of the muscles of the affected limb; results of the EMG are summarized in Table 3. The median values of CMAP amplitudes are shown in Table 4. The CMAP recordings showed absence of action potentials (Figure 1C) at both the proximal and distal stimulation sites of both the tibial and peroneal nerves in 6/38 (16%) dogs and 1 cat. Specific results on temporal dispersion are summarized in Table S1. Conduction blocks were recorded in 8/33 (24%) dogs and 1 cat, all pertaining to the tibial nerve.

The MNCV could not be measured because of absence or extreme reduction of the CMAP amplitude in the tibial nerves of 12/38 (32%) dogs and 1 cat, and in the peroneal nerves of 22/38 (58%) dogs and 4/10 (40%) cats. The median values of MNCV, categorized as pathologic or physiologic, are shown in Table 5. Specific results for the SNCS for the tibial and peroneal nerves, F waves and CDP are summarized in Table S2. The MEP was performed in 6/38 (16%) dogs and 1 cat. It was present in 3 patients and absent in 4. A significant association ($P = .01$) was found between the clinical and EDX localization (Table S3) but with low agreement ($\kappa = .36$, $P = .0002$).

3.2 | Outcome

Outcome was available for 32/38 (84%) dogs and 9/10 (90%) cats. Nine of 32 (28%) dogs and 1 cat had a negative outcome. Eight dogs and 1 cat recorded as having a negative outcome underwent limb amputation, and the other dog was euthanized for worsening of its clinical condition.

Clinical and EDX variables significantly associated with outcome are summarized in Table 6. Nonsignificantly associated clinical and EDX variables are summarized in Table S4. The CMAP recordings of the tibial nerve with proximal stimulation in dogs were the only

Test	Dogs (N = 38)		Cats (N = 10)	
	Present	Decreased/Absent	Present	Decreased/Absent
Stifle flexion	34 (89%)	4 (11%)	7 (70%)	3 (30%)
Hock extension	8 (21%)	30 (79%)	0 (0%)	10 (100%)
Hock flexion	7 (19%)	31 (81%)	1 (10%)	9 (90%)
Proprioception	9 (24%)	29 (76%)	3 (30%)	7 (70%)
Tibial sensitivity	28 (74%)	10 (26%)	5 (50%)	5 (50%)
Peroneal sensitivity	19 (50%)	19 (50%)	5 (50%)	5 (50%)
Root signature	5 (13%)	33 (87%)	0 (0%)	10 (100%)
Predominant involvement	Dogs (N = 38)		Cats (N = 10)	
Tibial nerve	6 (16%)		2 (20%)	
Peroneal nerve	14 (37%)		6 (60%)	
Sciatic nerve (common trunk)	18 (47%)		2 (20%)	

Note: The presence or absence of the tested reflexes, proprioception, sensitivity, and root signature are reported as number of patients and percentage of the total within each species. The predominant involvement of the sciatic-tibial, sciatic peroneal, or common trunk sciatic nerves defined according to the clinical evaluation are reported as number of patients and percentage of the total within each species.

TABLE 3 Results of the EMG recordings, reported as the number of patients and percentage of the total within each species for each spontaneous pathologic activity (SPA) grade.

Species	SPA grade	Quadriceps m. (N, %)	Semitendinosus m. (N, %)	Tibialis cranialis m. (N, %)	Gastrocnemius m. (N, %)	Plantar interossei m. (N, %)
Dog (n = 38)	0	30 (79%)	21 (56%)	5 (13%)	2 (5%)	2 (5%)
	+1	3 (8%)	5 (13%)	1 (3%)	2 (5%)	0 (0%)
	+2	2 (5%)	2 (5%)	2 (5%)	7 (19%)	7 (19%)
	+3	2 (5%)	8 (21%)	11 (29%)	14 (37%)	12 (31%)
	+4	1 (3%)	2 (5%)	19 (50%)	13 (34%)	17 (45%)
Cat (n = 10)	0	9 (90%)	5 (50%)	1 (10%)	0 (0%)	0 (0%)
	+1	0 (0%)	2 (20%)	1 (10%)	1 (10%)	1 (10%)
	+2	0 (0%)	2 (20%)	2 (20%)	1 (10%)	2 (20%)
	+3	1 (10%)	1 (10%)	2 (20%)	4 (40%)	2 (20%)
	+4	0 (0%)	0 (0%)	4 (40%)	4 (40%)	5 (50%)

Note: SPA included fibrillation potentials, positive sharp waves, and complex repetitive discharges, and was graded according to Ref. [17]. 0 = physiological electromyographic recording.

Abbreviations: m., muscle; SPA, spontaneous pathologic activity.

TABLE 4 Median (range) CMAPs amplitudes for the proximal and distal stimulation sites of the tibial and peroneal nerves in the 2 species.

	Proximal tibial nerve	Distal tibial nerve	Proximal peroneal nerve	Distal peroneal nerve
Dogs (n = 38)	1.2 (0.0-8.3)	1.6 (0.0-16.1)	0.2 (0.0-15.7)	0.3 (0.0-14.5)
Cats (n = 10)	2.1 (0.0-22.6)	3.5 (0.0-18.9)	1.2 (0.0-13.8)	0.7 (0.0-25.0)

independent predictor of outcome in the multivariable analysis. The results of the ROC curve evaluation for CMAPs are summarized in Table 7 and Figure 7. The ROC analysis was repeated for dogs within 90 days after trauma¹¹; 25 dogs were included in this further analysis, and the results are summarized in Table 7. At CMAP = 0, the days elapsed from the beginning of the clinical signs and the EDX

examination were not different ($P = .81$) between positive (54 ± 47) and negative (28 ± 28) outcomes in dogs. Similarly, no differences ($P = .78$) were detectable at CMAP = 1.45 mV between positive (35; 9-150 days) and negative (40; 20-210 days) outcomes in dogs. The only independent predictor of a positive outcome in cats was the absence of SPA 3+ at the EMG evaluation of the quadriceps muscle.

TABLE 2 Results of the clinical neurological examination.

TABLE 5 Median (range) motor nerve conduction velocity (MNCV) for the tibial and peroneal nerves, categorized as physiological or pathological, in the 2 species.

	Physiological		Pathological	
	Tibial nerve	Peroneal nerve	Tibial nerve	Peroneal nerve
Dogs (n = 26 T.n.; n = 16 P.n.)	59.9 (53.6-113.0) ^a	76.9 (68-94.8)	46.9 (20-54.5)	45.8 (26.7-53.8)
Cats (n = 9 T.n.; 6 P.n.)	92.9 (71.4-104.5)	104.8 (100-116.7)	54 (53-55)	48 ^b

Abbreviations: P.n., peroneal nerve; T.n.: Tibial nerve.

^aIncludes a 5-months-old puppy in which a low motor nerve conduction velocity is considered physiologic.

^bTwo subjects with the same MNCV.

TABLE 6 Variables significantly associated to the outcome at the univariate and multivariable nominal logistic regression.

Variable	Univariate	OR (95% CI)	Positive outcome	Negative outcome	Difference	Multivariable
Dogs						
Hock flexion	.03	0 (0-1.3)	pres. 17 abs. 6	pres. 9 abs. 0	.15 (n.s.)	.17 (n.s.)
Hock extension	.06	0 (0-1.8)	pres. 18 abs. 5	pres. 9 abs. 0	.29 (n.s.)	.33 (n.s.)
Tibial n. CMAP proximal	.01	2.2 (1.0-5.1)	(2.4; 0-22.6)	(0; 0-1.3)	.02*	.01*
Cats						
SPA <i>quadriceps</i> m.	<.0001	0.0 (0.0-1.1)	SPA +3 0 abs. 8	SPA +3 1 abs. 0	.003*	.01*
SPA <i>semitendinosus</i> m.	.10	n.a.	SPA +3 0 SPA +2 2 SPA +1 1 abs. 5	SPA +3 0 SPA +2 0 SPA +1 1 abs. 0	.03*	.99
Peroneal n. CMAP distal	.06	n.a.	2.1 (0-22.6)	0 ^a	.32 (n.s.)	.99
Tibial n. sensitivity	.06	n.a.	pres. 7 abs. 1	pres. 0 abs. 1	.04*	.99

Note: According to the statistical test, the odds ratio (OR) and relative 95% confidence intervals were reported. Number of patients within the outcome categories is reported for categorical variables, and median (range) for continuous variables. The *P*-value of the difference between the outcome categories has been reported.

Abbreviations: 95% CI, 95% confidence interval; abs., absence; CMAP, compound muscle activation potential; m., muscle; n., nerve; n.a., nonassessable; n.s., nonsignificant; OR, odds ratio; pres., presence.

^aSingle cat with negative outcome.

*Statistically significant.

TABLE 7 Results of the receiver operator characteristic (ROC) curve analysis for the CMAP recordings of the tibial nerve with proximal stimulation in dogs.

Variable	ROC curve (AUC; 95% CI; sig.)	Cut-off	Youden's <i>J</i>	Sens., Spec., PPV, NPV
Dogs				
Tibial n. CMAP proximal	0.72 (0.59-0.86) <i>P</i> = .03*	1.45 mV	0.56	58%, 100%, 1.0, 0.43
Dogs (within 90 days)				
Tibial n. CMAP proximal	0.68 (0.48-0.83) <i>P</i> = .01*	1.45 mV	0.53	53%, 100%, 1.0, 0.50

Note: The cut-off value, the corresponding Youden's index (*J*) and the value's sensitivity, specificity, negative, and positive predictive values are reported. Abbreviations: AUC, area under the curve; CI, confidence interval; n., nerve; NPV, negative predictive value; PPV, positive predictive value; ROC, receiver operator characteristic; Sens., sensitivity; Spec., specificity.

*Statistically significant.

3.3 | Quality of life

The questionnaire was completed by 38 owners, 31 owning a dog and 7 a cat. The QoL of their pet was perceived as poor in 3 cases, fair in 4, good in 11 and excellent in 13. Regarding their own QoL, owners reported that it had worsened in 13 cases, remained the same in 24 cases and improved in 1 case. When asked if and how their relationship with their pets had changed, 22 reported no change and 16 reported improvements. Outcome did not affect the perception of the QoL of the patient (*P* = .57), the owner (*P* = .68), or their

relationship (*P* = .54). Similarly, whether the pet lived outdoors, indoors, or both did not affect perceptions of the QoL for the patient (*P* = .91), the owner (*P* = .29), or their relationship (*P* = .76).

4 | DISCUSSION

Our primary aim was to describe the causes of SNI in a cohort of dogs and cats. The most common cause of SNI was trauma, particularly to the pelvis and the hind limbs. The higher prevalence of this cause

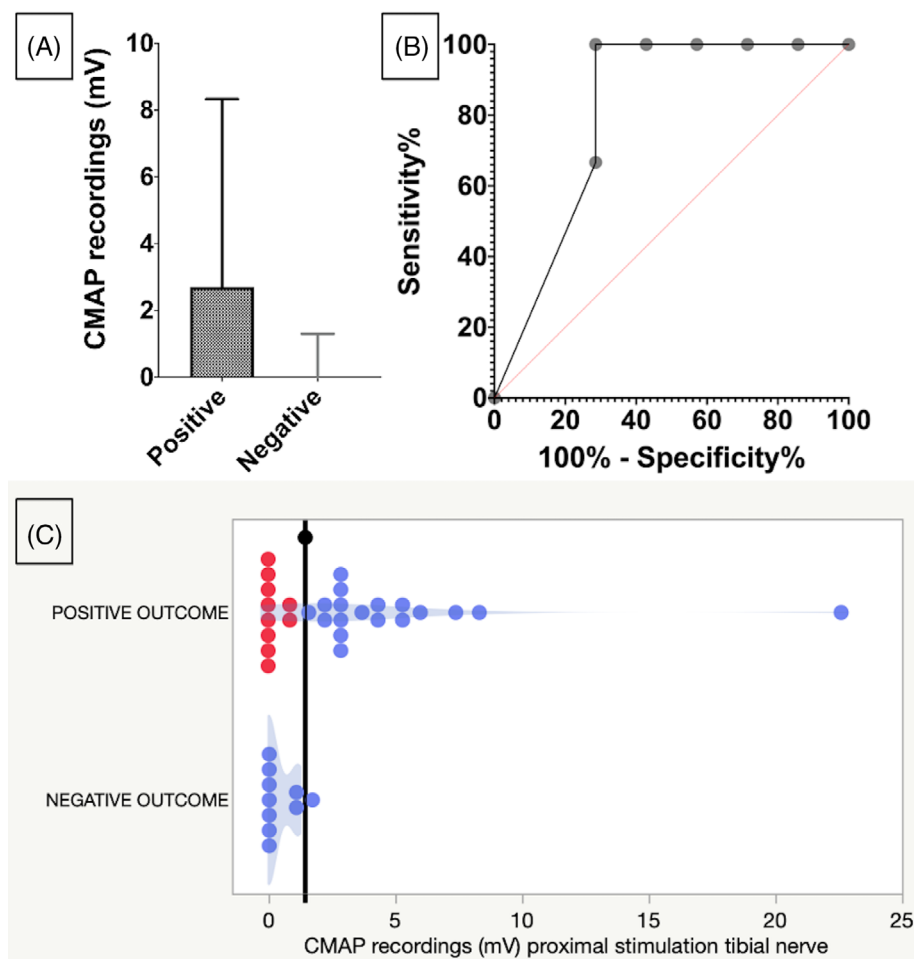


FIGURE 7 Graphic representation CMAP recordings at the proximal stimulation site of the tibial nerve in dogs. In A, median and range of the CMAP values recorded in the positive and negative outcome groups. In B, receiver operator characteristic (ROC) curve for the CMAP recorded values in the positive and negative outcome groups. In C, graphic representation of the cut-off value—black vertical line—considering the distribution of CMAP recorded values in the positive and negative outcome groups; the red dots represent the patients with a positive outcome with CMAP values lower than the cut-off value identified.

appears to be consistent with other studies. Indeed, the pelvis and extremities represented the most affected regions in traumatized small animals.²⁶⁻²⁸ Therefore, it is very important to establish the prognosis and the optimal therapeutic approach for these patients.²⁹ The second most common cause was complications from surgery for pelvic or femoral fractures and other orthopedic surgery of the pelvis, femur, and femoro-tibial joint, similar to previous reports.^{1,2} Sciatic nerve injury as a complication of total hip replacement, double pelvic osteotomy, and stabilization of femoral fractures has been reported.³⁰⁻³³ In general, the risk of SNI is considered to be higher in femoral and pelvic fracture surgery because of the limited visibility of the sciatic nerve as a consequence of its deep location.² Hence, an accurate neurological evaluation always should be performed before surgery for pelvic and femoral fractures.²⁹ Bites (21%) and injections (4%) represented other less common causes of SNI. In all 9 dogs with SNI caused by bites, the wound was the result of a wild boar attack. Penetrating wounds inflicted by wild boars represented the third most common cause of SNI in dogs in our study. As expected, this specific cause has only been reported in countries where wild boar hunting is practiced.³⁴ In a retrospective study, wild boar attacks in dogs caused penetrating wounds affecting hind limbs in 13% of the cases.³⁴ The only SNI caused by a bite in the cat in our study was associated with a dog attack. Finally, IM injections have been reported to cause SNI in

dogs and cats.^{1,2,35} Nerve damage has been associated with direct trauma by the needle, the injected substance, or even the scar resulting from irritating drugs.^{12,36,37} In our sample, injection lesions were found only in cats, accounting for 20% of cases. Because of the relatively high risk of damaging the sciatic nerve with injections in the *biceps femoris* muscle in cats, choosing the *quadriceps* muscle mass has been recommended.³⁸

Regarding ancillary tests, radiographs were obtained in most patients (86%), often before referral to the neurologist. Ten patients underwent radiography in association with ultrasound neurography, a versatile technique with high specificity that can be used to evaluate nerve integrity. Ultrasonography can be used to assess the localization of trauma in the presence of a foreign body, perilesional scar, neuroma, or nerve stump, as well as neuritis caused by injection.³⁹⁻⁴¹ Magnetic resonance imaging also was used in combination with ultrasound neurography and alone in 3 patients. It is routinely performed in human medicine, in association with EDX.^{42,43}

Regarding the clinical neurological assessment, ability to actively flex and extend the tarsal joints was significantly associated with a positive outcome in dogs in our study. In contrast, the absence of nociception of the tibial and peroneal nerves was not associated with outcome, different from previous reports about dogs with SNI.¹ Absence of nociception is a well-known sign of guarded or poor

prognosis for recovery of ambulation in spinal cord injury. In our study, absence of nociception was linked to peripheral nerve injury because spinal cord injury was excluded by clinical evaluation and diagnostic imaging. Fibers involved in nociceptive transmission are very resistant because of their small diameter, deep location, and wide distribution in the spinal cord. Therefore, absent nociception indicates functional spinal cord transection.⁴⁴ On the other hand, peripheral nerve fibers can regenerate. Thus, even without motor and sensory function at the neurological examination, recovery of limb function is deemed possible after injury without neurotmesis.¹ In our cases, the severe reduction or absence of motor activity of the extensors and flexors of the tarsal joints found in many animals with a poor prognosis may indicate axonotmesis or neurotmesis. The different involvement of sensory and motor fibers has been reported previously in 2 dogs and 1 cat with sciatic nerve dysfunction that, despite having absent nociception, had a fair prognosis. In the same case series, 2 other dogs with preserved nociception had a poor outcome.¹⁰ In cats in our case series, no correlation was found between neurological findings and outcome, probably because of the study's limited number of cats.

According to the EDX findings, SPA was present on EMG in at least 1 muscle of the affected limb in all patients. Given the history, neurological findings and abnormalities found on the other EDX tests, a myopathy was unlikely to have caused SPA on EMG in these cases. This finding suggested the presence of denervation because of axonotmesis or neurotmesis. Neurapraxia was unlikely because this condition should not be associated with the presence of SPA.⁴⁵ In fact, in neurapraxia, there should be no axonal damage and no signs of denervation, especially several days after the injury.⁴⁵

In some cases, the pathological temporal dispersion of CMAP and conduction block is probably related to nerve injury. The normal motor nerve conduction velocity found in most nerves is not surprising, given that nerve injury is associated with axonal loss.⁴⁶ Conduction velocity was decreased when a substantial number of nerve fibers, including the fastest fibers, were damaged. In the dogs, there was a significant correlation between the CMAP values recorded at the tibial nerve MNCS and outcome. Specifically, the amplitude of CMAP during proximal sciatic-tibial nerve stimulation was higher in dogs with a positive outcome. These findings are consistent with the results of neurological evaluation, which identified reflex motor function as a predictor of outcome. The tibial nerve activates muscles that extend the tarsus and flex the digits, and, together with the femoral nerve, is essential for weight-bearing.³ The common peroneal nerve supplies the muscles that flex the tarsus and extend the digits.³ When damaged, the main neurological sign is knuckling of the foot. These functional aspects may explain the association between the amplitude of sciatic-tibial nerve CMAP recordings and outcome. However, in most cases with poor outcome, both nerves seemed severely affected. A cut-off for CMAP amplitude of 1.45 mV may help discriminate dogs more likely to have a good prognosis. Unfortunately, CMAP amplitudes <1.45 mV showed poor ability to predict negative outcome. Surgical intervention for traumatic SNI has been widely described, but decision-making remains to be tailored to the individual patient

according to clinical, imaging, and EDX results.⁴⁷⁻⁵¹ With or without surgical intervention, physiotherapy and the use of tarsus-foot orthosis might be suggested as soon as possible in veterinary patients regardless of predicted outcome.⁵²⁻⁵⁴ Indeed, physiotherapy would help maintain muscle tone and avoid fibrosis, whereas the use of orthosis could stabilize the hock joint and prevent cutaneous lesions arising from dragging the hindlimb.⁵²⁻⁵⁴ When paresthesia and auto-mutilation occur, or in absence of clinical improvement, hindlimb amputation should be considered. Hence, patients with CMAPs <1.45 mV should be frequently re-evaluated either clinically or with EDX, or both. The potential ability of CMAP amplitude to help predict functional recovery is not surprising. It reflects the number of muscle cell fibers activated by nerve stimulation and is an indirect measure of the number of functional motor nerve fibers.¹⁶ The MNCS and MEP are considered valuable for predicting the prognosis of nerve injury.¹⁰ Both tests objectively assess motor function by stimulating motor pathways and recording CMAP produced by muscles of the limbs.

In cats, an association between the results of EMG, MNCS, and CDP and outcome was detected. The presence of SPA on EMG in the *semitendinosus* and *quadriceps* muscles and the inability to record CDP were associated with negative outcome. The presence of SPA in the *quadriceps* indicated the presence of concomitant involvement of the ipsilateral femoral nerve. Negative outcome of the cat with these EMG findings is probably related to monoplegia of the affected limb because of concomitant femoral involvement. The association between the *semitendinosus* muscle SPA and outcome may be related to the involvement of the proximal portion of the sciatic nerve. The CDP is a sensory potential arising in the caudal lumbar spinal cord. Abnormalities of the CDP also may indicate a proximal lesion.²³ The amplitude of CMAP recordings from the MNCS of the sciatic-peroneal nerve with distal stimulation also was correlated with outcome. The higher the amplitude, the higher the chance of a positive outcome, considering that only 1 cat in our sample had a negative outcome. These results are not surprising considering that proximal lesions are those associated with the worst prognosis.^{2,7,8} It could be speculated that excluding animals with signs of sacral trauma from our case series decreased the number of cats, particularly those with severe traumatic events. Pelvic trauma and related surgeries are the leading cause of SNI in cats. Exclusion of the cats with signs of sacral involvement also had a possible influence on the outcome, which was positive in most cases. However, similar percentages of cats with a good or fair prognosis also have been reported in other case series.^{2,28}

Questionnaires were available for the majority of animals included in the study. Most owners rated their pet's QoL as fair, good, or excellent, regardless of the objective clinical outcome. The quality of the owner-animal relationship was perceived as unchanged or, more often, improved. Similar results have been reported previously for brachial plexus injuries.⁴ Neuropathic pain has been reported to affect approximately 50% of humans with peripheral nerve injury, up to 100% in nerve root avulsions.⁵⁵ If present in our patients, neuropathic pain did not substantially affect QoL. Furthermore, negative outcome did not substantially affect the animals' QoL. The owners of 13 animals (34%) felt that SNI decreased their own QoL. The physical

and psychological impact of their pets' permanent motor impairment is likely to be responsible for this change in their QoL, even though limb amputation does not appear to negatively affect QoL in both our own and previous studies.⁵⁶

The limitations of our study are primarily a consequence of its retrospective nature. To limit the negative impact of missing data on the quality of the study, we included only animals with medical records including all of the variables of interest, an EDX including at least EMG and MNCS of both sciatic-tibial and sciatic-peroneal, and a minimum follow-up of 12 months. We also excluded all cases with concomitant sacral or cauda equina involvement or both, because the signs associated with these radicular injuries, particularly neurogenic urinary retention, may negatively affect outcome. These narrow inclusion criteria may have decreased sample size, especially for the cats. Another important limitation is the use of questionnaires.^{57,58} To avoid further decreasing the number of cases, we did not exclude animals that had EDX >90 days after injury, although this delay may have had an influence on SPA, EMG, and CMAP amplitudes in MNCS. However, we repeated the statistical analysis with only those patients tested within 90 days, and doing so did not affect the cut-off values of CMAP amplitudes.

In conclusion, our study shows that neurological examination and EDX findings may help predict long-term outcome in dogs and cats with SNI. The ability to predict the prognosis of limb function recovery in SNI is critical for the clinician to determine the optimal therapeutic approach.

ACKNOWLEDGMENT

The authors acknowledge the support of the article publication charge (APC) central fund of the University of Milan.

CONFLICT OF INTEREST DECLARATION

Authors declare no conflict of interest.

OFF-LABEL ANTIMICROBIAL DECLARATION

Authors declare no off-label use of antimicrobials.

INSTITUTIONAL ANIMAL CARE AND USE COMMITTEE (IACUC) OR OTHER APPROVAL DECLARATION

Authors declare no IACUC or other approval was needed.

HUMAN ETHICS APPROVAL DECLARATION

Authors declare human ethics approval was not needed for this study.

ORCID

Luigi Auletta  <https://orcid.org/0000-0002-1624-4240>

REFERENCES

- Gilmore DR. Sciatic nerve injury in twenty-nine dogs. *J Am Anim Hosp Assoc.* 1984;20(3):403-407.
- Forterre F, Tomek A, Rytz U, et al. Iatrogenic sciatic nerve injury in eighteen dogs and nine cats. *Vet Surg.* 2007;36:464-471.
- Hermanson JW, de Lahunta A, Evans HE. The spinal nerves. In: Evans HE, de Lahunta A, eds. *Miller's Anatomy of the Dog.* 5th ed. St. Louis, MO: Elsevier; 2020:748-752.
- Menchetti M, Gandini G, Bravaccini B, Dondi M, Gagliardo T, Bianchi E. Clinical, electrodiagnostic findings and quality of life of dogs and cats with brachial plexus injury. *Vet Sci.* 2020;7:101.
- Dewey CW, Talarico LR. Disorders of peripheral nervous system. In: Dewey CW, da Costa RC, eds. *Practical Guide to Canine and Feline Neurology.* 3rd ed. Ames, IA: John Wiley & Sons, Inc; 2016: 445-479.
- Menorca RMG, Fussell TS, Elfar JC. Nerve physiology mechanisms of injury and recovery. *Hand Clin.* 2013;29(3):317-330.
- Sulaiman W, Gordon T. Neurobiology of peripheral nerve injury, regeneration, and functional recovery: from bench top research to bedside application. *Ochsner J.* 2013;13(1):100-108.
- Nagappan PG, Chen H, Wang DY. Neuroregeneration and plasticity: a review of the physiological mechanisms for achieving functional recovery postinjury. *Military Med Res.* 2020;7:30.
- Cuddon PA. Electrophysiology in neuromuscular disease. *Vet Clin North Am Small Anim Pract.* 2002;32(1):31-62.
- Van Soens I, Struys MM, Van Ham LM. Muscle potentials evoked by magnetic stimulation of the sciatic nerve in unilateral sciatic nerve dysfunction. *J Small Anim Pract.* 2010;51(5):275-279.
- Troupel T, Van Caenegem N, Jeandel A, et al. Epidemiological, clinical, and electrophysiological findings in dogs and cats with traumatic brachial plexus injury: a retrospective study of 226 cases. *J Vet Intern Med.* 2021;35(6):2837-2845.
- Bennett D. An anatomical and histological study of the sciatic nerve, relating to peripheral nerve injuries in the dog and cat. *J Small Anim Pract.* 1976;17(6):379-386.
- Bailey CS, Kitchell RL. Cutaneous sensory testing in the dog. *J Vet Intern Med.* 1987;1(3):128-135.
- Tudury EA, de Figueiredo ML, Fernandes TH, et al. Evaluation of cranial tibial and extensor carpi radialis reflexes before and after anesthetic block in cats. *J Feline Med Surg.* 2017;19(2):105-109.
- de Lahunta A, Glass E, Kent M. The neurologic examination. In: de Lahunta A, Glass E, Kent M, eds. *de Lahunta's Veterinary Neuroanatomy and Clinical Neurology.* 5th ed. Philadelphia, PA: Elsevier; 2021: 531-546.
- Kimura J. Types of electromyographic abnormalities. In: Kimura J, ed. *Electrodiagnosis in Diseases of Nerve and Muscle Principles and Practice.* 4th ed. New York, NY: Oxford University Press; 2013:361-392.
- Harcourt-Brown TR, Granger NP, Fitzpatrick N, Jeffery ND. Electrodiagnostic findings in dogs with apparently painful lumbosacral foraminal stenosis. *J Vet Intern Med.* 2019;33(5):2167-2174.
- Lee AF, Bowen JM. Evaluation of motor nerve conduction velocity in the dog. *Am J Vet Res.* 1970;31:1361-1366.
- Walker TL, Redding RW, Braund KG. Motor nerve conduction velocity and latency in the dog. *Am J Vet Res.* 1979;40(10):1433-1439.
- van Nes JJ. An introduction to clinical neuromuscular electrophysiology. *Vet Q.* 1986;8(3):233-239.
- Poncelet L, Balligand M. Nature of the late potentials and F-ratio values in dogs. *Res Vet Sci.* 1991;51(1):1-5.
- Redding RW, Ingram JT, Colter SB. Sensory nerve conduction velocity of cutaneous afferents of the radial, ulnar, peroneal, and tibial nerves of the dog: reference values. *Am J Vet Res.* 1982;43(3):517-521.
- Cuddon PA, Delauche AJ, Hutchison JM. Assessment of dorsal nerve root and spinal cord dorsal horn function in clinically normal dogs by determination of cord dorsum potentials. *Am J Vet Res.* 1999;60(2):222-226.
- Malik R, Ho S, Church DB. A new method for recording and analysing evoked motor potentials from dogs. *J Small Anim Pract.* 1989;30: 13-19.
- Malik R, Ho S. Motor nerve conduction parameters in the cat. *J Small Anim Pract.* 1989;30:396-400.
- Kolata RJ. Trauma in dogs and cats: an overview. *Vet Clin North Am Small Anim Pract.* 1980;10(3):515-522.
- Johnson JA, Austin C, Breur GJ. Incidence of canine appendicular musculoskeletal disorders in 16 veterinary teaching hospitals from 1980 through 1989. *Vet Comp Orthop Traumatol.* 1994;7:56-69.

28. Jacobson A, Schrader SC. Peripheral nerve injury associated with fracture or fracture-dislocation of the pelvis in dogs and cats: 34 cases (1978-1982). *J Am Vet Med Assoc.* 1987;190(5):569-572.
29. Meeson RL, Geddes AT. Management and long-term outcome of pelvic fractures: a retrospective study of 43 cats. *J Feline Med Surg.* 2017;19(1):36-41.
30. Fanton JW, Blass CE, Withrow SJ. Sciatic nerve injuries as complication of intramedullary pin fixation of femoral fractures. *J Am Anim Hosp Assoc.* 1983;19:687-694.
31. Andrews CM, Liska WD, Roberts DJ. Sciatic neurapraxia as a complication in 1000 consecutive canine total hip replacements. *Vet Surg.* 2008;37(3):254-262.
32. Tavola F, Drudi D, Vezzoni L, Vezzoni A. Postoperative complications of double pelvic osteotomy using specific plates in 305 dogs. *Vet Comp Orthop Traumatol.* 2022;35(1):47-56.
33. Properzi R, Collivignarelli F, Paolini A, et al. Evaluation of the iatrogenic sciatic nerve injury following double pelvic osteotomy performed with piezoelectric cutting tool in dogs. *Vet Sci.* 2022;9(6):259.
34. Ingendaay C, Burger M, Linzmann H, et al. Injuries in the dog due to wild boar. *Kleintierpraxis.* 2008;53(1):13-23.
35. Mortari AC, Quitzan JG, Brandão CVS, Rahal SC. Sciatic nerve injection palsy in a dog: electrodiagnostic testing and microsurgical treatment. *Acta Sci Vet.* 2018;46:4.
36. Kakati A, Bhat D, Indira Devi B, et al. Injection nerve palsy. *J Neurosci Rural Pract.* 2013;4(1):13-18.
37. Kim HJ, Park SH. Sciatic nerve injection injury. *J Int Med Res.* 2014;42(4):887-897.
38. Baxter JS, Evans JM. Intramuscular injection in the cat. *J Small Anim Pract.* 1973;14(5):297-302.
39. Benigni L, Corr SA, Lamb CR. Ultrasonographic assessment of the canine sciatic nerve. *Vet Radiol Ultrasound.* 2007;48(5):428-433.
40. Bilgici A, Cokluk C, Aydin K. Ultrasound neurography in the evaluation of sciatic nerve injuries. *J Phys Ther Sci.* 2013;25(10):1209-1211.
41. Toijala TM, Canapp DA, Canapp SO. Ultrasonography findings in the proximal sciatic nerve and deep gluteal muscles in 29 dogs with suspected sciatic neuritis. *Front Vet Sci.* 2021;27(8):704904.
42. Amrami KK, Felmlee JP, Spinner RJ. MRI of peripheral nerves. *Neurosurg Clin N Am.* 2008;19(4):559-572.
43. Mitchell CH, Brushart TM, Ahlawat S, Belzberg AJ, Carrino JA, Fayad LM. MRI of sports-related peripheral nerve injuries. *Am J Roentgenol.* 2014;203(5):1075-1084.
44. Olby N, Levine J, Harris T, Muñana K, Skeen T, Sharp N. Long-term functional outcome of dogs with severe injuries of the thoracolumbar spinal cord: 87 cases (1996-2001). *J Am Vet Med Assoc.* 2003;222(6):762-769.
45. Robinson LR. Traumatic injury to peripheral nerves. *Muscle Nerve.* 2022;66(6):661-670.
46. Huynh W, Kiernan MC. Nerve conduction studies. *Aust Fam Physician.* 2011;40(9):693-697.
47. Campbell WW. Evaluation and management of peripheral nerve injury. *Clin Neurophysiol.* 2008;119(9):1951-1965.
48. Peng Y, Li KY, Chen YF, et al. Beagle sciatic nerve regeneration across a 30 mm defect bridged by chitosan/PGA artificial nerve grafts. *Injury.* 2018;49(8):1477-1484.
49. Lee WP, Constantinescu MA, Butler PE. Effect of early mobilization on healing of nerve repair: histologic observations in a canine model. *Plast Reconstr Surg.* 1999;104(6):1718-1725.
50. Granger N, Moissonnier P, Fanchon L, Hidalgo A, Gnirs K, Blot S. Cutaneous saphenous nerve graft for the treatment of sciatic neurotmesis in a dog. *J Am Vet Med Assoc.* 2006;229(1):82-86.
51. Lee H, Lee H, Lee K, et al. Epineural neuroorrhaphy of a large nerve defect due to iatrogenic sciatic nerve injury in a maltese dog. *Vet Sci.* 2022;9(7):361.
52. Levine JM, Fitch RB. Use of an ankle-foot orthosis in a dog with traumatic sciatic neuropathy. *J Small Anim Pract.* 2003;44(5):236-238.
53. Novak CB, von der Heyde RL. Rehabilitation of the upper extremity following nerve and tendon reconstruction: when and how. *Semin Plast Surg.* 2015;29(1):73-80.
54. Ree J, Hayashi K, Woelz J, Kim SY. Use of physical therapy in a dog with bilateral severe plantigrade stance. *J Am Anim Hosp Assoc.* 2015;51(1):31-35.
55. Ciaramitaro P, Mondelli M, Logullo F, et al. Traumatic peripheral nerve injuries: epidemiological findings, neuropathic pain and quality of life in 158 patients. *J Peripher Nerv Syst.* 2010;15(2):120-127.
56. Dickerson VM, Coleman KD, Ogawa M, et al. Outcomes of dogs undergoing limb amputation, owner satisfaction with limb amputation procedures, and owner perceptions regarding postsurgical adaptation: 64 cases (2005-2012). *J Am Vet Med Assoc.* 2015;247(7):786-792.
57. Roberts C, Blackwell EJ, Roe E, Murrell JC, Mullan S. Awareness and use of canine quality of life assessment tools in UK veterinary practice. *Animals.* 2023;13(6):1105.
58. Lavan RP. Development and validation of a survey for quality of life assessment by owners of healthy dogs. *Vet J.* 2013;197(3):578-582.

SUPPORTING INFORMATION

Additional supporting information can be found online in the Supporting Information section at the end of this article.

How to cite this article: Dell'Apa D, Auletta L, Okonji S, et al. Traumatic and iatrogenic sciatic nerve injury in 38 dogs and 10 cats: Clinical and electrodiagnostic findings. *J Vet Intern Med.* 2024;1-13. doi:10.1111/jvim.17076