



UNIVERSITÀ DI PARMA

ARCHIVIO DELLA RICERCA

University of Parma Research Repository

Sonographic knowledge of occiput position to decrease failed operative vaginal delivery: a systematic review and meta-analysis of randomized controlled trials

This is the peer reviewed version of the following article:

Original

Sonographic knowledge of occiput position to decrease failed operative vaginal delivery: a systematic review and meta-analysis of randomized controlled trials / Bellussi, F.; Di Mascio, D.; Salsi, G.; Ghi, T.; Dall'Asta, A.; Zullo, F.; Pilu, G.; Barros, J. G.; Ayres-de-Campos, D.; Berghella, V.. - In: AMERICAN JOURNAL OF OBSTETRICS AND GYNECOLOGY. - ISSN 0002-9378. - (2021). [10.1016/j.ajog.2021.08.057]

Availability:

This version is available at: 11381/2904053 since: 2022-01-10T01:59:30Z

Publisher:

Elsevier Inc.

Published

DOI:10.1016/j.ajog.2021.08.057

Terms of use:

Anyone can freely access the full text of works made available as "Open Access". Works made available

Publisher copyright

note finali coverage

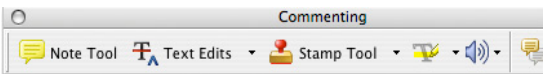
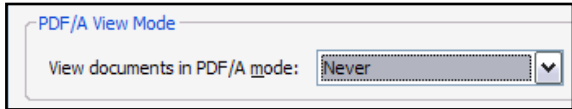
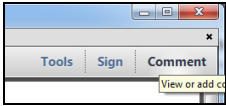
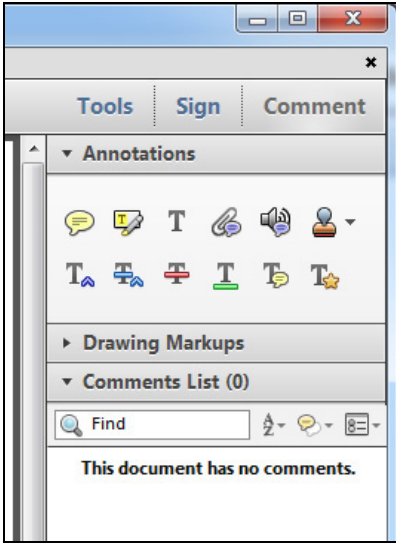
(Article begins on next page)

02 May 2026

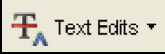


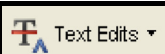

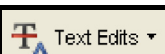





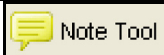

INSTRUCTIONS ON THE ANNOTATION OF PDF FILES


To view, print and annotate your content you will need Adobe Reader version 9 (or higher). This program is freely available for a whole series of platforms that include PC, Mac, and UNIX and can be downloaded from <http://get.adobe.com/reader/>. The exact system requirements are given at the Adobe site: <http://www.adobe.com/products/reader/tech-specs.html>.

Note: Please do NOT make direct edits to the PDF using the editing tools as doing so could lead us to overlook your desired changes. Rather, please request corrections by using the tools in the Comment pane to annotate the PDF and call out the changes you are requesting. If you opt to annotate the file with software other than Adobe Reader then please also highlight the appropriate place in the PDF file.

PDF ANNOTATIONS	
Adobe Reader version 9	Adobe Reader version X and XI
<p>When you open the PDF file using Adobe Reader, the Commenting tool bar should be displayed automatically; if not, click on 'Tools', select 'Comment & Markup', then click on 'Show Comment & Markup tool bar' (or 'Show Commenting bar' on the Mac). If these options are not available in your Adobe Reader menus then it is possible that your Adobe Acrobat version is lower than 9 or the PDF has not been prepared properly.</p>  <p>(Mac)</p> <p>PDF ANNOTATIONS (Adobe Reader version 9)</p> <p>The default for the Commenting tool bar is set to 'off' in version 9. To change this setting select 'Edit Preferences', then 'Documents' (at left under 'Categories'), then select the option 'Never' for 'PDF/A View Mode'.</p>  <p>(Changing the default setting, Adobe version 9)</p>	<p>To make annotations in the PDF file, open the PDF file using Adobe Reader XI, click on 'Comment'.</p> <p>If this option is not available in your Adobe Reader menus then it is possible that your Adobe Acrobat version is lower than XI or the PDF has not been prepared properly.</p>  <p>This opens a task pane and, below that, a list of all Comments in the text. These comments initially show all the changes made by our copyeditor to your file.</p> 

HOW TO...

HOW TO...		
Action	Adobe Reader version 9	Adobe Reader version X and XI
Insert text	<p>Click the 'Text Edits' button  on the Commenting tool bar. Click to set the cursor location in the text and simply start typing. The text will appear in a commenting box. You may also cut-and-paste text from another file into the commenting box. Close the box by clicking on 'x' in the top right-hand corner.</p>	<p>Click the 'Insert Text' icon  on the Comment tool bar. Click to set the cursor location in the text and simply start typing. The text will appear in a commenting box. You may also cut-and-paste text from another file into the commenting box. Close the box by clicking on '_'  in the top right-hand corner.</p>
Replace text	<p>Click the 'Text Edits' button  on the Commenting tool bar. To highlight the text to be replaced, click and drag the cursor over the text. Then simply type in the replacement text. The replacement text will appear in a commenting box. You may also cut-and-paste text from another file into this box. To replace formatted text (an equation for example) please Attach a file (see below).</p>	<p>Click the 'Replace (Ins)' icon  on the Comment tool bar. To highlight the text to be replaced, click and drag the cursor over the text. Then simply type in the replacement text. The replacement text will appear in a commenting box. You may also cut-and-paste text from another file into this box. To replace formatted text (an equation for example) please Attach a file (see below).</p>
Remove text	<p>Click the 'Text Edits' button  on the Commenting tool bar. Click and drag over the text to be deleted. Then press the delete button on your keyboard. The text to be deleted will then be struck through.</p>	<p>Click the 'Strikethrough (Del)' icon  on the Comment tool bar. Click and drag over the text to be deleted. Then press the delete button on your keyboard. The text to be deleted will then be struck through.</p>
Highlight text/ make a comment	<p>Click on the 'Highlight' button  on the Commenting tool bar. Click and drag over the text. To make a comment, double click on the highlighted text and simply start typing.</p>	<p>Click on the 'Highlight Text' icon  on the Comment tool bar. Click and drag over the text. To make a comment, double click on the highlighted text and simply start typing.</p>
Attach a file	<p>Click on the 'Attach a File' button  on the Commenting tool bar. Click on the figure, table or formatted text to be replaced. A window will automatically open allowing you to attach the file. To make a comment, go to 'General' in the 'Properties' window, and then 'Description'. A graphic will appear in the PDF file indicating the insertion of a file.</p>	<p>Click on the 'Attach File' icon  on the Comment tool bar. Click on the figure, table or formatted text to be replaced. A window will automatically open allowing you to attach the file. A graphic will appear indicating the insertion of a file.</p>
Leave a note/ comment	<p>Click on the 'Note Tool' button  on the Commenting tool bar. Click to set the location of the note on the document and simply start typing. <u>Do not use this feature to make text edits.</u></p>	<p>Click on the 'Add Sticky Note' icon  on the Comment tool bar. Click to set the location of the note on the document and simply start typing. <u>Do not use this feature to make text edits.</u></p>

HOW TO...		
Action	Adobe Reader version 9	Adobe Reader version X and XI
Review	To review your changes, click on the 'Show' button  on the Commenting tool bar. Choose 'Show Comments List'. Navigate by clicking on a correction in the list. Alternatively, double click on any mark-up to open the commenting box.	Your changes will appear automatically in a list below the Comment tool bar. Navigate by clicking on a correction in the list. Alternatively, double click on any mark-up to open the commenting box.
Undo/delete change	To undo any changes made, use the right click button on your mouse (for PCs, Ctrl-Click for the Mac). Alternatively click on 'Edit' in the main Adobe menu and then 'Undo'. You can also delete edits using the right click (Ctrl-click on the Mac) and selecting 'Delete'.	To undo any changes made, use the right click button on your mouse (for PCs, Ctrl-Click for the Mac). Alternatively click on 'Edit' in the main Adobe menu and then 'Undo'. You can also delete edits using the right click (Ctrl-click on the Mac) and selecting 'Delete'.


SEND YOUR ANNOTATED PDF FILE BACK TO ELSEVIER

Save the annotations to your file and return as instructed by Elsevier. Before returning, please ensure you have answered any questions raised on the Query Form and that you have inserted all corrections: later inclusion of any subsequent corrections cannot be guaranteed.

FURTHER POINTS

- Any (grey) halftones (photographs, micrographs, etc.) are best viewed on screen, for which they are optimized, and your local printer may not be able to output the greys correctly.
- If the PDF files contain colour images, and if you do have a local colour printer available, then it will be likely that you will not be able to correctly reproduce the colours on it, as local variations can occur.
- If you print the PDF file attached, and notice some 'non-standard' output, please check if the problem is also present on screen. If the correct printer driver for your printer is not installed on your PC, the printed output will be distorted.

AUTHOR QUERY FORM







 ELSEVIER	Journal: YMOB Article Number: 14050	Please e-mail your responses and any corrections to: E-mail: corrections.esi@elsevier.tnq.co.in
--	--	--

Dear Author,

Please check your proof carefully and mark all corrections at the appropriate place in the proof (e.g., by using on-screen annotation in the PDF file) or compile them in a separate list. **It is crucial that you NOT make direct edits to the PDF using the editing tools as doing so could lead us to overlook your desired changes.** Note: if you opt to annotate the file with software other than Adobe Reader then please also highlight the appropriate place in the PDF file. To ensure fast publication of your paper please return your corrections within 48 hours.

For correction or revision of any artwork, please consult <http://www.elsevier.com/artworkinstructions>.

Any queries or remarks that have arisen during the processing of your manuscript are listed below and highlighted by flags in the proof.

Location in article	Query / Remark: Click on the Q link to find the query's location in text Please insert your reply or correction at the corresponding line in the proof
	If there are any drug dosages in your article, please verify them and indicate that you have done so by initialing this query
Q1 	We have added the highest academic degrees of the authors per the manuscript draft. Please check if the degrees are correct as given.
Q2 	Sentence beginning "In this meta-analysis..." was reworded because journal style does not allow claims of primacy. Please review.
Q3 	Sentence beginning "Failure to progress..." okay as edited?
Q4 	Sentence beginning "In this meta-analysis..." okay as edited?
Q5	Please edit the Figure 2 title down to 8-10 words or less, if possible, per journal style.
Q6	Please insert the in-text citation for Ghi et al in place of superscripted XX in the column headings of Tables 1–5, per the reference list.
Q7	Please expand the abbreviations "VE" and "US" in the lettered footnotes of Table 3, per journal style.
Q8	Figure 3 is not cited in the text. Kindly check and provide citation.
Q9 	Correctly acknowledging the primary funders and grant IDs of your research is important to ensure compliance with funder policies. We could not find any acknowledgement of funding sources in your text. Is this correct?
Q10 	Please confirm that given names and surnames have been identified correctly and are presented in the desired order and please carefully verify the spelling of all authors' names.

(continued on next page)

Please check this box or indicate
your approval if you have no
corrections to make to the PDF file

Thank you for your assistance.

Sonographic knowledge of occiput position to decrease failed operative vaginal delivery: a systematic review and meta-analysis of randomized controlled trials

Federica Bellussi, MD, PhD; Daniele Di Mascio, MD; Ginevra Salsi, MD, PhD; Tullio Ghi, MD, PhD; Andrea Dall'Asta, MD, PhD; Fabrizio Zullo, MD; Gianluigi Pili, MD; Joana G. Barros, MD; Diogo Ayres-de-Campos, MD, PhD; Vincenzo Berghella, MD

Introduction

Safe, successful operative vaginal delivery (OVD) is an important goal in contemporary obstetrics. Failed OVD, defined as cesarean delivery (CD) or sequential use of different instruments after a trial of OVD, is associated with an increased risk for complications such as neonatal metabolic acidosis, seizures, neonatal encephalopathy, neonatal intracranial hemorrhage and maternal postpartum hemorrhage, prolonged hospitalization, and perineal wound complications.^{1–5} Moreover, second stage CD is also associated with risks, and the rate of complications increases

From the Division of Maternal-Fetal Medicine, Department of Obstetrics and Gynecology, Thomas Jefferson University Hospital, Philadelphia, PA (Drs Bellussi and Berghella); Department of Maternal and Child Health and Urological Sciences, Sapienza University of Rome, Italy (Drs Di Mascio and Zullo); Department of Medical and Surgical Sciences, Obstetric and Gynecologic Unit, S. Orsola-Malpighi Polyclinic, University of Bologna, Bologna, Italy (Drs Salsi and Pili); Obstetrics and Gynecology Unit, Department of Medicine and Surgery, University of Parma, Parma, Italy (Drs Ghi and Dall'Asta); Department of Obstetrics and Gynecology, Santa Maria University Hospital, Lisbon, Portugal (Drs Barros and Ayres-de-Campos); and Faculty of Medicine, University of Lisbon, Lisbon, Portugal (Dr Ayres-de-Campos).

Received June 29, 2021; revised Aug. 25, 2021; accepted Aug. 31, 2021.

The authors report no conflict of interest.

This study received no financial support.

Corresponding author: Federica Bellussi, MD, PhD. bellussi.federica@gmail.com

0002-9378/\$36.00

© 2021 Elsevier Inc. All rights reserved.

<https://doi.org/10.1016/j.ajog.2021.08.057>

OBJECTIVE: This study aimed to assess the efficacy of sonographic assessment of fetal occiput position before operative vaginal delivery to decrease the number of failed operative vaginal deliveries.

DATA SOURCES: The search was conducted in MEDLINE, Embase, Web of Science, Scopus, [ClinicalTrials.gov](https://www.clinicaltrials.gov), Ovid, and Cochrane Library as electronic databases from the inception of each database to April 2021. No restrictions for language or geographic location were applied.

STUDY ELIGIBILITY CRITERIA: Selection criteria included randomized controlled trials of pregnant women randomized to either sonographic or clinical digital diagnosis of fetal occiput position during the second stage of labor before operative vaginal delivery.

METHODS: The primary outcome was failed operative vaginal delivery, defined as a failed fetal operative vaginal delivery (vacuum or forceps) extraction requiring a cesarean delivery or forceps after failed vacuum. The summary measures were reported as relative risks or as mean differences with 95% confidence intervals using the random effects model of DerSimonian and Laird. An I^2 (Higgins I^2) $>0\%$ was used to identify heterogeneity.

RESULTS: A total of 4 randomized controlled trials including 1007 women with singleton, term, cephalic fetuses randomized to either the sonographic ($n=484$) or clinical digital ($n=523$) diagnosis of occiput position during the second stage of labor before operative vaginal delivery were included. Before operative vaginal delivery, fetal occiput position was diagnosed as anterior in 63.5% of the sonographic diagnosis group vs 69.5% in the clinical digital diagnosis group ($P=.04$). There was no significant difference in the rate of failed operative vaginal deliveries between the sonographic and clinical diagnosis of occiput position groups (9.9% vs 8.2%; relative risk, 1.14; 95% confidence interval, 0.77–1.68). Women randomized to sonographic diagnosis of occiput position had a significantly lower rate of occiput position discordance between the evaluation before operative vaginal delivery and the at birth evaluation when compared with those randomized to the clinical diagnosis group (2.3% vs 17.7%; relative risk, 0.16; 95% confidence interval, 0.04–0.74; $P=.02$). There were no significant differences in any of the other secondary obstetrical and perinatal outcomes assessed.

CONCLUSION: Sonographic knowledge of occiput position before operative vaginal delivery does not seem to have an effect on the incidence of failed operative vaginal deliveries despite better sonographic accuracy in the occiput position diagnosis when compared with clinical assessment. Perhaps future studies should evaluate how a more accurate sonographic diagnosis of occiput position or other parameters can lead to a safer and more effective operative vaginal delivery technique.

Key words: delivery outcome, instrumental vaginal delivery, occiput position, ultrasound in labor

AJOG at a Glance

Why was this study conducted?

A sonographic diagnosis is more accurate than a clinical digital diagnosis for fetal occiput position. It is unknown if this improved knowledge affects pregnancy outcomes when acquired before an operative vaginal delivery (OVD).

Key findings

This meta-analysis of randomized controlled trials (RCTs) showed that sonographic knowledge of occiput position before OVD does not have an effect on the incidence of failed OVD. There were no significant differences in any other obstetrical and perinatal outcomes assessed.

What does this add to what is known?

In this meta-analysis, recent RCTs on sonographic knowledge vs clinical knowledge of fetal occiput position before OVD were evaluated. Future studies should perhaps evaluate how a more accurate sonographic diagnosis of occiput position or other parameters can lead to a safer and more effective OVD technique.

when the CD is performed after a trial of OVD.¹

According to the international guidelines,^{6,7} an accurate diagnosis of fetal occiput position is necessary for a safe OVD, because an incorrect diagnosis of the occiput position is associated with an increased risk for failed OVD and its consequences. Clinical digital examination is traditionally performed before OVD to diagnose fetal occiput position, but studies in which ultrasound has been used show that the clinical examination alone is unreliable, because it fails to accurately diagnose the correct occiput position in many cases (about 20%), particularly in cases of occiput posterior or transverse position.^{8,9} In this scenario, over the past few years, performing an ultrasound before OVD has been proposed^{5,10–15} to improve the accuracy of the diagnosis of fetal occiput position.^{8,16–18}

Objective

The aim of our meta-analysis was to evaluate the effect of ultrasound diagnosis of fetal occiput position before OVD on the incidence of failed OVD, defined as a CD or sequential use of different instruments after a trial of OVD.

Materials and Methods**Search strategy**

This meta-analysis was performed according to a protocol recommended

for systematic review.¹⁹ The review protocol was designed by a priori defining methods for collecting, extracting, and analyzing data. The research was conducted using MEDLINE, Embase, Web of Science, Scopus, ClinicalTrial.gov, Ovid, and Cochrane Library as electronic databases from the inception of each database to April 2021. We systematically searched for a combination of the following terms: “ultrasound in labor,” intrapartum sonography,” “occiput position,” “fetal head position,” “instrumental vaginal delivery,” “operative vaginal delivery,” “vacuum delivery,” “forceps delivery,” and “fetal head presentation.” Review of articles also included the abstracts of all references retrieved from the search. No restrictions for language or geographic location were applied.

Study selection

Selection criteria included only randomized controlled trials (RCTs) of pregnant women randomized to either sonographic or clinical digital diagnosis of occiput position during the second stage of labor. Quasi-randomized trials (ie, trials in which the allocation was done based on a pseudorandom sequence, for example odd and even hospital number or date of birth alterations) were excluded.

Risk of bias assessment

The risk of bias in each included study was assessed by using the criteria outlined in the Cochrane Handbook for Systematic Reviews of Interventions.²⁰ The following 7 domains related to risk of bias were assessed in each included trial because there is evidence that these issues are associated with biased estimates of treatment effect: (1) random sequence generation; (2) allocation concealment; (3) blinding of participants and personnel; (4) blinding of outcome assessment; (5) incomplete outcome data; (6) selective reporting; and (7) other bias. The review authors' judgments were categorized as “low risk,” “high risk,” or “unclear risk” of bias.²⁰

Primary and secondary outcomes

The primary outcome was failed OVD, defined as a failed fetal vacuum or forceps operative extraction requiring a subsequent CD or instrumental delivery with forceps after a failed vacuum extraction attempt.

The secondary obstetrical outcomes were:

1. CD owing to failed OVD;
2. Obstetrical anal sphincter injuries (grade III and IV perineal tears);
3. Shoulder dystocia;
4. Distance between the center of the chignon and the flexion point;
5. Difficult OVD, defined as the number of patients who had ≥ 1 of the following: >3 tractions, CD, sequential instrument delivery, obstetrical anal sphincter injuries (OASIS), neonatal trauma;
6. Discordance in occiput position between pre-OVD evaluation and birth.

Secondary perinatal outcomes were:

1. Admission to neonatal intensive care unit (NICU);
2. Apgar score <7 at 5 minutes;
3. Neonatal trauma (skull fractures, subgaleal hemorrhage, cephalohematoma, any other neonatal hemorrhage);
4. Umbilical cord arterial pH <7.0 ;

5. Composite perinatal outcome defined as the sum of each of the perinatal outcomes;
6. Composite perinatal outcome defined as the number of patients experiencing at least 1 perinatal outcome.

Data extraction

Data extraction was completed by 2 independent authors (F.B. and G.S.). We resolved discrepancies through discussion and by consensus with a third reviewer (V.B.). Before data extraction, the review was registered with the PROSPERO International Prospective Register of Systematic Reviews (registration number, CRD42020136182). In case of missing data in a relevant article, the corresponding and/or the primary authors were contacted for additional information.

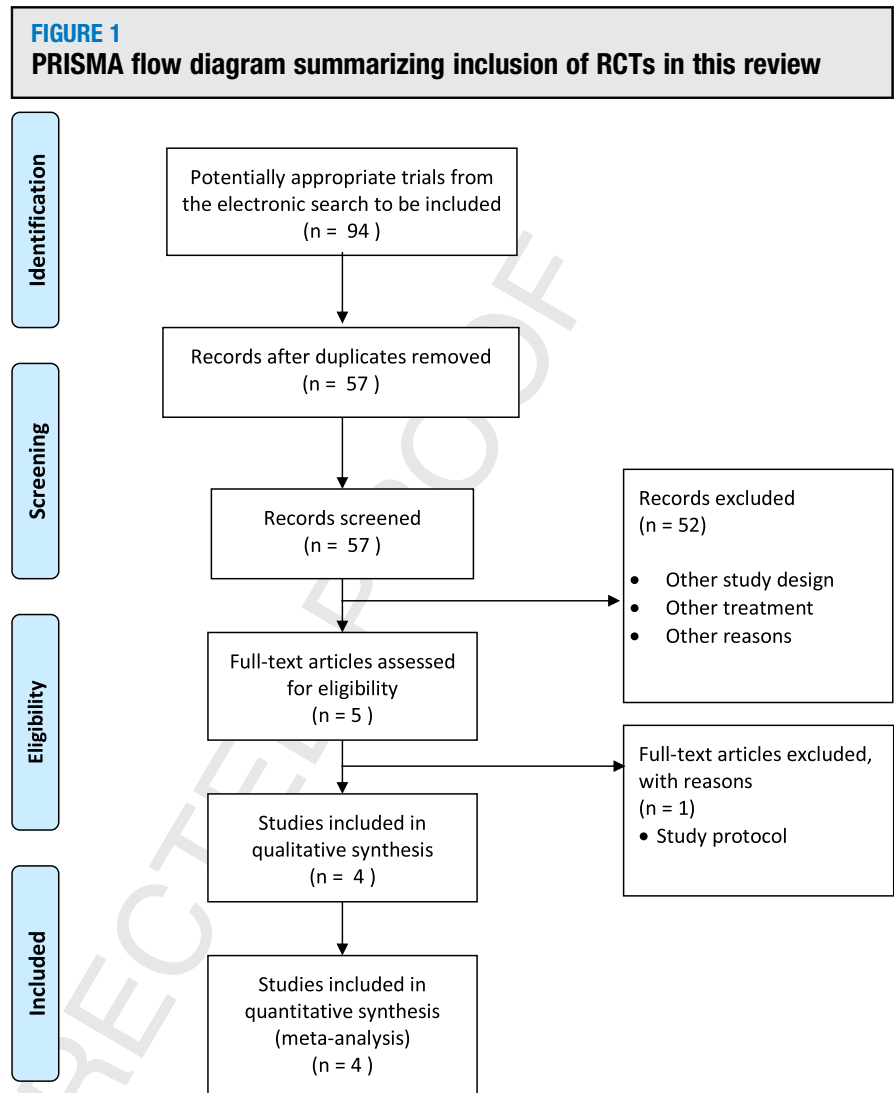
Data analysis

Data analysis was completed using Review Manager 5.4.1 (Copenhagen: The Nordic Cochrane Center, Cochrane Collaboration, 2020). The summary measures were reported as summary relative risks (RRs) or as summary mean differences (MDs) with 95% of confidence intervals (CIs) using the random effects model of DerSimonian and Laird. I^2 (Higgins I^2) $>0\%$ was used to identify heterogeneity. Potential publication biases were assessed graphically by using the funnel plot. The meta-analysis was reported according to the Preferred Reporting Item for Systematic Reviews and Meta-analyses (PRISMA) statement.²¹

Results

Study selection

[F1] Figure 1 shows the flow diagram (PRISMA template) of information derived from our review of potentially relevant articles. A total of 4 RCTs that included 1007 women randomized to either sonographic or clinical digital diagnosis of occiput position during the second stage of labor were included.^{8,16–18} Of the 1007 women included in the meta-analysis, 484 (48.1%) were randomized to the sonographic arm and 523 (51.9%) to the clinical digital diagnosis of occiput position arm.



PRISMA, preferred reporting items for systematic reviews and meta-analysis; RCTs, randomized controlled trials.
Bellussi. Sonographic occiput position before operative vaginal delivery. *Am J Obstet Gynecol* 2021.

Study characteristics

Table 1 shows characteristics of the included studies. Type of participants included women with singleton, term pregnancies and vertex presentation for which an OVD was indicated mainly for a prolonged second stage, failure to progress, fetal distress, or nonreassuring cardiotocography tracings. Only 2 studies were completed after reaching the needed sample size.^{8,17} Labor characteristics are described in Table 2. Most women had spontaneous labor and epidural anesthesia; rates of epidural use ($P=.80$), induction of labor ($P=.93$), and oxytocin augmentation ($P=.06$) were similar between the 2

groups. Failure to progress was the⁰³ most common indication for OVD, [T1] occurring in 50.4% of the sonographic examination group and in 60.6% of the clinical digital examination group ($P=.03$). The occiput posterior or transverse positions before OVD were detected significantly more frequently in the sonographic examination group than in the clinical digital examination group (36.4% vs 30.4%, respectively; $P=.04$). The frequency of fetal head [T2] station at $\geq +2$ was similar (44.5% vs 48.9%, respectively) for the 2 groups ($P=.33$). Rates of low birthweight (LBW) neonates were similar for the 2 groups ($P=.17$).

335
336
337
338
339
340
341
342
343
344
345
346
347
348
349
350
351
352
353
354
355
356
357
358
359
360
361
362
363
364
365
366
367
368
369
370
371
372
373
374
375
376
377
378
379
380
381
382
383
384
385
386
387
388
389
390**TABLE 1**
Characteristics of the included studies

Characteristics	Wong et al, ¹⁷ 2007	Ramphul et al, ⁸ 2014	Ghi et al, ^{xx} 2018	Barros et al, ¹⁶ 2020
Location	Hong Kong	Ireland	Italy	Portugal
Type of study	Single center RCT	Multicenter RCT	Multicenter RCT	Multicenter RCT
Sample size	25 vs 25	257 vs 257	89 vs 132	113 vs 109
Intervention	Clinical examination (transabdominal and vaginal assessment of occiput position) followed by US examination (transabdominal US assessment of spine and occiput position)	Abdominal and vaginal examination and US examination (transabdominal US assessment of spine and occiput position)	Vaginal examination followed by transabdominal US assessment of occiput position	Transabdominal US assessment of occiput position and transperineal assessment of the angle of progression
Control	Clinical digital examination of the occiput position	Abdominal and vaginal examination	Vaginal examination	Vaginal examination
Inclusion criteria	- Prolonged second stage and indication for OVD	- Singleton - Cephalic presentation - Indication for OVD	- Singleton - >18 y - Cephalic presentation - Indication for OVD	- Singleton - Cephalic presentation - Nonemergent indication for OVD
Exclusion criteria	- Multiple pregnancies - Preterm - Fetal distress - Contraindication for OVD	- Multiple pregnancies - <18 y - Limited understanding of English - Contraindication for OVD	- Any contraindication to OVD - Fetal head station >+3 - Emergency delivery needed - Sonographic evaluation of fetal head position performed before randomization	- <18 y - Fetal malformations - Limited understanding of the study
GA at randomization	≥37 wk	≥37 wk	≥37 wk	≥ 37 wk
Study primary outcome	Distance between the center of the chignon and the flexion point	Incorrect diagnosis of the fetal head position (diagnosis of incorrect position diagnosis was not done by US but by discrepancy between pre-OVD diagnosis and birth diagnosis or postnatal examination of instrument's markings on the neonatal face after delivery)	Incidence of failed vacuum extraction and need to perform emergency cesarean delivery	Composite of maternal and neonatal morbidity (severe PPH, severe perineal trauma, >48 h of postnatal hospital stay, low 5-min Apgar score, umbilical artery metabolic acidosis, birth trauma, and NICU admission)
Intention to treat analysis	Not reported	Yes	Not reported	Yes

Bellussi. Sonographic occiput position before operative vaginal delivery. *Am J Obstet Gynecol* 2021.

(continued)

391
392
393
394
395
396
397
398
399
400
401
402
403
404
405
406
407
408
409
410
411
412
413
414
415
416
417
418
419
420
421
422
423
424
425
426
427
428
429
430
431
432
433
434
435
436
437
438
439
440
441
442
443
444
445
446

TABLE 1
Characteristics of the included studies (continued)

Characteristics	Wong et al, ¹⁷ 2007	Ramphul et al, ⁸ 2014	Ghi et al, ^{xx} 2018	Barros et al, ¹⁶ 2020
Randomization technique	Randomization was done by computer-generated random numbers in a ratio of 1:1 using sealed envelopes, which were opened after recruitment at the time of decision for vacuum extraction	Randomization in a 1:1 ratio using a secure, web-based central randomization service, ensuring concealment of allocation. The allocation sequence was computer generated, stratified by center, and used random permuted blocks of 4, 8, and 12 women	Online randomization program	Randomization in a 1:1 ratio to 1 of the 2 study groups. The allocation group was determined by opening a previously prepared opaque, sealed envelope. These envelopes contained the results of an allocation sequence, created by a computer random-number generator, according to a permuted block method
Study completed after reaching sample size	Yes	Yes	No	No

GA, gestational age; NICU, neonatal intensive care unit; OVD, operative vaginal delivery; PPH, postpartum hemorrhage; RCT, randomized controlled trial; US, ultrasound; Bellussi. *Sonographic occiput position before operative vaginal delivery. Am J Obstet Gynecol* 2021.

Table 3 shows details of OVD. Two studies only used vacuum devices,^{17,18} whereas the other 2 used both vacuum and forceps.^{8,16} The rate of vacuum delivery (only vacuum used), forceps delivery (only forceps use), and sequential use of instruments (vacuum or forceps first) was similar for the 2 groups. Similarly, the number of cup applications and cup detachments and the rate of >3 tractions were also similar for both groups.

Risk of bias of the included studies

The quality of the RCTs included in our meta-analysis was assessed using the Cochrane Collaboration's Risk of Bias Tool.²¹ All the included studies used a computer-generated table of random numbers and had a low risk of bias for "incomplete outcome data" category (Figure 2). No method of blinding of either the participants or the outcome assessment was reported.

Synthesis of results

Table 4 shows the primary and secondary obstetrical outcomes. There was no significant difference in the rate of failed OVDs between the sonographic and clinical digital diagnosis of occiput position groups (9.9% vs 8.2%; RR, 1.14; 95% CI, 0.77–1.68). Similarly, no significant difference was found when considering the CD rate performed because of a failed OVD (2.9% vs 2.5%; RR, 1.1; 95% CI, 0.49–2.49).

No significant difference was also found in the rate of OASIS (9.3% vs 9.7%; $P=.59$), shoulder dystocia (4.6% vs 4.6%; $P=.91$), distance between the center of the chignon and the flexion point, and difficult OVD (20.8% vs 18.3%; $P=.82$). Finally, women randomized to the sonographic group had a significantly lower rate of discordance in the diagnosis of occiput position before OVD and in the evaluation after birth than those randomized to the clinical digital diagnosis group (2.3% vs 17.7%; RR, 0.16; 95% CI, 0.04–0.74; $P=.02$).

Table 5 shows the secondary perinatal outcomes. No significant differences were found in the rate of admission to the NICU (9.4% vs 8.6%; $P=.79$), Apgar score <7 at 5 minutes (0.6% vs 0.9%;

559
560
561
562
563
564
565
566
567
568
569
570
571
572
573
574
575
576
577
578
579
580
581
582
583
584
585
586
587
588
589
590
591
592
593
594
595
596
597
598
599
600
601
602
603
604
605
606
607
608
609
610
611
612
613
614**TABLE 2**
Labor characteristics

Characteristics	Wong et al, ¹⁷ 2007	Ramphul et al, ⁸ 2014	Ghi et al, ¹⁵ 2018	Barros et al, ¹⁶ 2020	Totals	P value
Rate of epidural use	2/25 (8) vs 3/25 (12)	228/257 (88.7) vs 228/257 (88.7)	53/89 (59.6) vs 91/132 (68.9)	112/113 (99.1) vs 108/109 (99.1)	395/484 (81.6) vs 430/523 (82.2)	.8
Induction of labor	9/25 (7.4) vs 8/25 (9.7)	129/257 (50.2) vs 129/257 (50.2)	NR	NR	138/282 (48.9) vs 137/282 (48.5)	.93
Augmentation	4/25 (9) vs 10/25 (11.8)	NR	NR	NR	4/25 (9) vs 10/25 (11.8)	.06
Indication for OVD	Prolonged second stage	General indications for instrumental delivery, including fetal distress	Failure to progress 44/89 (49.4) vs 81/132 (61.4)	Failure to progress 58/113 (51.3) vs 65/109 (59.6)	Failure to progress 102/202 (50.4) vs 146/241 (60.6)	.03
			Fetal distress 28/89 (31.4) vs 38/132 (28.7)	Nonreassuring CTG: 41/113 (36.3) vs 37/109 (33.9)		
			Failure to progress and distress: 17/89 (19) vs 13/132 (9.8)	Prophylactic/maternal indication: 5/113 (4.4) vs 2/109 (1.8)		
				Lack of maternal collaboration: 9/113 (8) vs 5/109 (4.6)		
OP position before OVD ^a	6/24 ^b (25) vs 4/25 (16)	48/257 (18.7) vs 39/257 (15.2)	NR	19/113 (16.8) vs 24/109 (22.0)	73/394 (18.5) vs 67/391 (17.13)	.61
OT position before OVD ^a	5/24 ^b (21) vs 2/25 (8)	66/257 (25.7) vs 70/257 (27.2)	NR	18/113 (15.9) vs 16/109 (14.7)	89/394 (22.5) vs 88/391 (22.5)	.98
OP or OT position before OVD ^a	11/ 24 ^b (45.8) vs 6/25 (24)	114/257 (44.4) vs 109/257 (42.4)	14/89 (15.7) vs 4/132 (3.0)	37/113 (32.7) vs 40/109 (36.7)	176/483 (36.4) vs 159/523 (30.4)	.04
OA position before OVD ^a	13/24 ^b (54.2) vs 19/25 (76)	143/257 (55.6) vs 148/257 (57.6)	75/89 (84.3) vs 128/132 (97.0)	76/113 (67.3) vs 69/109 (63.3)	307/483 (63.5) vs 364/523 (69.5)	.04
Station >+2	6/25 (24) vs 6/25 (24)	NR	31/89 (34.8) vs 56/132 (42.4)	64/113 (56.6) vs 68/109 (62.4)	101/227 (44.5) vs 130/266 (48.9)	.33
Rates of low birthweight	NR	3/257 (1.2) vs 2/257 (0.8)	4/89 (4.5) vs 3/132 (2.3)	6/113 (5.3) vs 3/109 (2.8)	13/459 (2.8) vs 8/498 (1.6)	.17

Numbers show comparison between data on patients in which ultrasound has been used in the diagnoses of occiput position before operative vaginal delivery and patients in which ultrasound was not used.

CTG, cardiotocography tracings; NR, not reported; OA, occiput anterior; OP, occiput posterior; OT, occiput transverse; OVD, operative vaginal delivery.

^a Position was ascertained by ultrasound in the intervention group and by clinical digital exam only in the control group; ^b Data available only for 24 of 25 patients (Wong et al,¹⁷ 2007).

Bellussi. Sonographic occiput position before operative vaginal delivery. *Am J Obstet Gynecol* 2021.

615
616
617
618
619
620
621
622
623
624
625
626
627
628
629
630
631
632
633
634
635
636
637
638
639
640
641
642
643
644
645
646
647
648
649
650
651
652
653
654
655
656
657
658
659
660
661
662
663
664
665
666
667
668
669
670

TABLE 3
Operative vaginal delivery details

Delivery details	Wong et al, ¹⁷ 2007	Ramphul et al, ⁸ 2014	Ghi et al, ¹⁵ 2018	Barros et al, ¹⁶ 2020	Totals	P value
Instrument used	Only vacuum (Bird's cup number 5)	Vacuum and forceps	Only vacuum	Vacuum and forceps (Simpson and Kielland)	NA	
Vacuum delivery (only vacuum used)	25/25 vs 25/25	168/257 (65.4) vs 162/257 (63.0)	89/89 (100) vs 132/132 (100)	67/113 (59.3) vs 71 (65.1)	349/484 (72) vs 390/523 (74.6)	.94
Forceps delivery (only forceps used)	0/25 (0) vs 0/25 (0)	7/257 (29.6) vs 77/257 (30.0)	0/89 (0) vs 0/132 (0) ^a	32/113 (28.3) vs 29/109 (26.6)	39/484 (8.05) vs 106/523 (20.2)	.37
Sequential use of instruments (vacuum or forceps first)	0/25 (0) vs 1/25 (4)	24/257 (9.3) vs 21/257 (8.2)	NA (only vacuum performed)	11/113 (9.7) vs 8/109 (7.3)	35/395 (8.86) vs 30/391 (7.67)	.53
Number of cup applications	NR	NR	1 application: 50/89 (56.1) vs 82/132 (62.1)	1 application: 47/80 vs 45/81 ^b	1 application 97/169 (57) vs 127/213 (59.6)	.69
			2 applications: 20/89 (22.5) vs 37/132 (28)	2 applications 20/89 (22.5) vs 37/132 (28)	.36	
			3 applications: 19/89 vs 13/132	3 applications 19/89 (21.3) vs 13/132 (9.85)	.02	
Number of cup detachments	NR	NR	NR	No cup detachment: 47/80 (59) vs 45/81 (56)	47/80 (59) vs 45/81 (56)	.68
			1 cup detachment: 18/80 (22) vs 20/81 (25)	18/80 (22) vs 20/81 (25)	.74	
			2 cup detachments: 6/80 (7.5) vs 6/81 (7.4)	6/80 (7.5) vs 6/81 (7.4)	.98	
			3 cup detachments: 8/80 ^b (10) vs 8/81 ^b (9.9)	8/80 ^b (10) vs 8/81 ^b (9.9)	.98	
>3 tractions	1/25 (4) vs 0/25 (0)	34/257 (13.2) vs 23/257 (8.9)	NR	20/113 (17.7) ^b vs 18/109 (16.5) ^b	55/395 (13.9) vs 41/391(10.55)	.15
Senior obstetrician as primary operator	NR	78/257 (30.4) vs 87/257 (33.9)	NR	NR ^c	78/257 (30.4) vs 87/257 (33.9)	.4

Numbers show comparison between data on patients in which ultrasound has been used in the diagnoses of occiput position before operative vaginal delivery vs patients in which ultrasound was not used.

NR, not reported.


^a Data with regards to NICU admission, umbilical cord pH, Apgar score <7 (the authors wrote that all the newborns did well) not available; ^b Data missing for 33 patients in the VE+US group and 28 patients in the VE group; ^c A senior obstetrician was present in every delivery and was responsible for the delivery procedure.

Bellussi. Sonographic occiput position before operative vaginal delivery. *Am J Obstet Gynecol* 2021.

727
728
729
730
731
732
733
734
735
736
737
738
739
740
741
742
743
744
745
746
747
748
749
750
751
752
753
754
755
756
757
758
759
760
761
762
763
764
765
766
767
768
769
770
771
772
773
774
775
776
777
778
779
780
781
782



FIGURE 2
Risk of bias according to the Cochrane Handbook in Randomized Controlled Trials included in this meta-analysis



Only the first author is given for each study.

Bellussi. Sonographic occiput position before operative vaginal delivery. *Am J Obstet Gynecol* 2021.

$P=.75$), neonatal trauma (4.9% vs 4.8%; $P=.93$), umbilical cord arterial pH <7 (2.7% vs 2.5%; $P=.89$), and composite perinatal outcomes defined either as the mathematical sum of each perinatal outcome (22.5% vs 21.6%; $P=.87$) or the number of patients experiencing at least 1 of the perinatal outcomes (13.9% vs 14.5%; $P=.66$).

Comment

Main findings

In this meta-analysis of 4 RCTs, which included 1007 women with singleton, term pregnancies with vertex presentation and most commonly epidural anesthesia and for which OVD was most often indicated for failure to progress, the sonographic examination group did not show a reduction in the number of failed OVDs, defined as a failed fetal vacuum or forceps operative extraction requiring a subsequent CD or instrumental delivery with forceps after a failed vacuum extraction, when compared with the clinical digital diagnosis of occiput position before an OVD group. This occurred despite the fact that the operator was aware that the occiput posterior or transverse positions before an OVD were detected significantly more frequently in the sonographic examination group than in the clinical digital examination group (36.4% vs 30.4%, respectively; $P=.04$).

Strengths and limitations

This meta-analysis of RCTs evaluated the effect of sonographic knowledge vs clinical knowledge of the fetal occiput position before an OVD on the outcome of an OVD. Only RCTs were included and for some criteria (with the notable exception of no blinding), these studies were of high quality and included >1000 women.

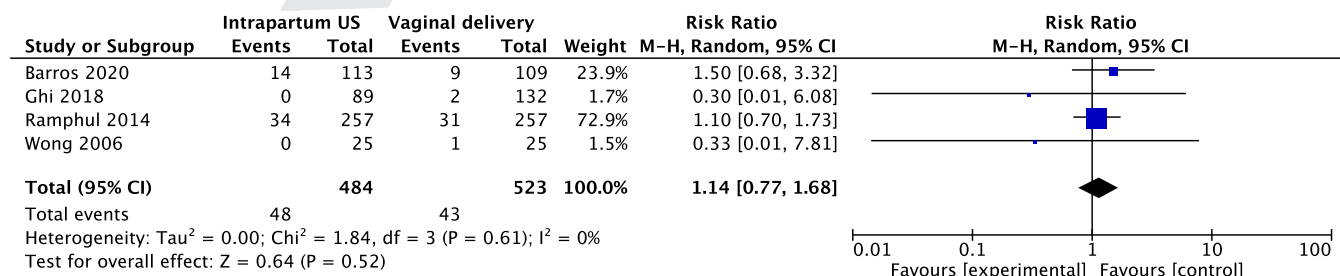
A limitation of this meta-analysis was the relatively small sample size ($n=1007$). To detect a 30% decrease in the 8.2% incidence of failed OVDs in our

control group with an alpha of 0.05 and 80% power, about 3246 women would need to be randomized. Only 2 studies¹⁴ were completed after reaching the needed sample size. About half of the OVDs were done at stations >+2, which may not be applicable in some countries such as the United States. Because an ultrasound was not done in the clinical digital examination group, the true occiput position before OVD in this group is unknown; perhaps future studies should have a “blind ultrasound” performed in the clinical digital diagnosis group. In the study by Ramphul et al⁸ (Instrumental delivery & ultrasound Irish trial), the physicians who performed the OVD did not always accept the sonographic diagnosis if discordant from their clinical digital examination assessment.⁸ Another limitation is that the exact experience and technique of each provider for each OVD was not well described in the RCTs. Another limitation is that the definition of fetal head station was different in the 3 RCTs that provided these data^{16–18}; Wong et al¹⁷ in their RCT used a range of fetal head stations between -3 and +3 and Ghi et al¹⁸ and Barros et al¹⁶ used a range of fetal head station between -5 and +5.

Comparison with existing literature

The results from this meta-analysis show a slightly lower rate of failed OVDs (9.9% for patients with ultrasound examinations vs 8.2% for patients without ultrasound examinations) when compared with previous literature. For

FIGURE 3
Forest plot of the primary outcome, failed operative vaginal delivery



Only the first author is given for each study.

Bellussi. Sonographic occiput position before operative vaginal delivery. *Am J Obstet Gynecol* 2021.

895
896
897
898
899
900
901
902
903
904
905
906
907
908
909
910
911
912
913
914
915
916
917
918
919
920
921
922
923
924
925
926
927
928
929
930
931
932
933
934
935
936
937
938
939
940
941
942
943
944
945
946
947
948
949
950**TABLE 4**
Primary and secondary obstetrical outcomes

Outcome	Wong et al, ¹⁷ 2007	Ramphul et al, ⁸ 2014	Ghi et al, ¹⁵ 2018	Barros et al, ¹⁶ 2020	Totals	RR or MD (95% CI)	P value	I2
Failed OVD (CD or sequential)	0/25 (0) vs 1/25 (4)	34/257 (13.2) vs 31/257 (12)	0/89 (0) vs 2/132 (1.5)	14/113 (3.5) vs 9/109 (0.9)	48/484 (9.9) vs 43/523 (8.2)	1.14 (0.77–1.68)	.52	0
CD owing to failed OVD	0/25 (0) vs 0/25 (0)	10/257 (3.9) vs 10/257 (3.9)	0/89 (0) vs 2/132 (1.5)	4/113 (3.5) vs 1/109 (0.9)	14/484 (2.9) vs 13/523 (2.5)	1.1 (0.49–2.49)	.81	3
OASIS (third- and fourth-degree perineal tears)	0/25 (0) vs 0/25 (0)	10/257 (3.9) vs 7/257 (2.7)	5/89 (5.6) vs 7/132 (5.3)	11/113 (9.7) vs 17/109 (15.6)	45/484 (9.3) vs 51/523 (9.7)	0.9 (0.62–1.31)	.59	0
Shoulder dystocia	NR	9 (3.5) vs 13 (5.1)	4/89 (4.5) vs 2/132 (1.5)	8/113 (7.1) vs 8/109 (7.3)	21/459 (4.6) vs 23/498 (4.6)	0.96 (0.5–1.84)	.91	14
Distance between the center of the chignon and the flexion point	2.1±1.3 vs 2.8±1.0	NR	1.57±0.99 vs 1.64±1.55	NR	NR	−0.32 (−0.93 to 0.28)	.3	66
Difficult OVD (number of patients who has had >1 of the following: >3 tractions, CD, sequential instrument delivery, OASIS, neonatal trauma ^a)	NR	NR	10/89 (11.2) vs 15/132 (11.4)	32/113 (28.3) vs 29/109 (26.6)	42/202 (20.8) vs 44/241 (18.3)	1.05 (0.72–1.52)	.82	0
Discordance of occiput position between pre-OVD evaluation and birth	NR	4/257 (1.6) vs 52/257 (20.2)	4/89 (4.5) vs 17/132 (12.9)	NR	8/346 (2.3) vs 69/389 (17.7)	0.16 (0.04–0.74)	.02	77

Numbers show comparison between data on patients in which ultrasound has been used in the diagnoses of occiput position before operative vaginal delivery vs patients in which ultrasound was not used.

CD, cesarean delivery; CI, confidence interval; MD, mean difference; NR, not reported; OASIS, obstetrical anal sphincter injuries; OVD, operative vaginal delivery; RR, relative risk.

^a Neonatal trauma include skull fractures, subgaleal hemorrhage, cephalohematoma, or any other neonatal hemorrhage.

Bellussi. Sonographic occiput position before operative vaginal delivery. *Am J Obstet Gynecol* 2021.

951
952
953
954
955
956
957
958
959
960
961
962
963
964
965
966
967
968
969
970
971
972
973
974
975
976
977
978
979
980
981
982
983
984
985
986
987
988
989
990
991
992
993
994
995
996
997
998
999
1000
1001
1002
1003
1004
1005
1006

TABLE 5
Secondary perinatal outcomes Outcome

	Wong et al, ¹⁷ 2007	Ramphul et al, ⁸ 2014	Ghi et al, ^{xx} 2018	Barros et al, ¹⁶ 2020	Totals	RR (95% CI)	P value	I ²
Admission to NICU	NR	31/257 (12.1) vs 30/257 (11.7)	5/89 (5.6) vs 9/132 (6.8)	7/113 (6.2) vs 4/109 (3.7)	43/459 (9.4) vs 43/498 (8.6)	1.06 (0.7–1.59)	.79	0
Apgar score <7 at 5 min	0/25 (0) vs 0/25 (0)	0/257 (0) vs 2/257 (0.8)	1/89 (1.1) vs 2/132 (1.5)	2/113 (1.8) vs 1/109 (0.9)	3/484 (0.6) vs 5/532 (0.9)	0.78 (0.18–3.42)	.75	0
Neonatal trauma ^a	0/25 (0) vs 0/25 (0)	20/257 (7.8) vs 17/257 (6.6)	2/89 (2.2) vs 5/132 (3.8)	2/113 (1.8) vs 3/109 (1.8)	24/484 (4.9) vs 25/523 (4.8)	1.02 (0.59–1.78)	.93	0
Umbilical cord arterial pH <7	NR	8/203 (3.9) vs 9/191 (4.7)	1/89 (1.1) vs 2/132 (1.5)	2/113 (1.8) vs 0/109 (0)	11/405 (2.7) vs 11/432 (2.5)	0.94 (0.41–2.17)	.89	0
Composite mathematical perinatal outcome (sum of OASIS, neonatal trauma, arterial pH <7, admission to NICU and Apgar score <7)	0/25 (0) vs 0/25 (0)	72/257 (28) vs 67/257 (23.7)	13/89 (14.6) vs 21/132 (15.9)	24/113 (21.2) vs 25/109 (22.9)	109/484 (22.5) vs 113/523 (21.6)	1.02 (0.81–1.28)	.87	0
Composite perinatal outcome ^b	NR	NR	10/89 (11.2) vs 14/132 (10.6)	18/113 (15.9) vs 21/109 (19.3)	28/202 (13.9) vs 35/241 (14.5)	0.90 (0.57–1.43)	.66	0

Numbers show comparison between data on patients in which ultrasound has been used in the diagnoses of occiput position before operative vaginal delivery vs patients in which ultrasound was not used.

CI, confidence interval; NICU, neonatal intensive care unit; NR, not reported; OASIS, obstetrical anal sphincter injuries; RR, relative risk.

^a Neonatal trauma; ^b Composite perinatal outcome is the number of patients who sustained ≥ 1 of the following: OASIS or neonatal trauma (skull fractures, subgaleal hemorrhage, cephalohematoma, or any other neonatal hemorrhage), arterial umbilical cord pH <7, admission to NICU, or Apgar score <7 at 5 minutes.

Bellussi. Sonographic occiput position before operative vaginal delivery. Am J Obstet Gynecol 2021.

example, in the Cochrane meta-analysis in which forceps and vacuum extractions were compared, a failed OVD rate of 9% with forceps extraction and 14% with vacuum extraction was reported.²² Almost three-quarters of the OVDs in our meta-analysis used vacuum extraction as the primary OVD instrument and thus perhaps an OVD failure rate closer to 14% could have been expected. The lower than expected incidence of failed OVDs could be because of the selection of easier cases for inclusion in the RCT (which is unlikely given that >50% had a station $>+2$) (Table 2); because of the research settings within which the RCTs were completed that perhaps allowed a more accurate selection of women eligible for OVD or engagement with better operators; or because with time, operators are getting better at OVDs (the RCTs in the Cochrane database are all much older than those in our meta-analysis).

Conclusions and implications

These data have several clinical implications. The more accurate diagnosis of the correct occiput positions (98% correct in the sonographic group vs 82% correct in the clinical digital groups; $P=.02$) (Table 4), and the fact that in more cases in the sonographic group, the operator knew that the fetus was in occiput posterior or transverse and not, erroneously if done by clinical digital exam, in the occiput anterior position, did not help to achieve a greater number of safe and successful OVDs or to achieve any significant differences in the maternal or neonatal outcomes. This might be secondary to the fact that the operator did not change or know how to change his or her OVD technique between different occiput positions. In fact, the rates of vacuum delivery (only vacuum used), forceps delivery (only forceps use), and sequential use of instruments (vacuum or forceps first) were similar for the 2 groups. Similarly, the number of cup applications and cup detachments and the rate of more than 3 tractions were also similar for both groups.

Knowledge of the correct position does not necessarily translate into a measurable outcome benefit.²³ It is also

possible that knowledge of the occiput position may affect the operator who is performing the OVD in different ways. For example, the operator may be more confident to perform an OVD if he or she thinks the position is occiput anterior. Or the operator may be more fearful and cautious if he or she thinks the position is occiput posterior or transverse. Further research is necessary to assess the possible usefulness of other parameters (eg, station, angle of progression, head to perineum distance, deflexion, asynclitism, and others) before OVD in addition to the knowledge of occiput position.

Sonographic knowledge of the correct occiput position pre-OVD was not associated with a significant effect on failed OVDs or maternal or perinatal outcomes in women with singleton, term pregnancies with vertex presentation and usually epidural anesthesia when compared with clinical digital knowledge of the occiput position. Although a more accurate diagnosis of occiput position using ultrasound does not necessarily translate into a measurable outcome benefit as studied so far, further research is needed on possible clinical management modifications and OVD technique changes based on this more accurate sonographic knowledge of the correct occiput position.

Uncited Figure

Figure 3

REFERENCES

1. Alexander JM, Leveno KJ, Hauth JC, et al. Failed operative vaginal delivery. *Obstet Gynecol* 2009;114:1017–22.
2. Demissie K, Rhoads GG, Smulian JC, et al. Operative vaginal delivery and neonatal and

infant adverse outcomes: population based retrospective analysis. *BMJ* 2004;329:24–9.

3. Johanson RB, Menon BK. Vacuum extraction versus forceps for assisted vaginal delivery. *Cochrane Database Syst Rev* 2000;2:CD000224.

4. Murphy DJ, Liebling RE, Verity L, Swingler R, Patel R. Early maternal and neonatal morbidity associated with operative delivery in second stage of labour: a cohort study. *Lancet* 2001;358:1203–7.

5. Bultez T, Quibel T, Bouhanna P, Popowski T, Resche-Rigon M, Rozenberg P. Angle of fetal head progression measured using transperineal ultrasound as a predictive factor of vacuum extraction failure. *Ultrasound Obstet Gynecol* 2016;48:86–91.

6. Operative vaginal birth: ACOG Practice Bulletin, Number 219. *Obstet Gynecol* 2020;135:e149–59.

7. Murphy DJ, Strachan BK, Bahl R; Royal College of Obstetricians and Gynaecologists. Assisted vaginal birth: Green-Top Guideline No. 26. *BJOG* 2020;127:e70–112.

8. Ramphul M, Ooi PV, Burke G, et al. Instrumental delivery and ultrasound: a multicentre randomised controlled trial of ultrasound assessment of the fetal head position versus standard care as an approach to prevent morbidity at instrumental delivery. *BJOG* 2014;121:1029–38.

9. Akmal S, Kametas N, Tsoi E, Hargreaves C, Nicolaides KH. Comparison of transvaginal digital examination with intrapartum sonography to determine fetal head position before instrumental delivery. *Ultrasound Obstet Gynecol* 2003;21:437–40.

10. Bellussi F, Salsi G, Simonazzi G, et al. A simple sonographic finding is associated with a successful vacuum application: the fetal occiput or forehead sign. *Am J Obstet Gynecol* 2019;1:148–55.

11. Ghi T, Eggebø T, Lees C, et al. ISUOG Practice Guidelines: intrapartum ultrasound. *Ultrasound Obstet Gynecol* 2018;52:128–39.

12. Cuerva MJ, Bamberg C, Tobias P, Gil MM, De La Calle M, Bartha JL. Use of intrapartum ultrasound in the prediction of complicated operative forceps delivery of fetuses in non-occiput posterior position. *Ultrasound Obstet Gynecol* 2014;43:687–92.

13. Sainz JA, Borrero C, Aquisé A, Serrano R, Gutiérrez L, Fernández-Palacín A. Utility of

intrapartum transperineal ultrasound to predict cases of failure in vacuum extraction attempt and need of cesarean section to complete delivery. *J Matern Fetal Neonatal Med* 2016;29:1348–52.

14. Kasbaoui S, Séverac F, Aïssi G, et al. Predicting the difficulty of operative vaginal delivery by ultrasound measurement of fetal head station. *Am J Obstet Gynecol* 2017;216:507.e1–9.

15. Sainz JA, García-Mejido JA, Aquisé A, et al. Intrapartum transperineal ultrasound used to predict cases of complicated operative (vacuum and forceps) deliveries in nulliparous women. *Acta Obstet Gynecol Scand* 2017;96:1490–7.

16. Barros JG, Afonso M, Martins AT, et al. Transabdominal and transperineal ultrasound vs routine care before instrumental vaginal delivery—a randomized controlled trial. *Acta Obstet Gynecol Scand* 2020;100:1075–81.

17. Wong GY, Mok YM, Wong SF. Transabdominal ultrasound assessment of the fetal head and the accuracy of vacuum cup application. *Int J Gynaecol Obstet* 2007;98:120–3.

18. Ghi T, Dall'Asta A, Masturzo B, et al. Randomised Italian Sonography for occiput POSITION Trial ante vacuum (R.I.S.POS.T.A.). *Ultrasound Obstet Gynecol* 2018;52:699–705.

19. Henderson LK, Craig JC, Willis NS, Tovey D, Webster AC. How to write a Cochrane systematic review. *Nephrology (Carlton)* 2010;15:617–24.

20. Higgins JPT, Thomas J, Chandler J, Cumpston M, Li T, Page MJ, Welch VA, eds. *Cochrane Handbook for Systematic Reviews of Interventions*, Second edition. Chichester, England, United Kingdom: John Wiley & Sons; 2019.

21. Moher D, Liberati A, Tetzlaff J, Altman DG; Prisma Group. Preferred reporting items for systematic reviews and meta-analyses: the PRISMA statement. *Ann Intern Med* 2009;151:264–9.

22. O'Mahony F, Hofmeyr GJ, Menon V. Choice of instruments for assisted vaginal delivery. *Cochrane Database Syst Rev* 2010;11:CD005455.

23. Youssef A, Pilu G. Knowledge, understanding and fetal occiput position. *Ultrasound Obstet Gynecol* 2016;47:523–4.

1231
1232
1233
1234
1235
1236
1237
1238
1239
1240
1241
1242
1243
1244
1245
1246
1247
1248
1249
1250
1251
1252
1253
1254
1255
1256
1257
1258
1259
1260
1261
1262
1263
1264
1265
1266
1267
1268
1269
1270
1271
1272
1273
1274
1275
1276
1277
1278
1279
1280
1281
1282
1283
1284
1285
1286

000 Sonographic knowledge of occiput position to decrease failed operative vaginal delivery: a systematic review and meta-analysis of randomized controlled trials

Federica Bellussi; Daniele Di Mascio; Ginevra Salsi; Tullio Ghi;
Andrea Dall'Asta; Fabrizio Zullo; Gianluigi Pilu; Joana G. Barros;
Diogo Ayres-de-Campos; Vincenzo Berghella

Sonographic knowledge of occiput position does not decrease the incidence of failed operative vaginal deliveries.

1287
1288
1289
1290
1291
1292
1293
1294
1295
1296
1297
1298
1299
1300
1301
1302
1303
1304
1305
1306
1307
1308
1309
1310
1311
1312
1313
1314
1315
1316
1317
1318
1319
1320
1321
1322
1323
1324
1325
1326
1327
1328
1329
1330
1331
1332
1333
1334
1335
1336
1337
1338
1339
1340
1341
1342