



UNIVERSITÀ DI PARMA

ARCHIVIO DELLA RICERCA

University of Parma Research Repository

Afatinib therapy in case of EGFR G724S emergence as resistance mechanism to osimertinib

This is the peer reviewed version of the following article:

Original

Afatinib therapy in case of EGFR G724S emergence as resistance mechanism to osimertinib / Minari, R.; Leonetti, A.; Gnetti, L.; Zielli, T.; Ventura, L.; Bottarelli, L.; Lagrasta, C.; la Monica, S.; Petronini, P. G.; Alfieri, R.; Tiseo, M.. - In: ANTI-CANCER DRUGS. - ISSN 0959-4973. - 32:7(2021), pp. 758-762. [10.1097/CAD.0000000000001064]

Availability:

This version is available at: 11381/2897047 since: 2022-01-07T20:15:25Z

Publisher:

Lippincott Williams and Wilkins

Published

DOI:10.1097/CAD.0000000000001064

Terms of use:

Anyone can freely access the full text of works made available as "Open Access". Works made available

Publisher copyright

note finali coverpage

(Article begins on next page)

02 May 2026






AUTHOR QUERY FORM

**LIPPINCOTT
WILLIAMS AND WILKINS**

JOURNAL NAME: CAD

ARTICLE NO: ACD-6738

QUERIES AND / OR REMARKS

AQ1	For indexing purposes, please confirm that author names have been correctly identified as given names (blue) and surnames (red). Color in the byline will not appear on the final published version.	
AQ2	Please provide complete manufacturer's details (city, state (if USA), and country) for "Sophia Genetics"	
AQ3	Please check and validate the conflicts of interest statement.	
AQ4	Figures 1–3 are low quality (blurred/unsharp text). Please provide print quality images with minimum 300 dpi resolution, in any of the following formats: TIFF, EPS, MS Word, MS PowerPoint, MS Excel, AI - Adobe Illustrator 10.0, PSD - Adobe PhotoShop 7.0, JPEG, Acrobat PDF.	
AQ5	As colour figure(s) are present in your article, there is a \$1000/article charge for them to be produced in colour in the final print and online versions. Please let me know how you wish to proceed.	

Afatinib therapy in case of *EGFR* G724S emergence as resistance mechanism to osimertinib

Roberta Minari^a, Alessandro Leonetti^a, Letizia Gnetti^b, Teresa Zielli^a, Luigi Ventura^c, Lorena Bottarelli^b, Costanza Lagrasta^b, Silvia La Monica^d, Pier Giorgio Petronini^d, Roberta Alfieri^d and Marcello Tiseo^{a,d}

AQ1

Osimertinib is a third-generation epidermal growth factor receptor-tyrosine kinase inhibitor (EGFR-TKI) used both as the first-line treatment of *EGFR*-mutated non-small cell lung cancer patients and in second-line after T790M-positive disease progression to first- or second-generation TKIs. Unfortunately, patients unavoidably experience disease progression to osimertinib and the current research is focused on resistance mechanisms and the relative therapeutic strategy. We report the case of a patient with advanced *EGFR*-mutated (exon 19 deletion and T790M-positive) non-small cell lung cancer who developed disease progression to osimertinib characterized by the loss of T790M concurrently with the emergence of G724S *EGFR* mutation, which was tackled by subsequent afatinib treatment. Next-generation sequencing molecular study of rebiopsy at time of progression to osimertinib revealed the persistence of *EGFR* exon 19 deletion, loss of T790M with a new G724S *EGFR* mutation; other concomitant mechanisms were excluded. Retrospective analysis of cell-free DNA revealed

the emergence of G724S *EGFR* mutation four months before the radiologically-proven disease progression. The patient, after chemotherapy, was treated with afatinib with clinical and radiological benefit. Our case report contributes to increase the knowledge on acquired resistance mechanisms to osimertinib treatment, and it shows, for the first time, the efficacy of afatinib in the case of T790M loss and emergence of G724S *EGFR* mutation. *Anti-Cancer Drugs XXX: 000–000* Copyright © 2021 Wolters Kluwer Health, Inc. All rights reserved.

Anti-Cancer Drugs 2021, XXX:000–000

Keywords: afatinib, *EGFR*-mutated non-small cell lung cancer, G724S, osimertinib

^aMedical Oncology Unit, ^bPathology Unit, Department of Medicine and Surgery, ^cThoracic Surgery, Department of Medicine and Surgery and ^dDepartment of Medicine and Surgery, University of Parma, Parma, Italy

Correspondence to Alessandro Leonetti, MD, Medical Oncology Unit, University Hospital of Parma, Via Gramsci 14, 43126 Parma, Italy
Tel: +39 0521 702316; fax: +39 0521 995448; e-mail: aleonetti@ao.pr.it

Received 19 September 2020 Revised form accepted 1 February 2021

Introduction

Osimertinib is a third-generation epidermal growth factor receptor-tyrosine kinase inhibitor (EGFR-TKI) highly selective for *EGFR* with both activating and T790M mutations. Osimertinib treatment represents the standard of care for *EGFR*-mutated non-small cell lung cancer (NSCLC) patients, both in first-line and in second-line after the failure of early-generation EGFR-TKIs (gefitinib, erlotinib and afatinib) due to the acquisition of a new point *EGFR* T790M mutation [1].

Unfortunately, cancer cells develop resistance to osimertinib with different mechanisms that have been divided into *EGFR*-dependent (tertiary *EGFR* mutations, *EGFR* amplification, loss of T790M) and *EGFR*-independent (*HER2/MET/FGFR* amplification, small-cell lung cancer transformation and *KRAS/BRAF* mutations) [2]. Understanding the mechanisms of acquired resistance to osimertinib and establishing an adequate following therapy constitute an emerging clinical need.

Here, we report the case of a patient who benefited from afatinib after the failure of second-line osimertinib, and whose postprogression tissue rebiopsy to osimertinib

showed the occurrence of G724S mutation with loss of T790M.

Case and methods

Methods

The patient was treated at the Medical Oncology Unit of University-Hospital of Parma. The patient signed an informed consent form before any diagnostic and therapeutic procedure. The patient was enrolled in an approved local protocol of cell-free DNA (cfDNA) monitoring in advanced NSCLC patients undergoing targeted therapies. According to this, samples for cfDNA analysis were taken at baseline of osimertinib therapy, every 2 months and at the same time-points of imaging reassessments. DNA was extracted from tissue biopsy and from 3 ml of plasma with proper kit (GeneRead DNA FFPE kit and QIAmp Circulating nucleic acid kit, Qiagen, Valencia, California, USA) and analyzed for *EGFR* mutational status (therascreen *EGFR* RGQ PCR kit and therascreen *EGFR* Plasma RGQ PCR kit, Qiagen). Next-generation sequencing (NGS) was performed with Solid Tumor Solution (Sophia Genetics) on the MiSeq platform (Illumina, San Diego, California,

AQ2

USA). Digital droplet PCR (ddPCR) was performed on cfDNA to assess the presence of *EGFR* mutation during treatment. Fluorescent in situ hybridization (FISH) analysis of *MET* and *HER2* was assessed on histologic samples to evaluate their amplification. Tumors were defined amplified if *MET*/CEP7 and *HER2*/CEP17 ratio was ≥ 2 .

Case report

F1

In 2016, a 51-year-old never smoker male, without a significant medical history, underwent neoadjuvant chemotherapy followed by a left upper lobectomy for lung adenocarcinoma (pathological stage T3N2). One year later, lung and bone recurrence occurred. Considering the presence of *EGFR* mutation (exon 19 deletion), the patient received erlotinib treatment with monthly zoledronic acid, achieving tumor response. Erlotinib was continued with cutaneous toxicity until February 2019, when a worsening of lung lesions appeared (Fig. 1a). Due to the presence of T790M mutation on liquid biopsy, second-line treatment with osimertinib was started, with partial tumor response (Fig. 1b). After 8 months of osimertinib, characterized by grade 1–2 cutaneous toxicity, in October 2019, lung and liver progression occurred

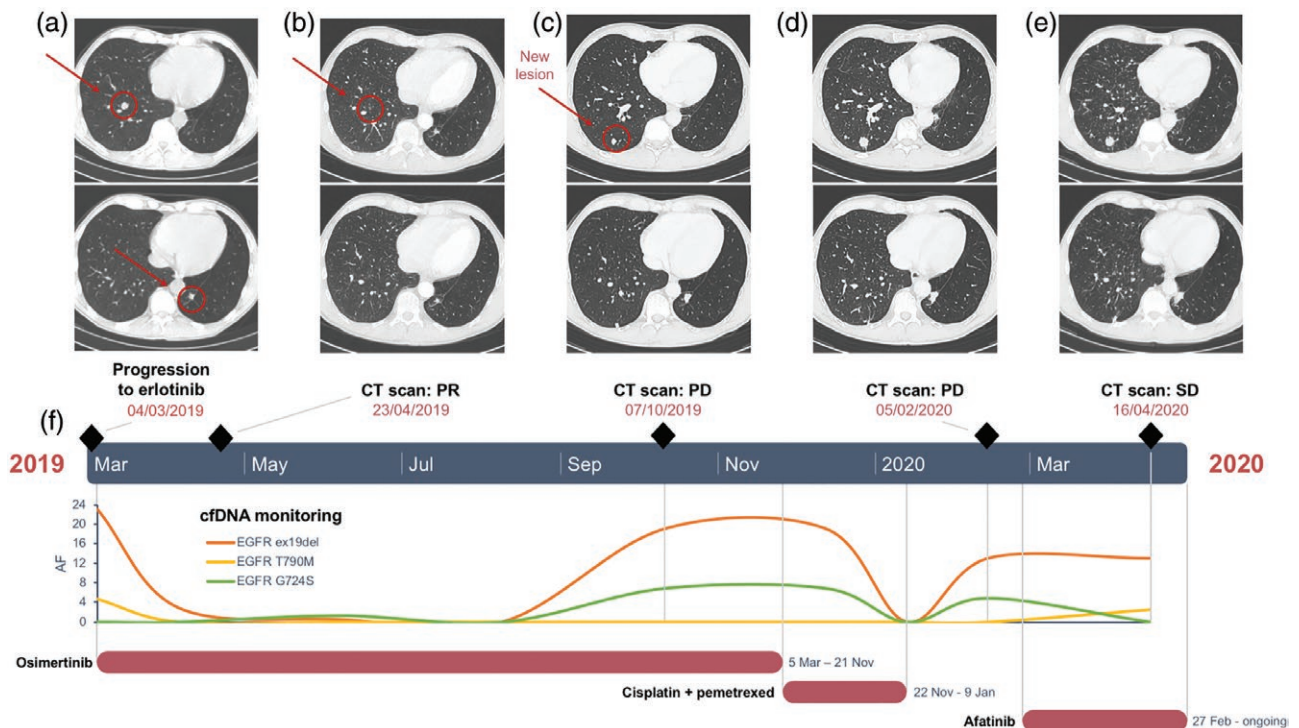
(Fig. 1c). For this reason, the patient underwent a new surgical lung biopsy with the aim of investigating resistance to osimertinib. Adenocarcinoma histology was confirmed (Fig. 2), and NGS study revealed persistence of *EGFR* exon 19 deletion [p.(Glu746_Ser752delinsVal), allelic frequencies (AF) = 67.1], loss of T790M with a new G724S *EGFR* mutation (AF = 20.9) (Fig. 3a). Other concomitant resistance mechanisms were excluded (also FISH for *MET* and *HER2* were negative; data not shown). In order to exclude ab initio presence of *EGFR* G724S, NGS on both pre-osimertinib cfDNA and diagnostic tissue was performed, confirming *EGFR* p.(-Glu746_Ser752delinsVal) (AF = 26.1) plus p.(T790M) (AF = 2.9) on pre-osimertinib cfDNA and only *EGFR* p.(Glu746_Ser752delinsVal) (AF = 28) on tissue biopsy (Fig. 3b, c).

F2

F3

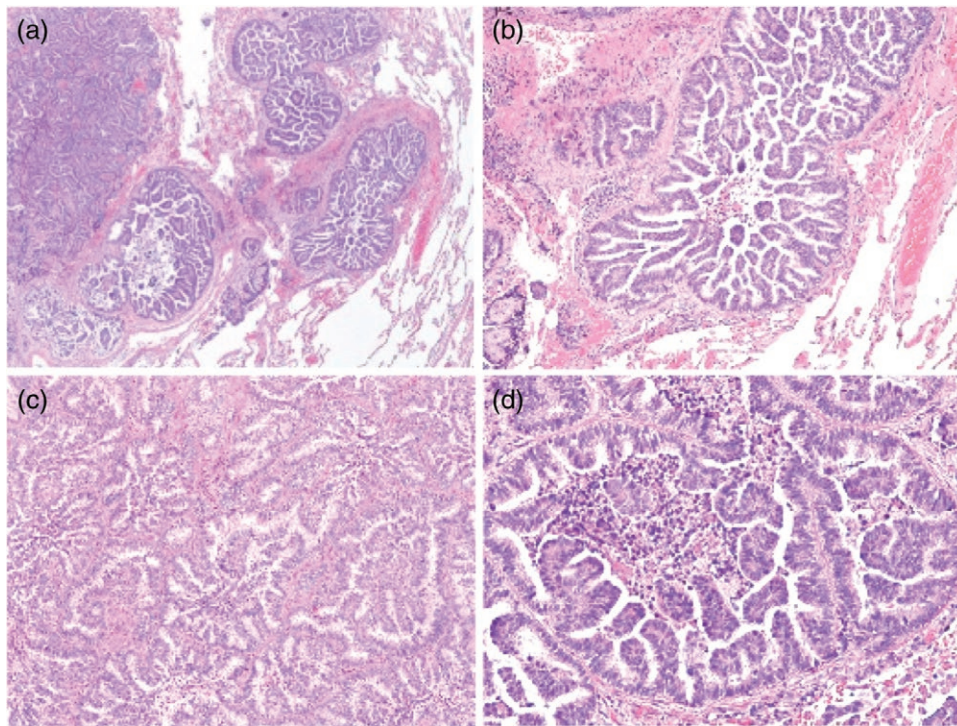
In November 2019, the treatment with osimertinib was interrupted, and carboplatin-pemetrexed chemotherapy was started. The patient received three cycles of chemotherapy, but unfortunately, a clinical (onset of asthenia, cough and dyspnea) and radiological (lung and brain progression) worsening were evidenced (Fig. 1d).

Fig. 1



Disease evolution under different treatments and correlation with molecular findings. (a) CT scan revealed progression of disease after erlotinib treatment for the onset of T790M mutation in a patient with exon 19 deletion *EGFR*-mutated NSCLC; (b) the patient achieved a partial response to osimertinib treatment; (c) CT scan after eight months of osimertinib treatment showed progression of lung disease; (d) CT scan performed after three cycles of cisplatin-pemetrexed revealed further progression of existing lesions; (e) the patient achieved stability of disease following afatinib monotherapy; (f) retrospective cfDNA analysis of *EGFR* activating, T790M and G724S mutations. ddPCR revealed the emergence of G724S *EGFR* mutation 4 months before the confirmed progression to osimertinib. After the starting of afatinib, the *EGFR* G724S clone was abrogated. CT, computed tomography; NSCLC, non-small cell lung cancer.

Fig. 2



Histopathological analysis of lung biopsy at the time of progression to osimertinib. (a) Image shows hematoxylin–eosin staining of lung adenocarcinoma with a solid (top left) and micropapillary (bottom right) pattern (magnification 10×); (b) cellular tufts with absence of fibrovascular core (magnification 20×); (c) tumor cells surrounded by stroma and consisting of a papillary component with tufts surrounded by lacunar spaces (magnification 40×); (d) small and cuboidal tumor cells with minimal nuclear atypia organizing in micropapillary tufts float in the alveolar space (magnification 40×).

Considering the emergence of G724S *EGFR* mutation with concomitant loss of T790M, and the preclinical data available about potential activity of second-generation *EGFR*-TKIs in this molecular portrait [3,4], single-agent afatinib was started. Since the patient experienced previous cutaneous toxicity, a reduced dose of 30 mg was administered. Brain lesions were treated with stereotactic radiotherapy. Rapid clinical improvement was achieved after 2 weeks, and it was confirmed by computed tomography (CT) scan after 2 months of afatinib treatment (Fig. 1e).

Retrospective analysis of *EGFR* mutations on cfDNA evidenced G724S appearance 4 months before osimertinib progression (Fig. 1f). After a clearance induced by chemotherapy treatment, *EGFR* activating and G724S mutations reappeared, concomitantly to radiological disease progression. G724S clone disappeared as afatinib treatment was initiated, concomitantly with a new onset of T790M and the persistence of *EGFR* activating mutation.

Discussion


Investigating resistance mechanisms to osimertinib represents a crucial step after its failure in order to find

novel potential therapeutic approaches to counteract tumor resistance. Here, we reported a case of acquired resistance to osimertinib mediated by the loss of *EGFR* T790M and acquisition of G724S mutation.

EGFR G724S variant has already been described in the literature as a potential driver of acquired resistance to *EGFR*-TKIs [3–10]. G724S occurs in the P-loop of *EGFR* kinase domain, and it confers TKI resistance by either changing the protein structure, enhancing ATP affinity or stabilizing active mutation [3,4]. Regarding osimertinib, structural analyses demonstrated that G724S mutation induces a conformational change in the receptor, which impairs the drug binding [3,4].

Even though the incidence of this rare mutation upon osimertinib treatment is currently unknown, due to the relatively limited evidence available [3–9], it is supposed that G724S-mediated resistance acts in an allele-specific manner since it preferentially emerges in the context of exon 19 deletion rather than L858R mutation [4]. Moreover, the most frequent exon 19 deletion variant associated with G724S is p.(Glu746_Ser752delinsVal), as reported in four case reports [3,5,6,9], in about 50% of cases studied by Brown *et al.* [4] and lastly in our patient.

Fig. 3



Study of resistance mechanism to osimertinib: results of next-generation sequencing. The Integrated Genome Viewer revealed the mutational status of (a) tumor at osimertinib disease progression; (b) cell-free DNA collected at the progression of erlotinib treatment; (c) diagnostic biopsy.

Interestingly, it has been demonstrated that second-generation EGFR-TKIs retains kinase affinity in G724S mutants and afatinib was successful in overcoming G724S-mediated resistance to osimertinib in vitro [4]. To date, two cases of *EGFR* G724S-positive patients treated with afatinib have been reported [6,9]. Peled *et al.* [6] combined afatinib to ongoing osimertinib therapy in a patient with multiple *EGFR* mutations, leading to a significant reduction of preexisting plasmatic G724S clone. On the other hand, the case presented by Fang *et al.* was a T790M-negative, G724S-positive patient who received afatinib monotherapy after third-line osimertinib, reaching a partial disease response. Similarly, afatinib induced a clinical and radiological benefit in our G724S-positive case, demonstrating for the first time its activity as a single agent in case of osimertinib progression concurrently with loss of *EGFR* T790M. Afatinib's effectiveness resulted in rapid clinical benefit and the abrogation of *EGFR* G724S clone (Fig. 1f). Nevertheless, the persistence of *EGFR* activating and the re-onset of T790M mutation during afatinib could foresee a forthcoming disease progression. In this possible future scenario, the reintroduction of osimertinib in combination with afatinib could be envisaged.

Conclusion

In conclusion, we firstly reported the efficacy and safety of afatinib in case of T790M loss and emergence of G724S

EGFR mutation under osimertinib treatment. Moreover, concordantly with previous evidence, our report underlines as the type of activating mutation, in this case, ex19del p.(Glu746_Ser752delinsVal), could predict the following resistance mechanism to osimertinib. In the near future, serial cfDNA analysis could be a useful tool to guide treatment choice, depending on the abrogation or persistence of a specific *EGFR* mutation in the blood, in order to control different disease clones.

Acknowledgements

This work was supported by Associazione Italiana per la Ricerca sul Cancro (AIRC), Milan Grant IG2017-20074 (P.I. Marcello Tiseo).

Conflicts of interest

There are no conflicts of interest.

AQ3

References

- 1 Planchard D, Popat S, Kerr K, Novello S, Smit EF, Faires-Finn C, *et al.*; ESMO Guidelines Committee. Metastatic non-small cell lung cancer: ESMO Clinical Practice Guidelines for diagnosis, treatment and follow-up. *Ann Oncol* 2018; **29**:iv192–iv237.
- 2 Leonetti A, Sharma S, Minari R, Perego P, Giovannetti E, Tiseo M. Resistance mechanisms to osimertinib in EGFR-mutated non-small cell lung cancer. *Br J Cancer* 2019; **121**:725–737.
- 3 Fassunke J, Müller F, Keul M, Michels S, Dammert MA, Schmitt A, *et al.* Overcoming EGFRG724S-mediated osimertinib resistance through unique binding characteristics of second-generation EGFR inhibitors. *Nat Commun* 2018; **9**:4655.
- 4 Brown BP, Zhang YK, Westover D, Yan Y, Qiao H, Huang V, *et al.* On-target resistance to the mutant-selective EGFR inhibitor osimertinib can develop

- in an allele-specific manner dependent on the original EGFR-activating mutation. *Clin Cancer Res* 2019; **25**:3341–3351.
- 5 Zhang Y, He B, Zhou D, Li M, Hu C. Newly emergent acquired EGFR exon 18 G724S mutation after resistance of a T790M specific EGFR inhibitor osimertinib in non-small-cell lung cancer: a case report. *Onco Targets Ther* 2019; **12**:51–56.
 - 6 Peled N, Roisman LC, Miron B, Pfeffer R, Lanman RB, Ilouze M, *et al.* Subclonal therapy by two EGFR TKIs guided by sequential plasma cell-free DNA in EGFR-mutated lung cancer. *J Thorac Oncol* 2017; **12**:e81–e84.
 - 7 Oztan A, Fischer S, Schrock AB, Erlich RL, Lovly CM, Stephens PJ, *et al.* Emergence of EGFR G724S mutation in EGFR-mutant lung adenocarcinoma post progression on osimertinib. *Lung Cancer* 2017; **111**:84–87.
 - 8 Schoenfeld AJ, Chan JM, Rizvi H, Rekhtman N, Daneshbod Y, Kubota D, *et al.* Tissue-based molecular and histological landscape of acquired resistance to osimertinib given initially or at relapse in patients with EGFR-mutant lung cancers. *J Clin Oncol* 2019; **37** (Suppl 15):9028–9028.
 - 9 Fang W, Huang Y, Gan J, Zheng Q, Zhang L. Emergence of EGFR G724S after progression on osimertinib responded to afatinib monotherapy. *J Thorac Oncol* 2020; **15**:e36–e37.
 - 10 Li J, Wang Z, Groen HJM, Zhao J, Wang P, Zhang C, *et al.* Uncommon EGFR G724S mutations arise in non-small-cell lung cancer patients with acquired resistance to first-generation EGFR-TKIs. *Lung Cancer* 2018; **118**:173–175.