Differences in femoral morphology between sheep (Ovis aries) and goat (Capra hircus): macroscopic and microscopic observations

Zoomorphology

Differences in femoral morphology between sheep (Ovis aries) and goat (Capra hircus): macroscopic and microscopic observations

--Manuscript Draft--

Manuscript Number:	
Full Title:	Differences in femoral morphology between sheep (Ovis aries) and goat (Capra hircus): macroscopic and microscopic observations
Article Type:	Original Article
Keywords:	sheep; goat; femur; comparative anatomy; bone tissue
Corresponding Author:	Marco Zedda Dipartimento di Medicina Veterinaria, Università di Sassari, Italy Sassari, ITALY
Corresponding Author Secondary Information:	
Corresponding Author's Institution:	Dipartimento di Medicina Veterinaria, Università di Sassari, Italy
Corresponding Author's Secondary Institution:	
First Author:	Marco Zedda
First Author Secondary Information:	
Order of Authors:	Marco Zedda
	Maria Rita Palombo
	Desiré Brits
	Marcella Carcupino
	Vijay Sathé
	Antonio Cacchioli
	Vittorio Farina
Order of Authors Secondary Information:	
Funding Information:	
Abstract:	It is often difficult, if not impossible, to separate postcranial elements of species, such as sheep and goats found in archaeological contexts. However, distinguishing between the skeletal remains of these species is important as it can provide a better understanding of the role of these animals in prehistoric economies. Therefore, the aim of this study was to assess morphological and morphometric differences of the microscopic and macroscopic characteristics of the femur of sheep and goats, to be used to distinguish between these species. About a hundred of adult sheep and goat femora were examined. Histological sections were prepared from the smallest breadth of the femoral midshaft and the bone tissue of each species was described. Measurements of osteons and Haversian canals were also collected. Microscopic results indicated similar bone tissue and a great degree of overlap in measurements between the species which did not allow for assertive separation. Qualitative and quantitative macroscopic differences in the femoral shaft and epiphyses were assessed. Differences related to the different behavioral and locomotion patterns of each species were observed and can thus be considered useful to distinguish between sheep and goat femora found in archaeological and/or fossil assemblages.

Differences in femoral morphology between sheep (*Ovis aries*) and goat (*Capra hircus*): macroscopic and microscopic observations

Marco Zedda[1], Maria Rita Palombo[2], Desiré Brits[3], Marcella Carcupino[4], Vijay Sathé[5], Antonio Cacchioli[6], Vittorio Farina[1]

[1]Dipartimento di Medicina Veterinaria, Università di Sassari, via Vienna 2, 07100 Sassari, Italy;
[2]Dipartimento di Scienze della Terra, La Sapienza Università di Roma, piazzale Aldo Moro 5, 00185 Roma, Italy;
[3]School of Anatomical Sciences, Faculty of Health Sciences, University of the Witwatersrand, 7 York Road, 2193 Parktown, Johannesburg, Republic of South Africa;
[4]Dipartimento di Scienze della Natura e del Territorio, Università di Sassari, via Muroni 25, 07100 Sassari, Italy;
[5]Department of Archaeology, Palaeontology Laboratory, Deccan College, Yerawada, Pune, Maharashtra 411006, India;
[6]Dipartimento di Scienze Medico-Veterinarie, Università di Parma, Via del Taglio 8, 43126 Parma, Italy.

Corresponding Author:

Marco Zedda

Department of Veterinary Medicine

University of Sassari

via Vienna 2

07100 Sassari, Italy

Tel. +39 079229583

Fax +39 079229432.

E-mail mzedda@uniss.it

Abstract

It is often difficult, if not impossible, to separate postcranial elements of species, such as sheep and goats found in archaeological contexts. However, distinguishing between the skeletal remains of these species is important as it can provide a better understanding of the role of these animals in prehistoric economies. Therefore, the aim of this study was to assess morphological and morphometric differences of the microscopic and macroscopic characteristics of the femur of sheep and goats, to be used to distinguish between these species. About a hundred of adult sheep and goat femora were examined. Histological sections were prepared from the smallest breadth of the femoral midshaft and the bone tissue of each species was described. Measurements of osteons and Haversian canals were also collected. Microscopic results indicated similar bone tissue and a great degree of overlap in measurements between the species which did not allow for assertive separation. Qualitative and quantitative macroscopic differences in the femoral shaft and epiphyses were assessed. Differences related to the different behavioral and locomotion patterns of each species were observed and can thus be considered useful to distinguish between sheep and goat femora found in archaeological and/or fossil assemblages.

Keywords: sheep, goat, femur, comparative anatomy, bone tissue

Introduction

The study of similarities and differences in body structures and functional morphology of bones, shown by closely related mammal species, may provide a better understanding of the adaptive changes that the focal species have undergone in the course of their evolution from a common ancestor. The morphological and biometrical comparison of bones and teeth coming from archaeological excavations represents the main procedure followed in zooarchaeological investigations. The identification of both domestic and wild species is of great importance for any further analysis aimed at palaeoeconomical study and/or palaeoecological reconstruction.

This is the case, for instance, of ovicaprids including sheep (*Ovis aries*) and goats (*Capra hircus*), whose presence has been documented in archaeological contexts of a variety of human civilizations throughout prehistoric times (Buckley et al. 2010; Zeder and Lapham 2010), but whose identification may be difficult, if not impossible, when cranial elements are missing. The identification of sheep and goat postcranial bones found in archaeological faunal assemblages may be problematic because they belong to the Caprini tribe (sensu Ropiquet

and Hassanin 2005), which is considered rather morphologically conservative (Matthee and Davis 2001). Although sheep and goats may be herded and bred together for the same economical purposes, the species show significant differences in environmental tolerances, feeding preferences, facility of control, reproductive characteristics and range of products (Halstead et al. 2002).

Skeletal elements are often ascribed to an undefined taxonomical category, including sheep and goats, differently named e.g. sheep/goat, caprines, ovicaprids, *Ovis vel Capra* among others (Davis 1985; von den Driesch and Wodtke 1997; Campbell et al. 1999; Croft 2003). Analysing a data set coming from such an artificial category may lead to a number of erroneous interpretations, as regards, for instance, to mortality profiles and population structures, which are very useful in understanding breeding managements. So, an illusory composite scenario is created, which is not valid for any species (Halstead et al. 2002). This problem is particularly acute in areas, such as the Mediterranean and Near East, where both sheep and goats have been the major components of livestock populations for a long time. Unambiguous identification of the archaeological remains of domestic sheep and goats may have profound implications for a better understanding of the use of domestic animals in prehistoric economies (Buckley et al. 2010).

Through time, zooarchaeologists have been proposing a number of comparative anatomical criteria in order to differentiate the two species. These criteria are based on discriminant morphological and biometrical traits of teeth, and cranial and post-cranial bones defined on the basis of the analysis of faunal assemblages from a wide variety of temporal and geographical contexts (Zeder and Lapham 2010). The first description of differences between sheep and goat bones goes back to 1891 (Cornevin and Lesbre 1891). About 70 years later, Boessneck et al. (1964) published criteria for a morphological distinction between the adult skeletons of these species. The latter work can be considered a milestone in this field. Successively, many papers have dealt with this issue, mainly basing the identification of sheep and goats on dental (Payne 1985; Helmer 2000; Halstead et al. 2002; Zeder and Pilaar 2009) and skeletal morphology (Schramm 1967; Kratochvil 1969; Boessneck 1970; Barone 2010; Prummel and Frisch 1986; Clutton-Brock et al. 1990; Helmer and Rocheteau 1994; Zeder and Lapham 2010). Morphometrical studies are also available to distinguish sheep and goat long bones, though metapodial bones are considered the most useful (Schramm 1967; Payne 1969; Teichert 1975; Pourlis et al. 2014).

Many studies on bone microstructure were performed to describe histological features of sheep and goat bones. In particular, the humerus and metapodial bones (Gudea and Stefan 2013), ulna (Metz et al. 2003), femur (Martiniaková et al. 2007a, b; Brits et al. 2014; Giua et al. 2014) and calcaneus (Skedros et al. 1994; Skedros

2005) of sheep have been studied. Conversely, less data related to the histological structure of the humerus and metapodial bones (Gudea and Stefan 2013) and femur (Mayya et al. 2013) are available for goats.

In recent decades, the number of studies to distinguish sheep from goat remains by means of non-morphological methods has been increasing. These studies include tooth wear and stable carbon isotopes analysis in the aims of identifying sheep and goats on the basis of their different trophic behaviour. Sheep and goats, indeed, eat different plants with different abrasion power leading to a different wear pattern (Grine et al. 1987), and a different ratio of ^{13}C and ^{12}C isotopes (Balasse and Ambrose 2005) between sheep and goats. These approaches, which are based on different vegetable diets, are of interest in zooarchaeological contexts and may be more reliable in wildlife conditions, even if they could suffer from limitations due to human-induced foddering practice (Pearson et al. 2007).

Studies based on collagen-peptide sequencing (Buckley et al. 2010) and ancient DNA (Loreille et al. 1997; Newman et al. 2002; Bar-Gal et al. 2003) can be included among the unambiguous non-morphological methods proposed to separate sheep from goats, though the reliability of the results may be affected by the degradation of collagen (Nielsen-Marsh 2002) and DNA (Willerslev and Cooper 2005) through time, as well as contamination from exogenous sources of domestic animal DNA (Haile et al. 2007) and laboratory reagents (Leonard et al. 2007).

This study aims at providing further data for the correct identification of sheep and goat by analysing femoral morphologic and morphometric characteristics. The femur, though often neglected in previous comparative studies, may be useful in defining the locomotor patterns and the habitat of extant and extinct bovids (Gentry 1970; Kappelman 1988, 1991; Kappelman et al. 1997).

Materials and methods

Our research focused on 52 femora of sheep (*Ovis aries*) and 46 femora of goats (*Capra hircus)*. Bones came from the osteological collections of the Department of Veterinary Medicine of the University of Sassari, Italy, the School of Anatomical Sciences of the University of the Witwatersrand, Johannesburg, South Africa and the Palaeontology Laboratory, Deccan College, Pune, India. The femora belong to adult animals butchered in local slaughterhouses. No evidence of skeletal pathology was detected in either species and the age, estimated on the basis of skeletal ossification (Barone 2010), ranges from 4 to10 years.

Microscopic observations

Femora were crosscut at the level of the smallest breadth of their diaphyses (midshaft) using an electrical saw to obtain 2mm thick sections. The rings were ground and thinned either using a fine sandpapering machine or handily processed by emery paper to obtain ± 50 µm thick sections. After thorough washing to remove debris, transverse sections were mounted onto glass slides with Eukitt (Merck, Darmstadt, Germany) and cover-slipped. Sections were observed and photographed by means of a Zeiss Axiophot microscope (Zeiss, Jena, Germany) at 2.5X, 10X and 20X magnifications. Bone patterns were classified following the bone tissue classification proposed by Enlow and Brown (1956). Two hundred well-defined secondary osteons surrounded by an evident cement line, were examined per species. The number of lamellae was also counted based on the position of osteocytic lacunae.

The following parameters were measured by means of Scion Image software (Scion Corporation, Frederick, MD, USA): perimeter, area, minimum and maximum diameters of secondary osteons and Haversian canals. The measurement of secondary osteon area included the Haversian canal. Only intact osteons were considered for statistical analyses.

Macroscopic observations

Anatomical terms from the Nomina Anatomica Veterinaria (2012) were employed. Bones were photographed and osteometrical measurements were taken using a micrometric caliper. In particular, height, width and length of the femoral head (caput ossis femoris) (Fig. 1a, 1b), as well as the maximum depth and the distance between the lips of the trochlea (trochlea ossis femoris) (Fig. 1c) were measured. The eccentricity of the caput femoris was also calculated in an attempt to establish possible differences between sheep and goats. Although the caput femoris of mammals could be geometrically considered as a complex triaxal ellissoid, only the eccentricity of the ellipse visible in proximal view was calculated here, in order to simplify its mathematical representation. The width and length of the caput has been considered respectively as the minor and the major semiaxis of the ellipse. The degree of eccentricity of the ellipse was calculated according to the following mathematical formula (e = eccentricity, a = major semiaxis, b = minor semiaxis):

$$e = \sqrt{1 - \frac{b^2}{a^2}}$$

The angular inclination of the caput with respect to the femoral axis, was measured by photographing the bones in two standardized positions (Bouma et al. 2013) with a digital camera (Nikon D5100, Shinjuku, Japan). Craniocaudal photographs were taken with the femoral neck aligned parallel to the examination table. Proximodistal photographs were taken directing the camera to the femoral axis (for this view both femoral condyles were rested flat on the examination table). The angular inclination of the femoral neck on the femoral axis was measured on the photographs with the GNU Image Manipulation Program 2.8 software. The protocol proposed by Bouma et al. (2014) was followed in detail. To individuate the exact position of the neck axis in a craniocaudal view, a best-fit circle along the outline of the caput and a second circle around the narrowest part of the neck were drawn. Then, a line connecting the centres of these two circles was drawn. Two angles were measured: the acute α angle formed by the intersection between the shaft axis and the neck axis (Fig. 2a), and the acute β angle formed by the intersection between the neck axis and the examination table where the condyles were rested (Fig. 2b).

Blind test and statistical analysis

In order to verify the reliability of the twelve criteria proposed to distinguish sheep and goat femora, a blind test was performed in the Department of Veterinary Medicine of the University of Sassari during the year 2015. Fourteen volunteer students attending the course of veterinary anatomy were invited, regardless of their skill level in bone recognition. Twenty femora (10 sheep and 10 goats) were chosen by an author and proposed to each analyst. Each analyst was invited to recognize sheep and goat employing Table 4. Results are reported in Table 5, where correct and wrong answers are expressed in percentage for each criterion.

Both microscopic and macroscopic measurements were used for statistical analysis. Measurements were repeated to evaluate intra-observer reliability and taken by a second researcher to evaluate inter-observer reliability. Ranges, means and standard deviations were calculated for each parameter and values were compared between sheep and goat with a Kruskal-Wallis test according to Dominguez and Crowder (2012).

Results

Microscopic observations The qualitative observations indicated that the basic microstructural patterns of bone tissue in both species can be classified as plexiform and irregular Haversian tissues (Fig. 3a, 3b), following the classification proposed by Enlow and Brown (1956). These authors report that plexiform tissue, also called fibro lamellar system, consists of primary vascular canals organized into a regular, well-defined plexus. Irregular Haversian tissue is characterized by isolated secondary osteons, generally having a direction perpendicular to the primary vascular canals.

In the majority of the sections studied the tissue patterns changed from one to the other, mainly starting from mesosteal zone, namely the area between periosteal and endosteal zones. In both species, secondary osteons were formed of 4-5 lamellae and appeared small and isolated and rarely clustered together in small groups (Fig. 3c, 3d). No differences in bone patterns were found among anterior, posterior, medial and lateral sides.

The significant differences between sheep and goat were limited to the size of secondary osteons (Table 1). Osteons were slightly larger in goats (mean maximum diameter 173 ± 41μm) than in sheep (164 ± 29μm), as well as the Haversian canals (mean maximum diameter 35 ± 8μm in goats and 24 ± 3μm in sheep). Therefore, values obtained from the area and perimeter of secondary osteons and Haversian canals were expected to be larger in goats compared to sheep. However, these values were not very dissimilar. This could be due to the fact that the minimum diameter of osteons in goats was smaller than that in sheep, because the osteons of goats were more elliptical. As a result, assessing significance at $p \leq 0.05$, none of the measurements showed any significant differences between sheep and goats, with the exception of the maximum diameters of osteons ($p < 0.03$) and Haversian canals ($p < 0.01$).

Macroscopic observations

Different morphological details were observed between sheep and goat femora, especially with regards to the proximal and distal epiphyses and the shaft. Observing the whole bone, it appears straighter in sheep than in goats, where a slight curvature both in craniocaudal and mediolateral views is appreciable (Fig. 4). In sheep, the caput shows an elliptical shape gradually passing into the fossa trochanterica. In goats, the caput is round and clearly distinguishable from the fossa trochanterica. The general appearance of the caput of sheep reminds that of cow (*Bos taurus)*. The major roundness of the caput in goats is confirmed by the measurements reported in Table 2, where the values of height, width and length are indicated. The proximal view confirms that the caput is more elliptical in sheep (mean eccentricity = 0.63) than in goats (mean eccentricity = 0.39). As is known, the

eccentricity of an ellipse is between 0 and 1 ($0 < e < 1$). When the eccentricity is 0 the figure is a circle, when the eccentricity tends toward 1, the figure becomes more elongated (elliptical). In the medial part of the caput, a distinct small pit (fovea capitis femoris) serving for the attachment of the ligamentum teres femoris of the hip joint is present. This fovea tends to show a well-defined circular shape in sheep, whereas it is frequently oval-shaped in goats.

The orientation of the neck (collum femoris) is another character that differentiates sheep from goats. When the bone is observed from a cranial or caudal view, the neck is nearly horizontal in sheep, and rather sloped in goats. Consequently, the top of the caput is in line with the trochanter major in the goat, whereas it is slightly lower in sheep (Fig. 5). These morphological features are confirmed by measuring the angle between the neck axis and the shaft axis (α angle). Indeed, the α angle is 46° (ranging from 38° to 64°) in goats and 67° (ranging from 52° to 76°) in sheep. Moreover, the neck axis is more cranially inclined in goat than in sheep. This morphological feature is consistent with the measure of the angle between the neck axis and the examination table (β angle), being its averaged amplitude 25° (ranging from 19° to 32°) in sheep and 42° (ranging from 28° to 52°) in goats (Table 2).

The shaft (corpus ossis femoris) is nearly cylindrical in both species, while the facies aspera in the caudal surface is broader in the goat, making the two species easily identifiable. A small nutrient foramen (foramen nutricium) is present in the proximal part of the cranial surface (70% of goats and 50% of sheep), or in the distal part of the caudal surface (30% of goats and 50% of sheep). In the first case, it pierces the bone in a distal direction, in the second in a proximal direction.

The main difference in the distal epiphysis is the relative deepness of the trochlea ossis femoris that is more marked in goats than in sheep (Fig. 6). The ratio between the distance of the trochlear lips and the maximum depth shows a difference of 38% in the two species (Table 3). Another interesting feature is the small synovial dimple present in the trochlea in 80% of goats. This is absent in all the examined sheep.

All these macroscopical observations are listed as twelve criteria and reported in Table 4.

Assessing significance at $p \leq 0.05$, differences in both intra-observer and inter-observer measurements were not detected ($p = 0.46$ and $p = 0.17$ respectively).

Blind test

The results of the blind test are reported in Table 5, where the percentages of the correct and wrong identifications are used as basis for evaluating the reliability degree for each criterion. The degree of reliability of each criterion to the species detection has been expressed as number of asterisks (Table 5). When the sum of the errors exceeded 30%, the reliability is poor and indicated with one asterisk. When the sum of the errors was between 10% and 30%, the reliability is good and indicated with two asterisks. When the sum of the errors was lower than 10%, the reliability is excellent and indicated with three asterisks. Five criteria out of twelve show the highest degree of reliability: the shape of the caput (criterion b), the outline of the caput (criterion c), the inclination of the neck in cranial or caudal view, that is α angle (criterion e), the inclination of the neck in proximal view, that is β angle (criterion f) end the presence of a synovial dimple in the trochlea (criterion l).

Discussion

In this work, the differences between sheep and goat femora have been pointed out, in order to identify criteria useful to distinguish unknown specimens, such as those from archaeological excavations. The results obtained by the qualitative analysis of the bone microstructure show that the basic structural patterns of femoral bone tissue can be classified as plexiform and irregular Haversian tissues, which are typical of adult ruminants. Our results confirm data reported for other bones, such as sheep calcaneus (Skedros et al. 1994; Skedros 2005; Skedros et al. 2013), sheep ulna (Metz et al. 2013), and humerus and metapodials of sheep and goat (Gudea and Stefan 2013), though there are a few differences in the described patterns. Such differences probably depend on the type of bone and the main direction and extent of mechanical loads each bone is subjected to. In particular, our results are very similar to those obtained for femora of sheep (Martiniaková et al. 2007a, 2007b; Brits et al. 2014; Giua et al. 2014), and goat (Mayya et al. 2013), though the patterns described by these researchers often include areas of primary vascular bone tissue. The presence of this last pattern and the absence of secondary osteons in sheep may be regarded as juvenile characteristics of bone tissue (Mulhern and Ubelaker 2001). In accordance with Brits et al. (2014) and unlike reports by Martiniaková et al. (2007b), no dense Haversian bone tissue, characterized by a dense concentration of secondary osteons, was detected here in sheep femora. The inconsistency among results obtained by the various researchers may depend on differences in both the age and breed of sheep. Indeed, the sheep breeds studied are Merino (Martiniaková et al. 2007a, 2007b; Brits et al. 2014), Zackel (Gudea and Stefan 2013), Dorper (Brits et al. 2014) and Sarda, as well as the wild subspecies mouflon

(Giua et al. 2014). As regards goat breeds, the Osmanabadi (Mayya et al. 2013) and a local breed of Romania (Gudea and Stefan 2013) have been described. All things considered, microscopical qualitative analysis of femora does not permit one to distinguish firmly sheep from goats.

The quantitative data concerning osteons and Haversian canals in the sheep are similar to those reported by others, though with some differences. The values of maximum and minimum diameter of Haversian canals (24 ± 3 and 22 ± 2 µm, respectively) are lower than those reported by Martiniakovà et al. (2007a, 2007b) in femora (34 ± 9 and 12 ± 3µm, respectively). Moreover, the secondary osteons described by these authors are more elliptical in shape as the values of their minimum and maximum diameter are lower (67 ± 17 µm) and higher (208 ± 70 µm) respectively than those measured in our samples (minimum diameter 135 ± 21 µm, maximum diameter 164 ± 29 µm). Conversely, our data are close to those of sheep humerus reported by Gudea and Stefan (2013). Indeed, their values differ from ours for 10% only and are here reported: Haversian canals: minimum diameter 19 ± 4µm, maximum diameter 25 ± 7µm, perimeter 70 ± 17 µm, area 364 ± 136µm^2; secondary osteons: minimum diameter 127 ± 22 µm, maximum diameter 164 ± 26 µm, perimeter 464 ± 77 µm, area 16.514 ± 6542 µm^2. As to the dimensions of osteons and Haversian canals of goat femora studied here, only the maximum and minimum diameters of secondary osteons are very similar to those from goat humeri reported by Gudea and Stefan (2013) (humerus: maximum diameter 169 ± 37 µm, minimum diameter 125 ± 18 µm). These values differ from ours for 3% only. Conversely, the maximum and minimum diameters of Haversian canals differ over 30% (humerus: maximum diameter 23 ± 5 µm, minimum diameter 18 ± 4 µm).

Secondary osteon size shows little differences between sheep and goat. In particular, the two species are similar as to the area and perimeter of secondary osteons and Haversian canals, although the maximum diameter of secondary osteons is slightly larger (+ 5%) in goat than sheep and the maximum diameter of Haversian canals is greater (+ 29%) in goat than sheep. In addition, the minimum diameter of secondary osteons is smaller in goats than sheep (- 4%), whereas the minimum diameter of Haversian canals is larger (+ 8%) in the former species. The shape of secondary osteons is slightly more elliptical in goats than sheep. Since secondary osteons are more resistant to mechanical stresses when elliptical rather than circular (Zedda et al. 2008, Zedda et al. 2015), it may be hypothesized that the femur is loaded by more intense mechanical stresses in goats than sheep. All things considered, our results indicate that the bones of sheep and goats cannot be discriminated based on quantitative analysis of femoral microstructure because the dimensions of secondary osteons and Haversian canals overlap. Indeed, the present histomorphological investigation failed to provide diagnostic elements suitable for a firm

discrimination between sheep and goat long bones as previously stated by Gudea and Stefan (2013), who focused on humeri and metapodials.

Conversely, at least twelve macroscopic diagnostic criteria which allow for the successful separation of sheep and goat femora, were illustrated. The first criterion refers to the general shape of the bone (a), six criteria to the morphological traits of the proximal epiphysis (b, c, d, e, f, g), three to the shaft (h, i, j) and finally two criteria concern the distal epiphysis (k, l). The degree of their reliability is reported in Table 5. Five criteria (b, c, e, f, l) have a high degree of reliability and are very easy to be detected. A few of these criteria were proposed in the past, however with no long-term success. Therefore these diagnostic traits were not reported in a recent review of the criteria used to identify postcranial bones in sheep and goat (Zeder and Lapham 2010). For example, the identification of the proximal segment of the femur based on the shape of the caput and its relationship to the trochanter maior was illustrated by Boessneck et al. (1964) and Boessneck (1970), but these criteria were not considered fully valid as are dependent on the age of the animal. It is worth noting that some criteria (b, e, f, k) are expressed mathematically, enabling the subjective evaluation with objective measurements. This is the case of the roundness of the caput (b). Other numerically-defined characters are the inclination of the neck on the femoral axis (e) from a cranial view (α angle), and the inclination of the neck on the median plane (f) from a proximal view (β angle). The measurements of these angles are preceded by the exact definition of the femoral neck axis. Different problems arise when efforts are made to define that exactly. In this work, a geometrically-based method has been followed adapting concepts employed in the radiographic research on human beings (Bouma et al. 2014).

An outstanding question may be if the morphological differences between the two species may depend on different locomotion habits, habitat preferences, or genetic heritage. In this regard, it is of particular interest to focus on the proximal epiphysis, as the hip joint shows numerous interspecific differences among mammals related to locomotion of the whole hindlimb (Bouma et al. 2013). According to Bouma et al. (2013), some species show a round caput, which allows for a wide range of motions in relation to the acetabulum. This is the case of the orangutan (*Pongo pygmaeus*), chimpanzee (*Pan troglodytes*), beaver (*Castor fiber*) and seal (*Phoca vitrulina*). Other species have an oval *caput*, for example, kangaroo (*Macropus giganteus*) and bison (*Bos bison*). In addition, relationships among habitat, specific pattern of locomotion and shape of the caput were suggested in Bovidae (Gentry 1970; Kappelman 1988; Rozzi and Palombo 2013; Rozzi et al. 2013). Following those authors, bovid species living in open habitats, such as savanna, depend on speed for survival, and, therefore, their caput is

expanded laterally (oval), so that the movements allowed by the hip joint are restricted to flexion/extension increasing locomotor power. In contrast, forest bovids have a marked inclination of the cranial articular surface of the caput, which is quite rounded allowing extended adduction/abduction and rotation to facilitate movements through the dense vegetation. Hence, the different shape of the caput between sheep and goats would account for some differences in their behavior. The two species examined here have been living under domestic conditions for more than 10,000 years and their habitats are different today from those of their wild ancestors. Nevertheless, a relation between locomotion and shape of the caput can be confirmed even for these two species having different patterns of locomotion. Goats have an almost spherical caput and a high range of potential movements. Indeed, they can run, jump and stand vertically in the bipedal stance to reach vegetable foods and goats climbing trees are frequently seen. In contrast, sheep have a rather oval caput and consequently show a limited pattern of locomotion. Accordingly, the greater inclination of the neck on the femoral axis (α angle) and median plane (β angle) in goats may indicate that the proximal epiphysis permits major manoeuvrability, including adduction/abduction and rotation.

Whether the different shape and position of the caput in *Ovis aries* and *Capra hircus* is dependent upon ossification processes is still an unanswered question. Of interest here is the work of Serrat et al. (2007), who assessed interspecies differences in the femoral proximal epiphysis of 70 different mammalian species on the basis of their ossification patterns. Briefly, according to those authors, in the proximal part of the femur, ossification starts with one chondroepiphysis, which subsequently separates into the trochanteric and the capital physis in some species, whereas it remains as one coalesced epiphysis in others. Artiodactyla are listed with the species showing the coalesced type of ossification. Unfortunately, no descriptions are reported for sheep and goats.

Moreover, the marked deepness of goat trochlea can be related to the pattern of locomotion of this species, as the knee joint is well preserved during movements of adduction/abduction of the hindlimb.

Conclusions

In this work, femora of domestic *Ovis aries* and *Capra hircus* have been compared in order to detect morphometric and morphologic differences useful to the taxonomic identification of the two species. Qualitative and quantitative microscopic investigations, failed to be conclusive. Conversely, significant differences were

detected during macroscopic observations and twelve criteria were defined which successfully allowed for the correct identification of domestic sheep and goats. Some of these morphologic differences, such as the shape and position of the caput and the deepness of the trochlea, are dependent upon the different locomotion patterns of sheep and goats. The results obtained are useful for distinguishing these two species in archaeological/fossil assemblages. The suggested morphological criteria refer to both the proximal and distal epiphyses and consequently can be successfully applied on incomplete zooarchaeological and paleontological remains.

Compliance with ethical standards

Funding: This study was funded by the Fondazione Banco di Sardegna.

Conflict of Interest: The authors declare that they have no conflict of interest.

References

Balasse M, Ambrose S H (2005). Distinguishing sheep and goats using dental morphology and stable carbon isotopes in C4 grassland environments. J Archaeol Sci 32:691-702

Bar-Gal G K, Ducos P, Horwitz, L K (2003). The application of ancient DNA analysis to identify neolithic Caprinae: a case study from the site of Hatoula, Israel. Int J Osteoarchaeol 13:120-131

Barone R (2010). Anatomie comparée des mammifères domestiques. Tome I, Osteologie. Vigot, Paris.

Boessneck J, Müller H H, Teichert M (1964). Osteologische Unterscheidungmerkmale zwischen Schaf (*Ovis aries* Linné) und Ziege (*Capra hircus* Linné). Kühn-Archiv 78:1-129

Boessneck J (1970). Osteological differences between sheep (*Ovis aries* Linné) and goats (*Capra hircus* Linné). In: Brothwell D, Higgs E (eds) Science in Archaeology Praeger, London, New York, pp 331-358.

Bouma H W, De Boer S S, De Vos J, Van Kampen P M, Hogervorst A (2013). Mammal hip morphology and function: coxa recta and coxa rotunda. Anat Rec 296:250-256

Bouma, H, Slot N-J, Toogood P, Pollard T, Van Kampen P, Hogervorst T (2014). Where is the neck? Alpha angle measurement revisited. Acta Orthopaed 85:147-151

Brits D, Steyn ML, L'Abbé EN (2014). A histomorphological analysis of human and non-human femora. Int J Legal Med 128:369-377

Buckley M, Kansa S W, Howard S, Campbell, Thomas-Oates J, Collins M (2010). Distinguishing between archaeological sheep and goat bones using a single collagen peptide. J Archaeol Sci 37:13-20

Campbell S, Carter E, Healey E, Anderson S, Kennedy A, Whitcher S. (1999). Emerging complexity on the Kahramanmaras plain, Turkey: the Domuztepe project, 1995-1997. Am J Archaeol 103:395-418

Clutton-Brock J, Dennis-Bryan K, Armitage P L (1990). Osteology of the Soay Sheep. Bulletin of the British Museum of Natural History (Zoology) 56:1-56

Cornevin C, Lesbre F-X (1891). Caractères ostéologiques différentiels de la chévre et du mouton. Bulletin de la Société d'Anthropologie de Lyon 10:47-73

Croft P (2003). The animal bones. In: Peltenburg E (ed) The colonisation and settlement of Cyprus: investigations at Kissonerga–Mylouthkia. Astrom, Savedalen, pp 49-56.

Davis S J M (1985). A preliminary report of the fauna from Hatoula: a Natufian Khiamian (PPNA) site near Latroun, Israel. In: Lechevallier M, Ronen A (eds), Le Site Natoufien–Khiamien de Hatoula Press de Latroun, Israel, vol. 1. Les Cahiers de Recherche du Centre de Recherche française de Jerusalem, Association Paleorient, Paris, pp 71-98.

Dominguez VM, Crowder CM (2012) The utility of osteon shape and circularity for differentiating human and non-human Haversian bone. Am J Phys Anthropol 149:84-91

Enlow D H, Brown SO (1956). A comparative histological study of fossil and recent bone tissues. Part I. Texas J Sci 8:405-443

Gentry AW (1970). The Bovidae (Mammalia) of the Fort Ternan fossil fauna. In: Leakey L S B,. Savage RJG

(eds), Fossil Vertebrates of Africa. Academic Press, London, pp 243-323.

Giua S, Farina V, Cacchioli A, Ravanetti F, Carcupino M, Mohadero Novas M, Zedda M (2014). Comparative histology of the femur between mouflon (Ovis aries musimon) and sheep (Ovis aries aries). J Biol Res 87:74-77

Grine F E, Krause D W, Fosse G Jungers W L (1987). Analysis of individual, intraspecific and interspecific variability in quantitative parameters of caprine tooth enamel structure. Acta Odontol Scand 45:1-23

Gudea A, Stefan A C (2013). Histomorphometric, fractal and lacunarity comparative analysis of sheep (*Ovis aries*), goat (*Capra hircus*) and roe deer (*Capreolus capreolus*) compact bone samples. Folia Morphol 72: 239-248

Haile J, Holdaway R, Oliver K, Bunce M, Gilbert M T P, Nielsen R, Munch K, Ho S Y W, Shapiro B, Willerslev E (2007). Ancient DNA chronology within sediment deposits: are paleobiological reconstructions possible and is DNA leaching a factor? Mol Biol Evol 24:982-989

Halstead P, Collins P, Isaakidou V (2002). Sorting the sheep from the goats: morphological distinctions between the mandibles and mandibular teeth of adult Ovis and Capra. J Archaeol Sci 29:545-553

Helmer D (2000). Discrimination des genres Ovis et Capra à l'aide des prémolaires inférieures 3 et 4 et interpretation des ages d'abbatage: l'example de Dikili Tash (Grèce). Anthropozoologica 31 Ibex J Mountain Ecology 5:29-38

Helmer D, Rocheteau M (1994). Atlas du squelette appendiculaire des principaux genres Holocenes de petits ruminants du nord de la Mediterranee et de procheorient (*Capra, Ovis, Rupicapra, Capreolus, Gazella*). Fiches d'ostéologie animale pour l'archéologie. Série B: Mammifères. Centre de recherches archéologiques du CNRS, APDCA, Juan-Les-Pins, pp 3-21.

Kappelman J (1988). Morphology and locomotor adaptations of the bovid femur in relation to habitat. J Morphol 198:119-130

Kappelman J (1991). The paleoenvironment of Kenyapithecus at Fort Ternan. J Hum Evol 20:95-129

Kappelman J, Plummer T, Bishop L, Appleton A D, Appleton S (1997). Bovids as indicators of Plio-Pleistocene paleoenvironments in East Africa. J Hum Evol 32:229-256

Kratochvil Z (1969). Species criteria on the distal section of the tibia in *Ovis ammon F. aries* L. and *Capra aegagrus F. hircus* L. Acta Vet Brno 38:483-490

Leonard J A, Shanks O, Hofreiter M, Kreuz E, Hodges L, Ream W, Wayne R K, Fleischer R C (2007). Animal DNA in PCR reagents plagues ancient DNA research. J Archaeol Sci 34:1361-1366

Loreille O, Vigne J D, Hardy C, Callou C, Treinen-Claustre F, Dennebouy N, Monnerot M (1997). First distinction of sheep and goat archaeological bones by the means of their fossil mtDNA. J Archaeol Sci 24:33-37

Martiniaková M, Grosskopf B, Omelka R, Dammers K, Vondráková M, Bauerová M (2007a). Histological study of compact bone tissue in some mammals: a method for species determination. Int J Osteoarchaeol 17:82-90

Martiniaková M, Grosskopf B, Omelka R, Vondráková M Bauerová M (2007b). Histological analysis of ovine compact bone tissue. J Vet Med Sci 69:409-411

Matthee C A, Davis S K (2001). Molecular Insights into the Evolution of the Family Bovidae: A Nuclear DNA Perspective. Mol Biol Evol 18:1220-1230

Mayya A, Banerjee A, Rajesh R (2013). Mammalian cortical bone in tension is non-Haversian. Sci Rep 3:2533

Metz L N, Martin B, Turner S (2003). Histomorphometric analysis of the effects of osteocyte density on osteonal morphology and remodelling. Bone 33:753-759

Mulhern D M, Ubelaker D H (2001). Differences in osteon banding between human and nonhuman bone. J Forensic Sci 46:220-222

Nielsen-Marsh C (2002). Biomolecules in fossil remains. Biochem 12-14

Newman M E, Parboosingh J S, Bridge P J, Ceri H (2002). Identification of archaeological animal bone by PCR/DNA analysis. J Archaeol Sci 29:77-84

Nomina Anatomica Veterinaria, Fifth Edition by International Committee on Veterinary Gross Anatomical Nomenclature 2012. Hannover, Columbia, Ghent, Sapporo.

Payne S (1985). Morphological distinctions between the mandibular teeth of young sheep, *Ovis* and goats, *Capra*. J Archaeol Sci 12:139-147

Payne S (1969). A metrical distinction between sheep and goat metacarpals. In: Ucko P J, Dimbleby G W (eds.): The Domestication and Exploitation of Plants and Animals,, Duckworth, London, pp 295-306.

Pearson J A, Buitenhuis H, Hedges R E M, Martin L, Russell N, Twiss K C (2007). New light on early caprine herding from isotope analysis: a case study from Neolithic Anatolia. J Archaeol Sci 34:2170-2179

Pourlis A, Chatzis T, Katsoulos P (2014). Comparison of two methods for the measurement of medial and lateral metapodial bones in karagouniko sheep (*Ovis aries*, L. 1758) and Hellenic goat (*Capra hircus*, L. 1758). Anat Res Int 2014:1-5

Prummel W, Frisch H-J 1(986). A guide for the distinction of species, sex, and body size of sheep and goat. J Archaeol Sci 13:567-577

Ropiquet A, Hassanin A (2005). Molecular evidence for the polyphyly of the genus *Hemitragus* (Mammalia, Bovidae). Mol Phylogenet Evol 36:154-68

Rozzi R, Palombo M R (2013). Do methods for predicting paleohabitats apply for mountain and insular fossil bovids? Integr zool 8: 244-259

Rozzi R, Winkler D E, De Vos J, Schulz E, Palombo M R (2013). The enigmatic bovid *Duboisia santeng* (Dubois, 1891) from the Early–Middle Pleistocene of Java: A multiproxy approach to its paleoecology. Palaeogeogr, Palaeoclimatol, Palaeoecol 377:73-85

Schramm Z (1967). Kosci dlugie a wysokosc w klebie u kozy. Roczniki wyzszej szkoly rolniczej w Poznaniu 36:89-105

Serrat M A, Reno P L, McCollum M, Meindl R S, Lovejo C O (2007). Variation in mammalian proximal femoral development: comparative analysis of two distinct ossification patterns. J Anat 210:249-258

Skedros J G, Mason M W, Bloebaum R D (1994). Differences in osteonal micromorphology between tensile and compressive cortices of a bending skeletal system: indications of potential strain-specific differences in bone microstructure. Anat Rec 239:405-413

Skedros J C (2005). Osteocyte lacuna population densities in sheep, elk and horse calcanei. Cells Tissues Organs 181:23-37

Field Code Changed

Skedros J G, Knight A N, Clark G C, Crowder C M, Dominguez V M, Qiu S, Mulhern D M, Donahue S W, Busse B, Hulsey B I,, Zedda M, Sorenson S M (2013). Scaling of Haversian canal surface area to secondary osteon bone volume in ribs and limb bones. Am J Phys Anthropol 151:230-244

Teichert M (1975).Osteometrische Untersuchungen zur Berechnung der Widerristhöhe bei Schafen. In: Clason A T (ed): Archaeozoological studies. American Elsevier, New York, pp 51-69.

von den Driesch A, Wodtke U (1997). The fauna of ’Ain Ghazal, a major PPN and early PM settlement in central Jordan. In: Gebel, H., Kafafi, Z. and Rollefson, G. (eds), The Prehistory of Jordan II. Perspectives From 1997. Ex Orient, Berlin, pp 511-543.

Willerslev E. Cooper A (2005). Ancient DNA. Proceedings of the Royal Society B: Biological Sciences 272:3-16

Zedda M, Lepore G, Manca P, Chisu V, Farina V (2008). Comparative bone histology of adult horses (*Equus caballus*) and cows (*Bos taurus*). Anat Histol Embryol 37:442-445

Zedda M, Lepore G, Biggio G P, Gadau S, Mura E, Farina V (2015). Morphology, morphometry and spatial distribution of secondary osteons in equine femur. Anat Histol Embryol 44:328-332

Zeder M A, Pilaar S E (2009). Assessing the reliability of criteria used to identify mandibles and mandibular teeth of sheep, *Ovis*, and goats, *Capra*. J Archaeol Sci 37:225-242

Zeder M A, Lapham H A (2010). Assessing the reliability of criteria used to identify postcranial bones in sheep, *Ovis*, and goats, *Capra*. J Archaeol Sci 37:2887-2905

Figure captions

Fig. 1 Parameters used for osteometrical measurements. a: goat proximal epiphysis, cranial view, height (1), width (2) of the caput. b: sheep proximal epiphysis, proximal view, length of the caput (1). c: goat distal epiphysis, cranial view, distance between the lips of the trochlea (1), depth of the trochlea (2)

Fig. 2 Protocols followed to define the neck axis and the α and β angles of its inclination. a: sheep proximal epiphysis, caudal view. b: goat proximal epiphysis, proximal view. 1, centre of the best-fit circle along outline of the caput (a, b); 2, centre of the circle around the narrowest part of the neck (a, b); 3, neck axis corresponding to the line connecting the centres of these two circles (a, b); 4, femoral shaft axis (a), plane of the examination table where the condyles were rested (b); 5, α angle formed by the intersection between the shaft axis and the neck axis (a), β angle formed by the intersection between the neck axis and the examination table (b)

Fig. 3 a, c: sheep; b, d: goat. The basic microstructural patterns of bone tissue can be classified in both species as plexiform (a) and irregular Haversian tissue (b). The former consists of primary vascular canals forming a regular, well-defined plexus. The latter is characterized by isolated secondary osteons, generally perpendicular to the primary vascular canals. Secondary osteons are small being formed of 4-5 lamellae and are isolated or rarely clustered together in small groups in both species (c, d). Bar = 120 µm

Fig. 4 The whole bone (medial view) is more curve in goats (a) than sheep (b)

Fig. 5 Proximal epiphysis, caudal view. The caput is as high as the trochanter maior and clearly distinguishable from the fossa trochanterica in goats (a), whereas it is slightly lower in sheep where it gradually passes into the fossa trochanterica (b). The different profile is highlighted by the lines

Fig. 6 Distal epiphysis, cranial view. The trochlea is deeper in goats (a) than in sheep (b), as highlighted by the lines

Figure 1

Click here to download Figure Fig. 1.jpg

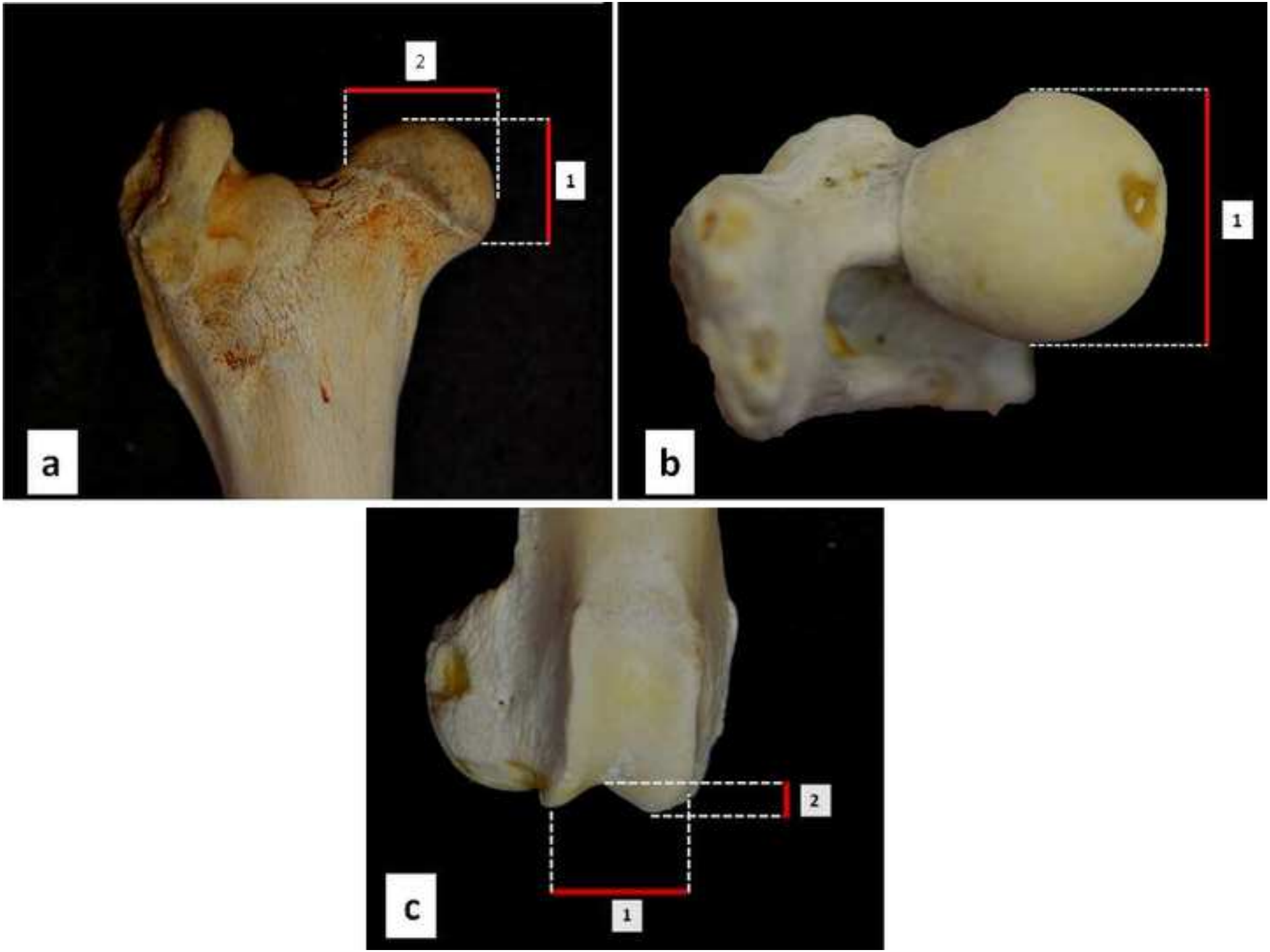

Figure 2

Click here to download Figure Fig. 2.jpg

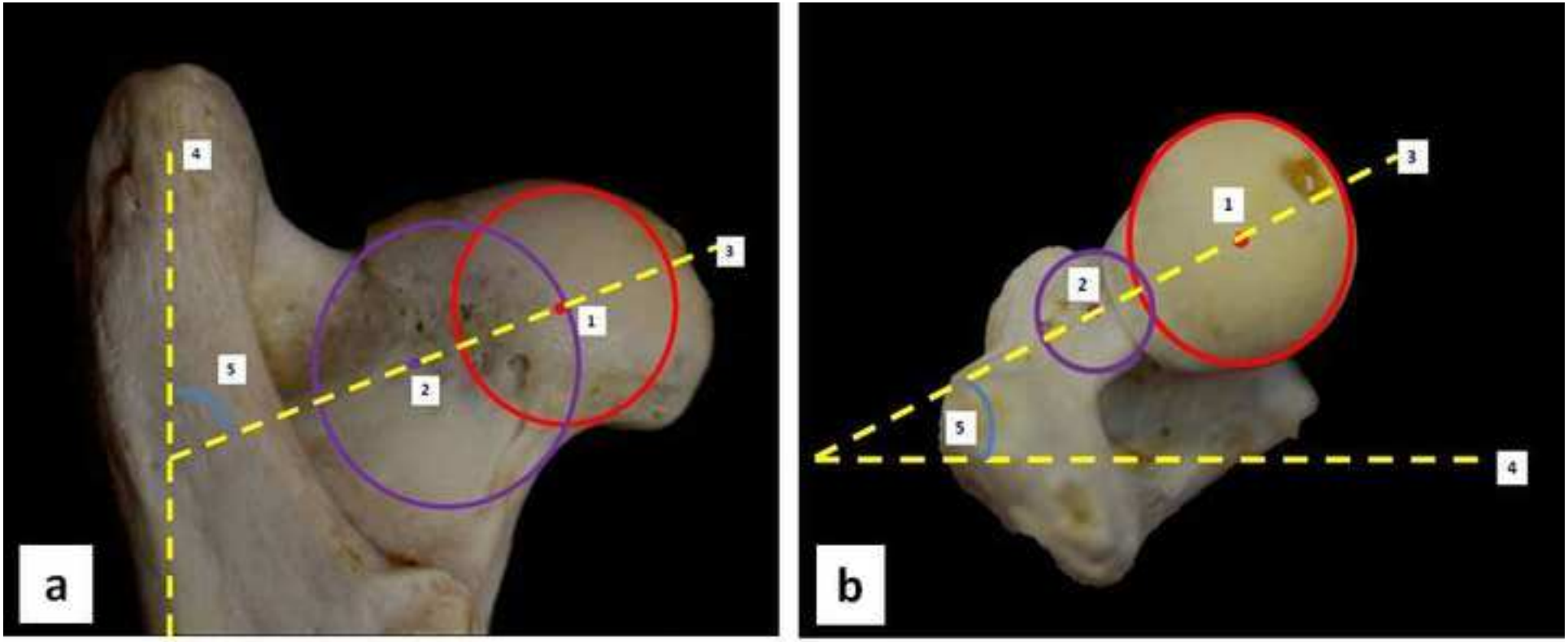

Figure 3

Click here to download Figure Fig. 3.jpg

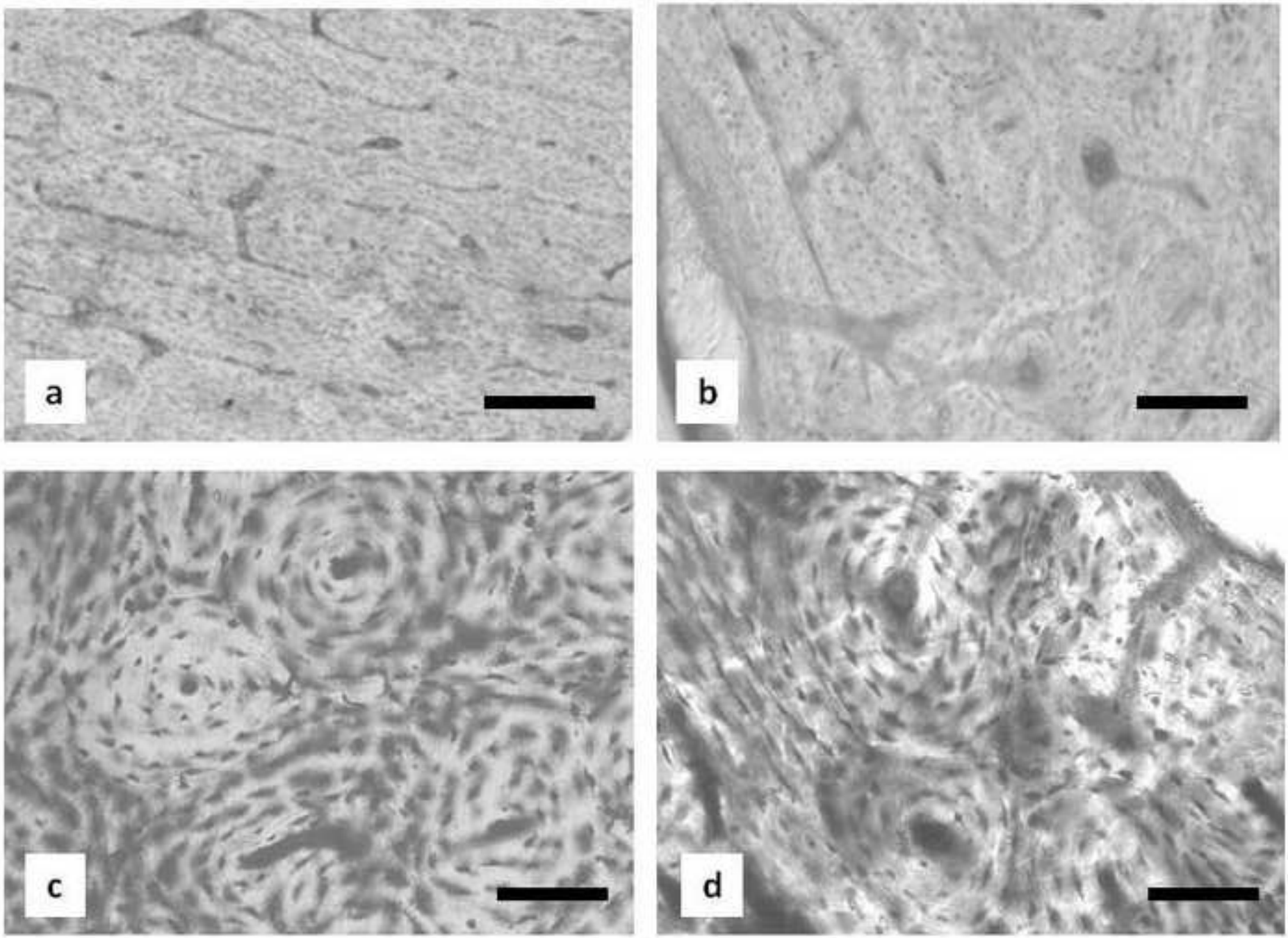

Figure 4

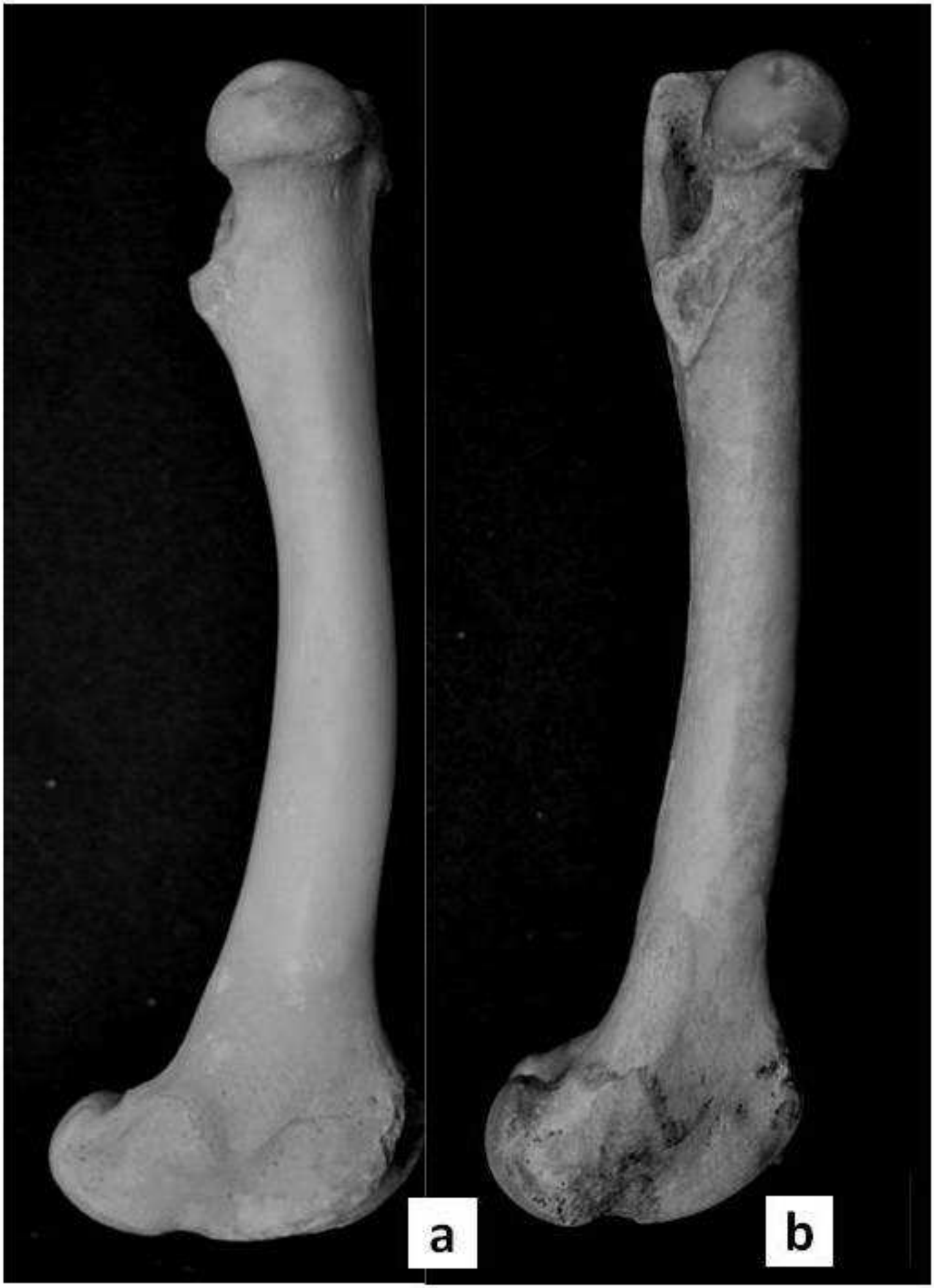

Figure 5

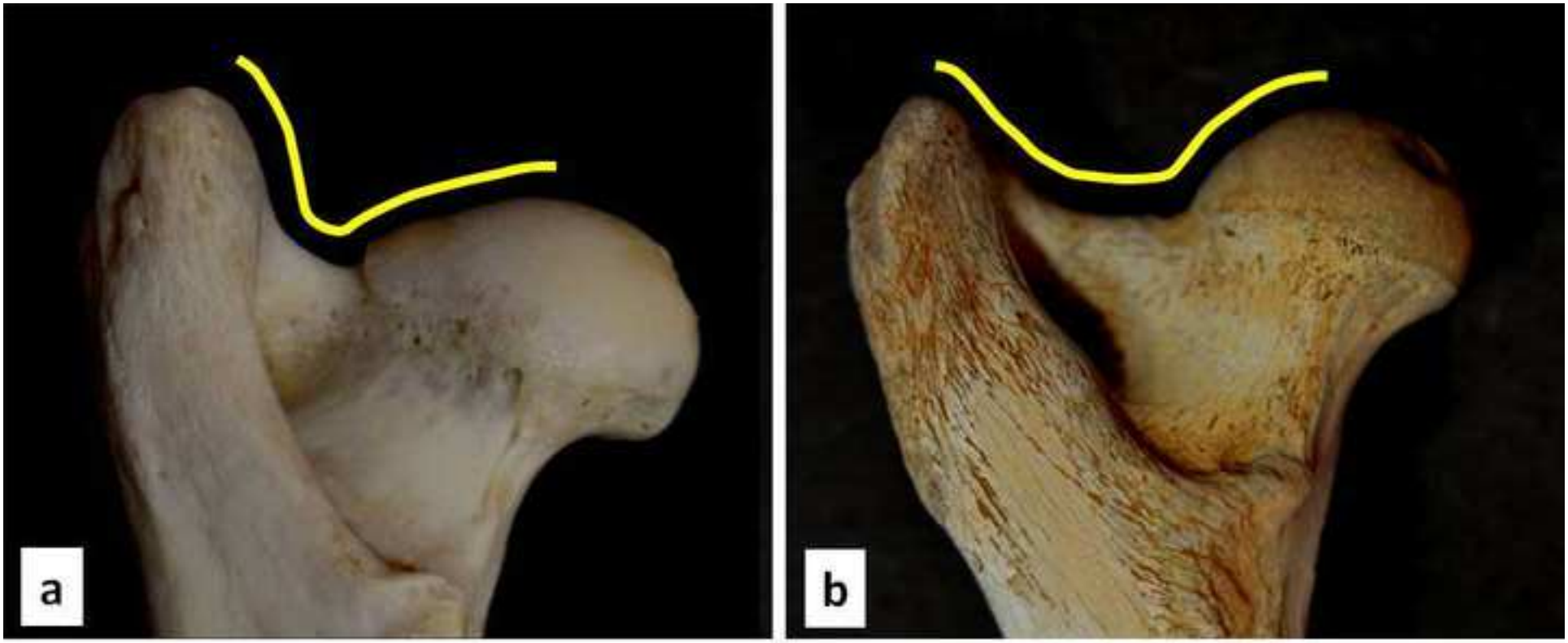

Figure 6

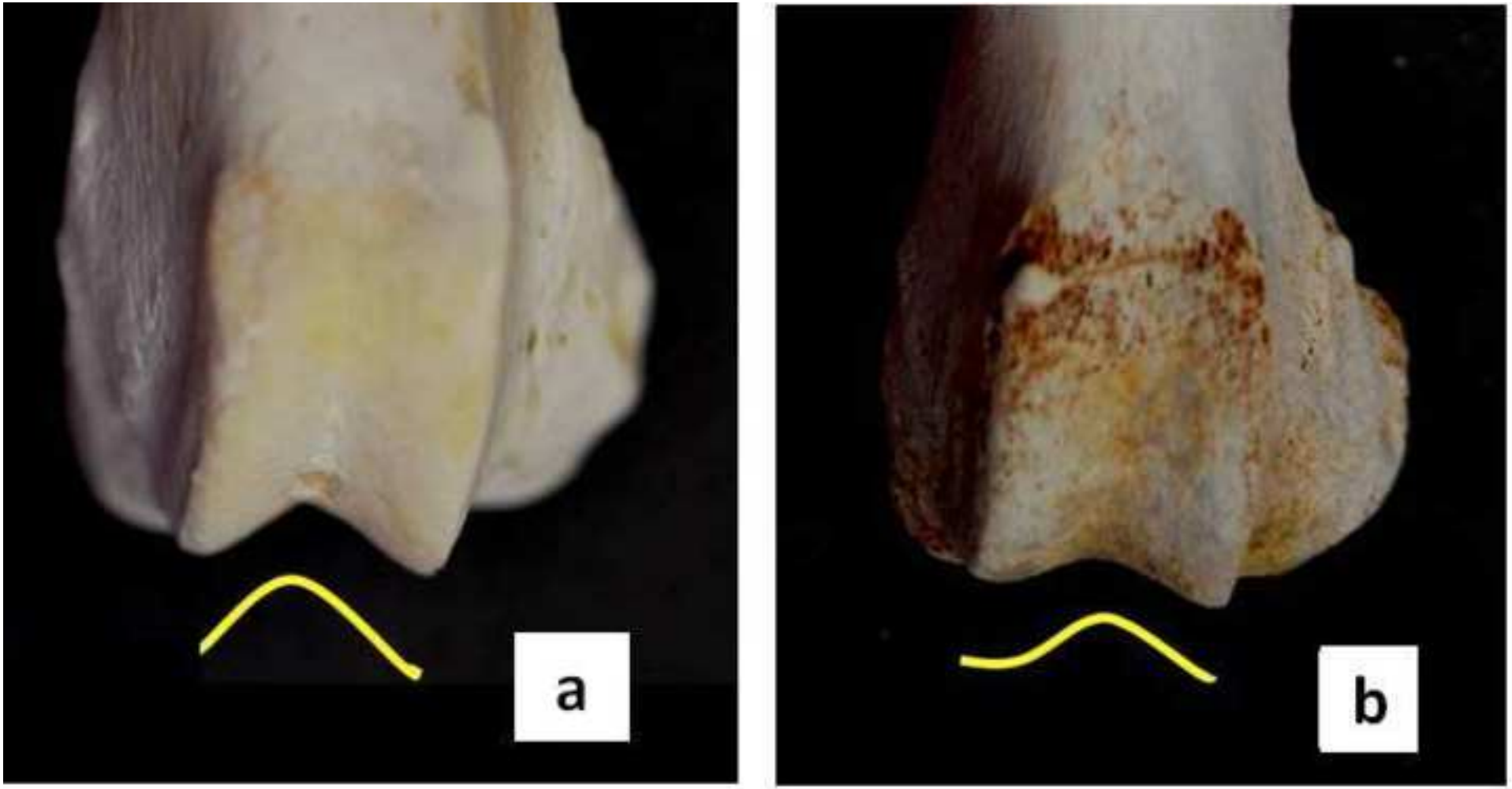

Table 1

	Osteons				Haversian canals			
	minimum diameter (µm)	maximum diameter (µm)	perimeter (µm)	area (μm^2)	minimum diameter (µm)	maximum diameter (µm)	perimeter (µm)	area (μm^2)
Sheep (*Ovis aries*)	135±21	164±29	472±36	17380±1540	22±2	24±3	72±9	414±63
Goat (*Capra hircus*)	129±38	173±41	475±85	16794±1927	24±7	35±8	74±11	408±86

Table 1. Microscopic observations. The most significant differences concern the maximum diameter of secondary osteons and Haversian canals, which are slightly larger in goats than sheep.

Table 2

	Caput ossis femoris				*Inclination of the axis of the collum femoris (α angle)*				*Inclination of the axis of the collum femoris (β angle)*			
	height (mm)	width (mm)	length (mm)	eccentricity	mean value	standard deviation	maximum value	minimum value	mean value	standard deviation	maximum value	minimum value
Sheep (*Ovis aries*)	19 ± 3	21 ± 2	27 ± 4	0.63 ± 0.12	67°	± 5	76°	52°	25°	± 4	32°	19°
Goat (*Capra hircus*)	22 ± 2	24 ± 2	26 ± 3	0.39 ± 0.08	46°	± 4	64°	38°	42°	± 5	52°	28°

Table 2. Macroscopic observations. Measurements of the *caput* indicate that it is more elliptical in sheep. The inclination of the femoral neck is another character that differentiates sheep from goats. Measurements of α angle confirm the morphological observations that the femoral neck is nearly horizontal in sheep, and rather sloped in goats. Values of the β angle indicate that the neck axis is more cranially inclined in goat than in sheep.

Table 3

	Trochlea ossis femoris		
	mean distance between lips (mm)	mean value of maximum depth (mm)	ratio between values of the left columns
Sheep (*Ovis aries*)	15 ± 3	3 ± 2	5.0
Goat (*Capra hircus*)	18 ± 3	6 ± 1	3.2

Table 3. Measurements of the femoral trochlea. The deepness of the trochlea is more marked in goats than in sheep. The ratio between the distance of the trochlear lips and the maximum depth differs for 38% between the two species.

Table 4

Criteria		***Femoral segments***	***Sheep***	***Goat***
a	direction of the axis	whole bone	straighter	slightly curve in a lateral view
b	shape of the caput	proximal epiphysis	more elliptical (eccentricity in proximal view, e = 0.42)	less elliptical (eccentricity in proximal view, e = 0.63)
c	outline of the caput	proximal epiphysis	the head gradually passes into the fossa trochanterica	the head ends abruptly
d	shape of the fovea capitis	proximal epiphysis	circular	with an oval outline
e	inclination of the neck (cranial or caudal view)	proximal epiphysis	nearly horizontal (α angle:67°)	oblique (α angle: 46°)
f	inclination of the neck (proximal view)	proximal epiphysis	minor craniomedial inclination (β angle: 25°)	major craniomedial inclination (β angle: 42°)
g	height of caput and trochanter maior	proximal epiphysis	trochanter maior slightly higher than caput	about the same height
h	distinction of the surfaces	shaft	restricted facies aspera (convex caudal surface)	broad facies aspera (flat caudal surface)
i	nutrient foramen in the proximal part of the cranial surface	shaft	present in 50%	present in 70%
j	nutrient foramen in the distal part of the cranial surface	shaft	present in 50%	present in 30%
k	trochlea	distal epiphysis	less deep	deeper
l	trochlea	distal epiphysis	absence of synovial dimple in 100%	a small synovial dimple is present in 80%

Table 4. Twelve macroscopic diagnostic criteria suitable to a successful distinction between sheep and goat femora are here summarized.

Table 5

	Sheep			Goat			
criteria	**#**	**% correct**	**% wrong**	**#**	**% correct**	**% wrong**	**reliability**
a	10	91.5	8.5	10	90.7	9.3	**
b	10	97.6	2.4	10	98.4	1.6	***
c	10	96.7	3.3	10	96.1	3.9	***
d	10	88.1	11.9	10	82.2	17.8	**
e	10	94.3	5.7	10	95.8	4.2	***
f	10	96.0	4.0	10	94.9	5.1	***
g	10	92.5	7.5	10	92.4	7.6	**
h	10	82.4	17.6	10	78.7	21.3	*
i	10	87.8	12.2	10	88.9	11.1	*
j	10	84.3	15.7	10	72.4	27.6	*
k	10	87.3	12.7	10	94.6	5.4	**
l	10	97.0	3.0	10	94.8	5.2	***
Total	120	91.3	8.7	120	90.0	10.0	**

Table 5. The results of the blind test in the identification of sheep and goat femora are here summarized. The numbers expressed in percentage of correct and wrong answers refer to the mean values from fourteen volunteers. #: number of femora. When the sum of the errors exceeds 30%, the reliability is poor and indicated with one asterisk. When the sum of the errors is between 10% and 30%, the reliability is good and indicated with two asterisks. When the sum of the errors is lower than 10%, the reliability is excellent and indicated with three asterisks. Five criteria (b, c, e, f, l) have this highest degree of reliability.