



UNIVERSITÀ DI PARMA

ARCHIVIO DELLA RICERCA

University of Parma Research Repository

EXIT (Ex utero Intrapartum Treatment) in lymphatic malformations of the head and neck: Discussion of three cases and proposal of an EXIT-TTP (Team Time Procedure) list.

This is the peer reviewed version of the following article:

Original

EXIT (Ex utero Intrapartum Treatment) in lymphatic malformations of the head and neck: Discussion of three cases and proposal of an EXIT-TTP (Team Time Procedure) list / Stefini, S; Bazzana, T; Smussi, C; Piccioni, M; Frusca, Tiziana; Taddei, F; Tomasoni, G; Recupero, D; Cavazza, A; Villani, P; Nicolai, P; Eivazi, B; Wiegand, S; Werner, Ja; Schmidt, S; Maier, Rf; Torossian, A.. - In: INTERNATIONAL JOURNAL OF PEDIATRIC OTORHINOLARYNGOLOGY. - ISSN 1872-8464. - 76:1(2011), pp. 20-27.
[10.1016/j.ijporl.2011.09.015]

Availability:

This version is available at: 11381/2681560 since: 2016-10-06T16:21:35Z

Publisher:

Published

DOI:10.1016/j.ijporl.2011.09.015


Terms of use:

Anyone can freely access the full text of works made available as "Open Access". Works made available

Publisher copyright

note finali coverpage

(Article begins on next page)



EXIT (Ex utero Intrapartum Treatment) in lymphatic malformations of the head and neck: Discussion of three cases and proposal of an EXIT-TTP (Team Time Procedure) list

Stefania Stefini^a, Tullia Bazzana^{a,*}, Cinzia Smussi^a, Michela Piccioni^a, Tiziana Frusca^b, Fabrizio Taddei^b, Gabriele Tomasoni^c, Daniela Recupero^c, Alessandra Cavazza^d, Paolo Villani^d, Piero Nicolai^a, Behfar Eivazi^e, Susanne Wiegand^e, Jochen Alfred Werner^e, Stephan Schmidt^f, Rolf F. Maier^g, Alexander Torossian^h

^a Department of Otorhinolaryngology, University of Brescia – Spedali Civili of Brescia, Italy

^b Department of Maternal-fetal Medicine, University of Brescia – Spedali Civili of Brescia, Italy

^c Department of Anaesthesiology 1, University of Brescia – Spedali Civili of Brescia, Italy

^d Department of Neonatology, University of Brescia – Spedali Civili of Brescia, Italy

^e Department of Otorhinolaryngology, University of Marburg, Germany

^f Department of Obstetrics and Perinatology, University of Marburg, Germany

^g Department of Pediatrics and Neonatology, University of Marburg, Germany

^h Department of Anaesthesiology, University of Marburg, Germany

ARTICLE INFO

Article history:

Received 5 August 2011

Received in revised form 14 September 2011

Accepted 19 September 2011

Available online 10 November 2011

Keywords:

(EXIT) EX-utero Intrapartum Treatment

Fetal airway

Fetal endoscopy

Lymphatic malformation

OK-432

ABSTRACT

Objectives: Ex utero Intrapartum Treatment (EXIT) is a technique to secure the fetal airway while oxygenation is maintained through utero-placental circulation. The aim of the study is to present three cases of fetal lymphatic malformation of the head and neck that required EXIT and to summarize EXIT details.

Methods: The cases were studied before the delivery and EXIT was planned with a multidisciplinary team. The key factors of EXIT are considered and the type, stage and clinical score of the three lymphatic malformations are defined.

Results: In the three cases of EXIT the time working on placental support to secure the airway was 9, 7, and 9 min, respectively (from the hysterotomy to clamping the umbilical cord). Procedures performed on the airway were laryngo-tracheo-bronchoscopy in the first case, laryngoscopy and intubation in the second one, laryngoscopy, drainage of the lymphatic macro-cyst, and intubation in the third case. A sketching to detail the EXIT steps are presented: EXIT-Team Time Procedure list (EXIT-TTP list).

Lymphatic malformations were classified as mixed (micro/macro-cystic) in two cases, and macro-cystic in one. de Serres Stage was IV, V and II. Therapy varied in the three neonates (surgery alone, surgery + Picibanil[®] + Nd-YAG, or Picibanil[®] alone).

Conclusions: In case of prenatal suspicion of airway obstruction, EXIT should be planned with a multidisciplinary team. The EXIT-Team Time Procedure list (EXIT-TTP list), reviews the most critical phases of the procedure when different teams are working together. The type of lymphatic malformation, the anatomic location and the clinical score predict the outcome.

© 2011 Elsevier Ireland Ltd. All rights reserved.

1. Introduction

Large fetal lymphatic malformations (LMs) of the head and neck may present a major challenge to secure the airway at birth. The EX utero Intrapartum Treatment (EXIT) is a controlled technique to

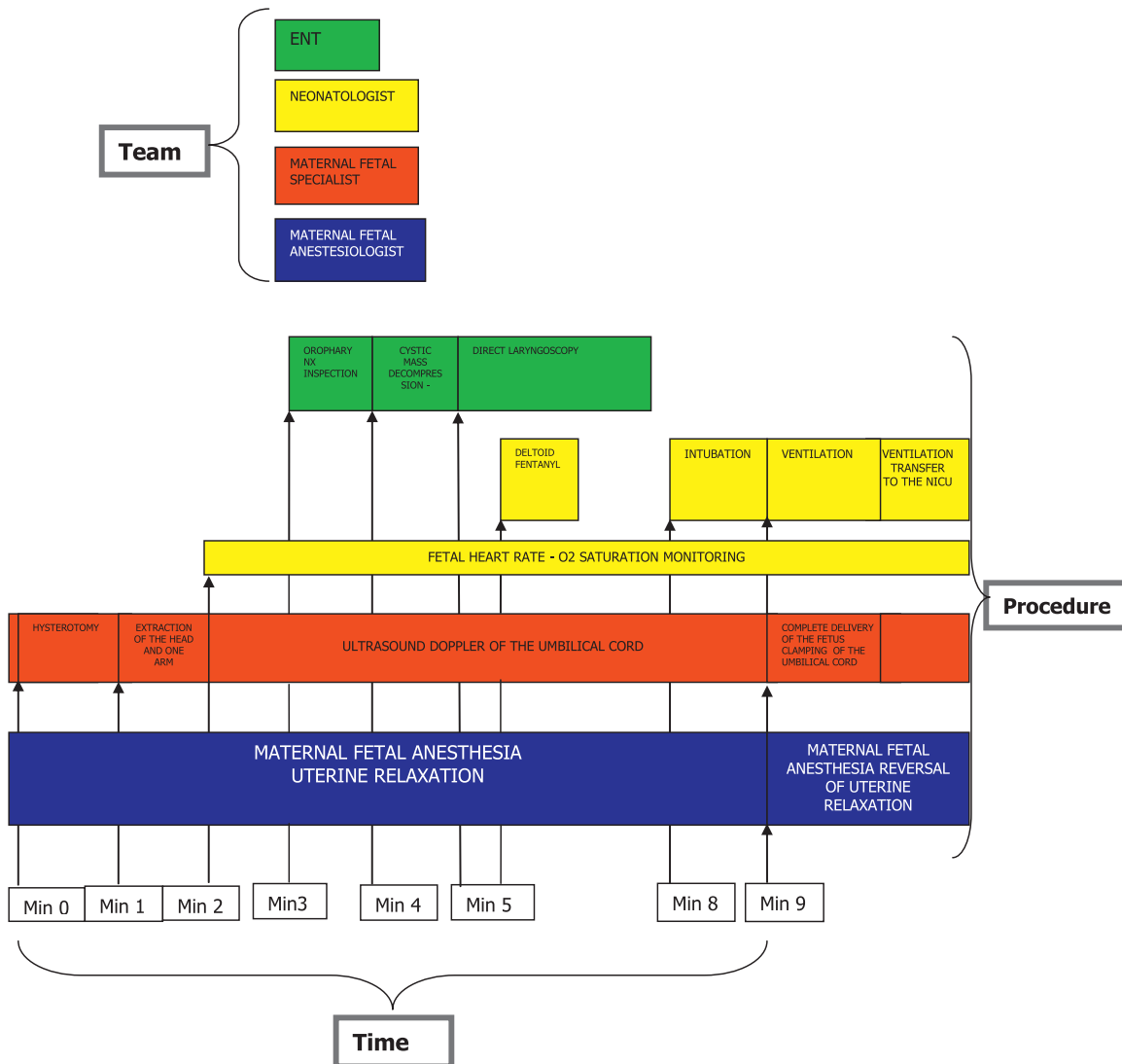
allow partial fetal delivery via modified Cesarean section with subsequent establishment of a safe fetal airway by either intubation, bronchoscopy, or tracheotomy, while fetal oxygenation is maintained through utero-placental circulation [1–3]. The time provided by the EXIT procedure converts an emergency in to a controlled situation [4].

We report three cases of LM of the head and neck that required EXIT: two cases occurred at the Hospital of Marburg (Germany) and one case which occurred about 5 years ago at the Hospital of Brescia (Italy).

* Corresponding author at: Department of Pediatric Otolaryngology – Az. Spedali Civili of Brescia, Italy. Tel.: +39 0303996226; fax: +39 0303996095.

E-mail addresses: tullia@fastwebnet.it, tullia.bazzana@spedalicivili.brescia.it (T. Bazzana).

Table 1
EXIT-TTP list (EXIT-Team Time Procedure list) in the case 3.



We also proposed a list to resume EXIT: the EXIT-TTP (EXIT-Team Time Procedure) list (Table 1).

2. Case 1

The first case was a mixed micro/macro-cystic LM of the neck, floor of the mouth and tongue. Diagnosis was made with prenatal routine ultrasound in a 33 years old mother (3rd para, 2nd gravida) during the otherwise uneventful pregnancy. Obstruction of the airway for displacement of the base of the tongue and the epiglottis was noted in the ultrasound. EXIT procedure to secure the airway was performed at 36th week of pregnancy. The hysterotomy and the partial fetal extraction were made 22 min after induction of the anesthesia. Child’s oxygenation was monitored by pulse oximetry.

Laryngoscopy and rigid tracheoscopy were performed. The oropharynx was narrowed in accordance with previous findings of the ultrasound. No relevant narrowing of the larynx or trachea was evident. The left vallecula appeared edematous. An immediate surgical intervention was not indicated. The child was then completely extracted, umbilical cord was cut and the neonate was given to the neonatologist. The child was under the effect of the maternal anesthesia, therefore without initial spontaneous respiration or movement. The heart rate was stable but over 100 bpm.

The umbilical arterial pH was 7.27. Under mask ventilation with a maximum of 60% oxygen during the first 3–4 min of life a proper breathing began. The Apgar evaluation was in accordance with this description 2/4/8/8 (according 1/3/5/10 min). The birth weight was 2745 g. An approximately 7 × 3.5 cm large fluctuating mass was evident in the neck. Cardiopulmonary was always unremarkable.

Stage according de Serres et al. [5] classification was IV, Cologne Disease Score [6] was 5 (Table 2). Ten days after birth the tumor has been surgically removed. Tracheotomy was not required. The histology confirmed the diagnosis of a lymphatic malformation. The immediate postoperative course was uneventful. The surgery was the only therapy. The child is now 5 years old. The swallow function and speaking ability are normal. Micro-cystic residuals are now evident in the area of the tongue and floor of the mouth. Recurrent swelling conditions are treated with antibiotics. Cologne Disease Score after therapy was 8 (Table 2). Corrective measures are planned in the adolescence.

3. Case 2

The second case was a severe micro/macro-cystic lymphatic malformation of the neck, tongue, pharynx, larynx and thorax.

Diagnosis was made by prenatal ultrasound at the 20th week of gestation in a 23-year-old mother (nullipara). The neck mass measured $6 \times 5 \times 2$ cm at the 24th week and a right sided pleural effusion was also present. Pregnancy was complicated by pyelonephritis at the 30th week. EXIT procedure was indicated because of the massive cystic mass of the neck and was performed at the 36th week of gestation. After hysterotomy child's head was extracted, endoscopy revealed severe obstruction of pharynx and larynx. The child was then intubated on placental support. After the intubation the child was completely extracted, mechanically ventilated and referred to the neonatology intensive care unit. Stage according de Serres et al. [5] classification was V, Cologne Disease Score [6] was 0 (Table 2). Surgical reduction of the cervical mass with tracheotomy was performed eleven days after birth. Laser therapy of the pharyngeal and laryngeal parts was performed in the 6th week after birth. At the age of 3 months a thoracoscopy was performed with Nd:YAG laser treatment of the thoracic parts of the LM. Sclerosing therapy for the cervical parts with Picibanil® (OK-432) was performed in three stages for the cervical (9th, 11th and 14th month) and in one stage for the thoracic parts (15th month). The child died suddenly in the sixteenth month of life with respiratory failure, which was attributed to a fulminant pneumonia.

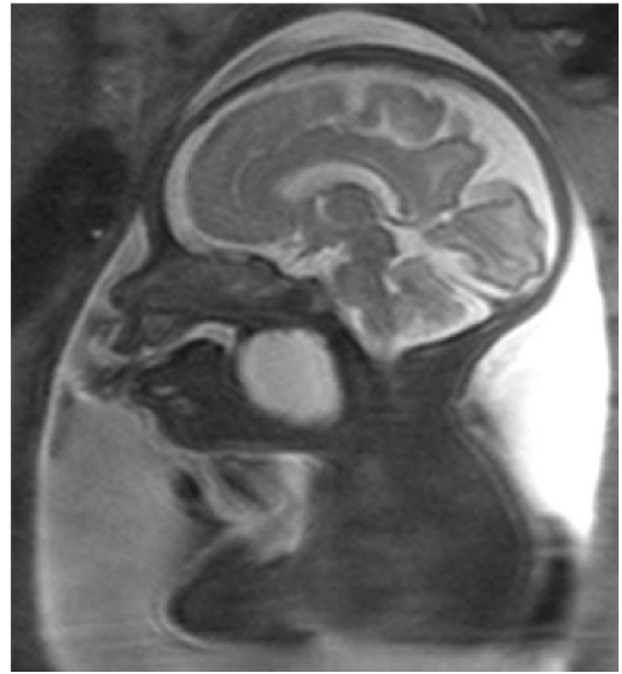


Fig. 2. Case 3 fetal MR at 37th week.

4. Case 3

The third was a case of a fetus with macro-cystic lymphatic malformation of the oropharynx, parapharyngeal space and maxilla. Diagnosis was suspected based on a prenatal routine ultrasound scan performed at 31st week of gestation; polyhydramnios was also present. Complete obstruction of the oropharynx was confirmed by 3D ultrasound and fetal MR done at 37th week (Figs. 1 and 2). An EXIT was proposed and discussed in a multidisciplinary meeting. The map of the OR with mother team-area and baby-team area was drawn (Fig. 3).

The steps and the algorithm of different possibilities following the Pittsburgh Children Hospital flow chart [3] were simulated in the OR the week before birth. Otherwise decompression of the

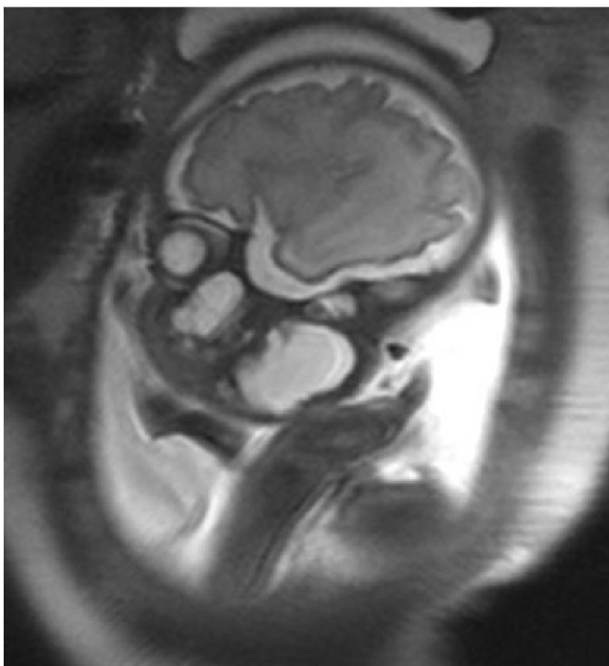


Fig. 1. Case 3 fetal MR at 37th week.

cysts was planned before any attempt of intubation, because of the extent of macrocystic mass at the fetal MR.

Amnioreduction was performed the day before the delivery to avoid the overdistension of the uterus.

All neonatal endoscopic and surgical instruments for managing airway were ready for: oropharynx inspection, intubation, intubation with endoscope, direct laryngoscopy, rigid bronchoscopy, tracheotomy on placental support, emergency tracheotomy without placental support.

A modified Cesarean delivery with EXIT was performed at 38th week of gestation. Utero-placental circulation was maintained to avoid neonatal hypoxemia. The head and the right arm of the fetus were extracted (Fig. 4). Doppler ultrasound of the umbilical cord was used to control the blood supply to the fetus. At the inspection of the oropharynx the ENT found that it was completely obstructed by the mass. Decompression of the cyst, which was already considered looking at the fetal MR, was performed by aspirating 40 cc of liquid from the mass (Fig. 5). At this point, direct laryngoscopy was possible and glottis was visualized. Fentanyl administration to the fetus in the deltoid was necessary because of some movement during laryngoscopy. Nasotracheal intubation was performed by the neonatologist with a tube size of 2.5 mm in inner diameter. The umbilical cord was clamped and uterine relaxation reversed. The newborn was ventilated and transferred to the neonatal intensive care unit. The whole procedure on placental support from the hysterotomy to the intubation and clamping of the umbilical cord lasted 9 min as summarized in the "EXIT-Team Time Procedure" list (EXIT-TTP list) (Table 1).

The newborn weight was 2700 g. Umbilical cord blood pH was 7.17 (pCO₂ 53, pO₂ 65, HCO₃ 20, BE-8). O₂ saturation at birth was 85%. Mother blood loss was of 700 cc.

MR performed after birth (Figs. 6 and 7) showed an increase in the volume of the macro-cystic mass with two components (maxillary and parapharyngeal). There was a compression and dislocation of the right eye (Fig. 8). It was a de Serres type II lymphatic malformation (unilateral and suprahyoid) [5].

Cologne Disease Score [6], modified by Wiegand et al. [7], was 2 with one point for disfigurement and one point for impairment of the right eye movement; all the other items were zero (Table 2). At

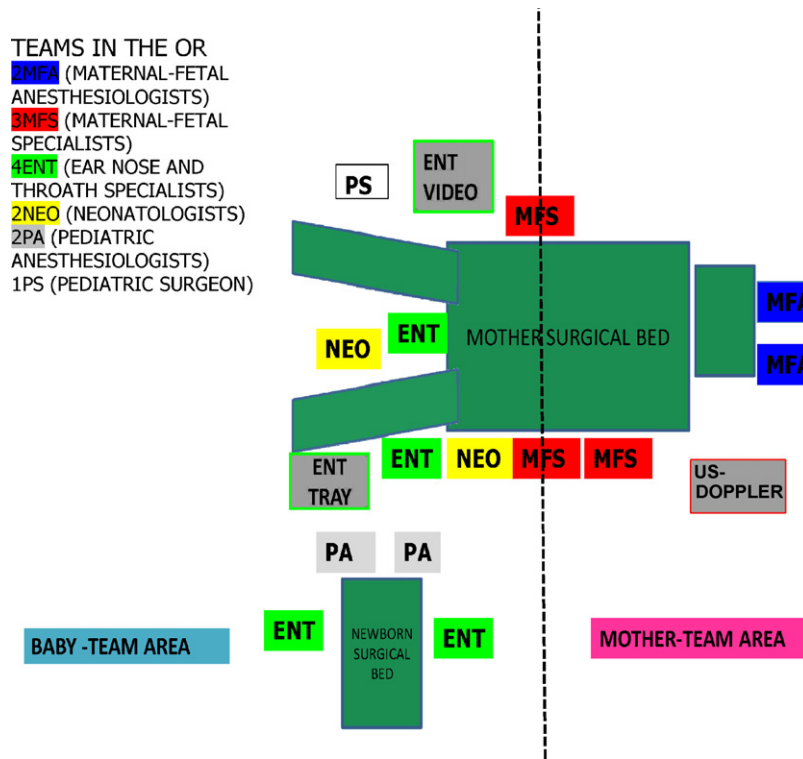


Fig. 3. The OR MAP in the case 3.

7th day of life a first injection of Picibanil[®] according to Ogita protocol [8] and pharmaceutical indications was done.

At 28 days of life there was still some increase of the mass; tracheotomy and a second infiltration with Picibanil[®] were performed and were followed by 3 other ultrasound guided infiltrations at about 1 month of interval.

After the second infiltration the mass progressively shrunk. The MR performed at 5 months of life (Figs. 9 and 10) showed a substantial reduction in volume of the mass, with improvement in sucking, swallowing and breathing. At 5 months of age tracheotomy tube has been removed and the patient was eating per os, he recovered the motion of the right eye but he still had some degree of protrusion of the tongue (Fig. 11). At 18 month, there was only a

minimal asymmetry of the cheek (Fig. 12). From modified Cologne Disease Score of 2/11 he became at score 10/11 with normal eye motion (Table 2). The baby is now 5 years old and he has a small residual disease in the right premaxilla of 8 mm under ultrasound follow-up.

5. Discussion

Management of fetal airway obstruction has been radically improved by advances in prenatal diagnosis. Actually, fetal US and MR can identify head and neck masses with airway obstruction several weeks before birth. The Otolaryngologist is therefore asked to perform fetal endoscopy and fetal surgery on placental support during EX-utero Intrapartum Treatment [9].

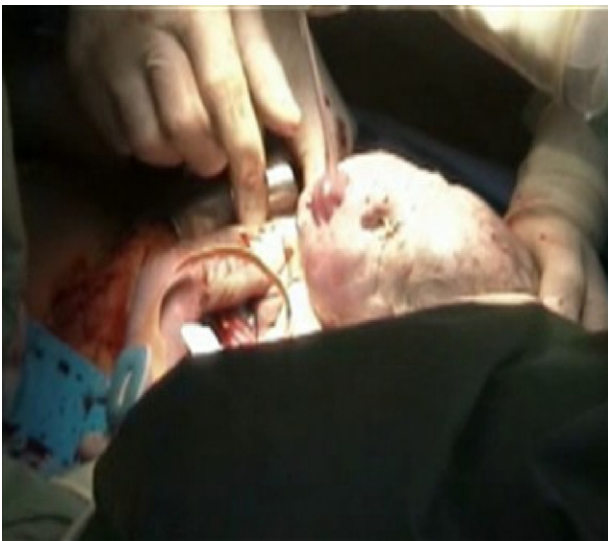

Fig. 4. Case 3 EXIT: delivery of the head and right arm.

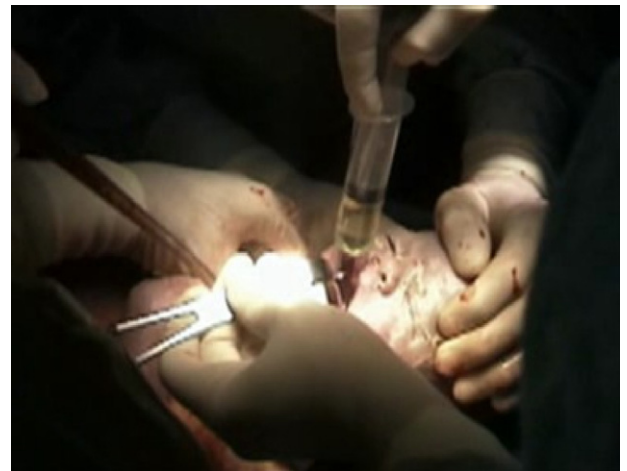

Fig. 5. Case 3 EXIT: laryngoscopy, decompression of the mass and endotracheal intubation were performed on the fetus partially delivered.

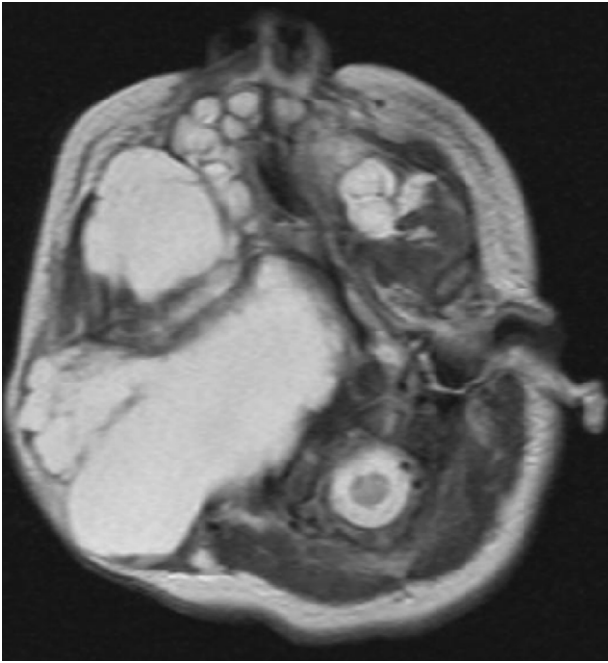


Fig. 6. Case 3 MR after birth.

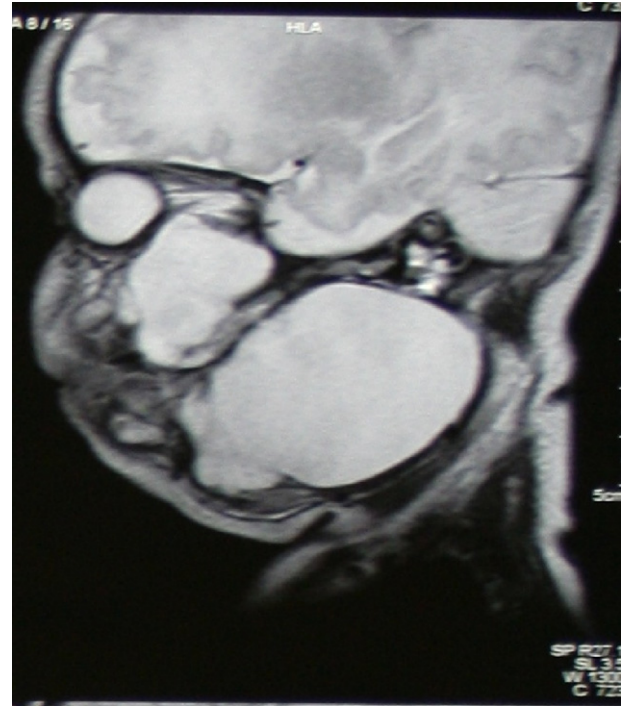

Fig. 8. Case 3 MR after birth.

LM and teratomas are the most frequent head and neck masses that can compromise airways at birth [10].

If allowed to deliver in the standard fashion, overall infant mortality rate is estimated at 20% [11]. From the literature in 27 cases of EXIT for LM, tracheotomy was performed in 4 cases (15%). LM are more compressible than teratomas, that have about 40% of tracheotomy rate reported. LM seems also to be associated with a lower mortality rate (11% versus 17%) [1,9–18].

EXIT is a multistep technique to secure airway when compromised by head and neck masses. The procedure was first

described by Schwartz et al. [19]; Skarsgard et al. [13] called the technique OOPS (Operating On Placental Support); subsequently procedural guidelines and EXIT acronym were proposed by Mychaliska et al. [1].

During EXIT the patient is still « unborn » in the sense that the procedure is performed before breathing, with the fetus partially delivered (only the head and one arm extracted) and with oxygen supply by utero-placental circulation.

The key factors of EXIT are team, time and procedure.

EXIT is a multidisciplinary procedure [20], more than three teams were present in the OR in the cases presented. The steps may be variably combined, some teams were working on both mother and fetus:

- Maternal-Fetal Anesthesiologist team
- Maternal-Fetal Specialist team.

The other specialists were working on the fetus only:

- Neonatologist team (with neonatal intensivists with experience in intubation and resuscitation, working in Neonatal Intensive Care Unit)
- Otolaryngologist team.

The OR map should be studied in details with a mother-team-area and a baby-team-area with simulation of the procedure [12,21,22].

In 1997 Liechty et al. reported in a table the essential data of 5 cases of EXIT: time working on placental support (28 ± 22 min) and procedures performed [23].

Bouchard et al. in 2002 [24] summarized in a table the time working on placental support for different pathology requiring EXIT (29.2 ± 16.4 min). Hirose et al. [10] reported an average operating time “on placental support” (from hysterotomy to clamping of the umbilical cord) of 45 ± 25 min with a maximum time reported of 150 min.

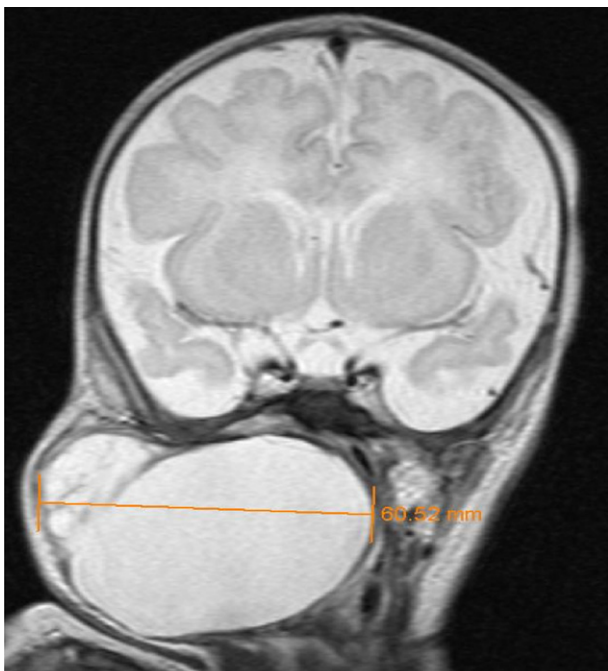

Fig. 7. Case 3 MR after birth.

Table 2
Staging and therapy of the three cases.

	Gender	Gestational age at EXIT	Site	Type	Exit time	Stage (de Serres [5])	CDS 0–10	Therapy	CDS after therapy
Case 1	F	36w	Neck, floor of the mouth	Mixed micro- and macro-cystic	9 min	IV	5/10	Surgical resection	8/10
Case 2	M	35w	Bilateral neck, pharynx, larynx, thorax	Mixed micro- and macro-cystic	7 min	V	0/10	Tracheotomy, Surgical resection, OK 432, Nd:YAG laser	0/10 Fatal at 16 months
Case 3	M	38w	Oropharynx Parapharynx + maxilla right orbit	Macro-cystic	9 min	II	CDSM 2/11	Tracheotomy OK-432	CDSM 10/11

EXIT time: from hysterotomy to the umbilical cord clamping.

CDS: Cologne Disease Score [6].

CDSM: Cologne Disease Score modified for eye involvement [7].

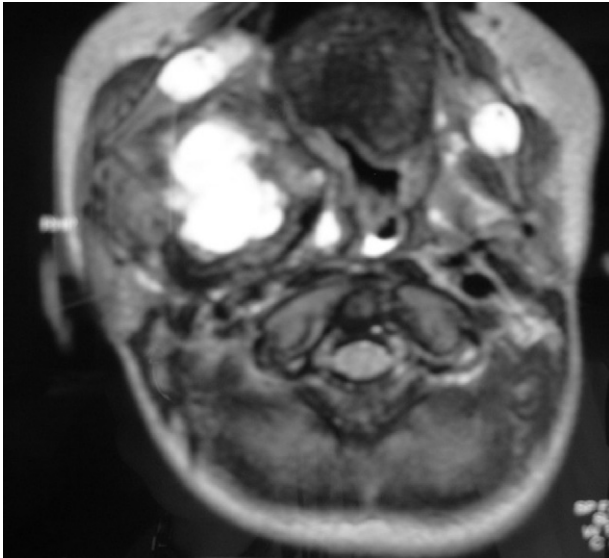


Fig. 9. Case 3 MR at 5 month of age.

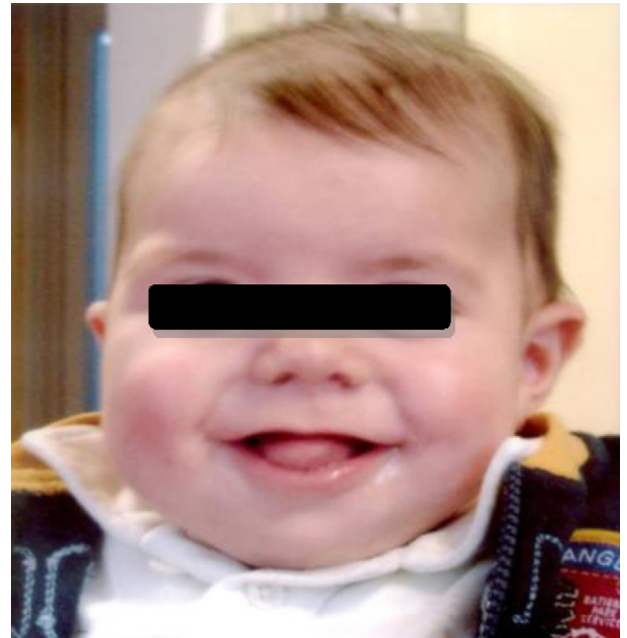


Fig. 11. Case 3 at 5 months of age.

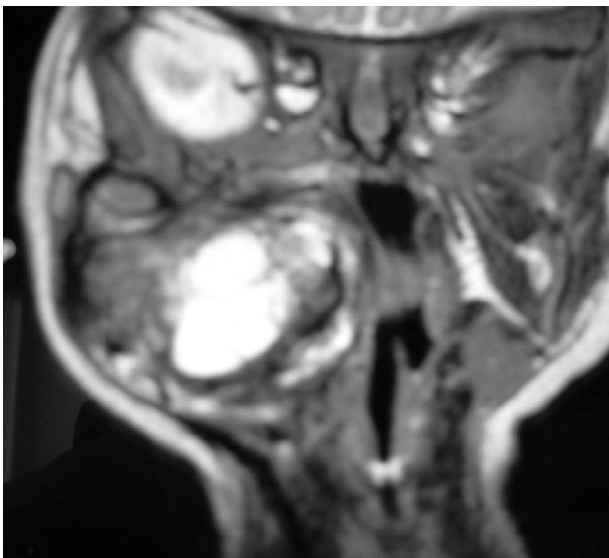


Fig. 10. Case 3 MR at 5 month of age.

Procedures on both the mother and fetus are performed by Maternal-Fetal Anesthesiologists team and by Maternal-Fetal Specialists team.

Maternal-Fetal Anesthesiologists team should obtain uterine relaxation to facilitate the delivery of the fetal head and arm with

minimum compromise of placental support. Fetal transplacental anesthesia provides fetal sedation and avoids the first inspiration at the head extraction. Uterine relaxation increases the risk of important uterine haemorrhage, so that the stability of the mother can influence subsequent steps [2,3,12]. The possibility of immediate reversion of uterine relaxation (with oxytocic medication) should always be kept in mind and not only at the end of the procedure [3]. Maternal-Fetal Specialists team is involved in ultrasound placental mapping to avoid placental damage, low transversal hysterotomy, delivery of the fetal head and one arm only, because if the entire fetus is extracted uterine contraction reduces gas exchange and can promote delivery of the placenta [2,12]. Ultrasound Doppler of the umbilical cord may also give information on fetus oxygenation [10]. At the end of the EXIT the umbilical cord is clamped and the placenta removed. The Procedures on the fetus are usually performed by Neonatologists, Otolaryngologists, Pediatric Surgeons and Pediatric Anesthesiologists.

Neonatologists team is involved in O₂ and heart rate monitor, intramuscular (deltoid) administration of medications, intubation, resuscitation. The Otolaryngologic team is expected to secure the airway.

Two useful algorithms have been proposed in the literature to anticipate the sequence of possible procedures that the team could adopt during EXIT to secure the airway for neck masses [3,25]. The

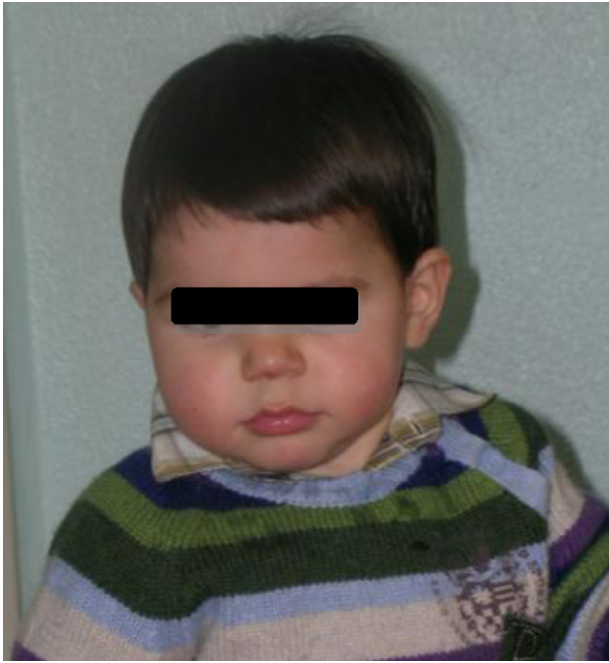

Fig. 12. Case 3 at 18 month of age.

algorithm developed at the Fetal Care center of Cincinnati Children's Hospital Medical Center includes direct laryngoscopy with intubation, flexible or rigid bronchoscopy and intubation with armored endotracheal tube over the endoscope, retrograde intubation over endotracheal tube exchanger inserted through a tracheotomy (Seldinger technique), elevation of the mass off the airway and release of the strap muscles. If the latter surgical maneuver does not allow a proper exposure of the airway, reflection of the mass off the airway or even resection of the mass followed by formal surgical tracheotomy is recommended [25].

In the algorithm from the Children's Hospital of Pittsburgh the steps reported to secure the airway are direct laryngoscopy, bronchoscopy, tracheotomy over the bronchoscope with or without placental support, decompression of the mass, excision of the neck mass and tracheotomy on placental support or emergency tracheotomy without placental support, when the mother is not stable [3].

Pediatric Surgeons are team of EXIT procedure depending on cases and Institutions [3,4,15,16,23–25]. Pediatric Anesthesiologists may be involved in neonatal general anesthesia [12].

The third case of EXIT presented has been summarized in an original list (called EXIT-TTP list) to better clarify the teams involved, the time working "on placental support" and the procedures performed. From the minute 3 to the minute 8 there was a critical phase when four different teams of specialists were working together (Table 1).

Management of LM and comparison of cases require an accurate staging. Different sites of the head and neck involved by LM are considered in de Serres et al. classification (Stage I unilateral infrahyoid, Stage II unilateral suprahyoid, Stage III unilateral suprahyoid and infrahyoid, Stage IV bilateral suprahyoid and infrahyoid, Stage V bilateral infrahyoid) [5]. The severity of symptoms due to the LM of the head and neck, are considered in the Cologne Disease Score and modified Cologne Disease Score [6,7]. Items evaluated (from 0 to 2 points for each item) are respiration, nutrition, speech, cosmetic appearance, progression [6] and eye movement [7]. A maximum score of 10 (for Cologne Disease Score) or 11 (for Cologne Disease Score modified) is obtained if all items are normal and with improvement of the disease [6,7], zero point is the minimum score [6]. de Serres staging

and Cologne Disease Score are useful to predict the outcome [5–7] and to compare the results of treatment [6,7].

The different types of LM macro-cystic, micro-cystic or mixed require tailored therapy (OK-432 immunotherapy, surgery or even bleomycin infiltration in selected cases) [26]. Treatment of unresectable LM is still controversial, but immunotherapy with OK-432 in macro-cystic lesions is today considered the therapy of choice [26].

6. Conclusions

In case of fetal LM of the neck with prenatal suspicion of airway obstruction, EXIT to secure the airway should be planned with a multidisciplinary team. A map of the OR and simulation before the EXIT improve the coordination between different specialists. Airway algorithm anticipates the sequence of the procedures to secure fetal airway during EXIT.

The EXIT-TTP list proposed can be useful to review cases of EXIT and to emphasize the most critical phases of the procedure when several teams are working together.

References

- [1] G.B. Mychaliska, J.F. Bealer, J.L. Graf, M.A. Rosen, N.S. Adzick, M.R. Harrison, Operating on placental support: the Ex utero Intrapartum Treatment procedure, *J. Pediatr. Surg.* 32 (1997) 227–230.
- [2] D.A. Schwartz, K.P. Moriarty, D.B. Tashjian, R.S. Wool, R.K. Parker, G.R. Markenson, et al., Anesthetic Management of the EXIT (Ex utero Intrapartum Treatment) Procedure, *J. Clin. Anesth.* 13 (2001) 387–391.
- [3] T.D. Otteson, D.J. Hackam, D.L. Mandell, The Ex utero Intrapartum Treatment (EXIT) procedure. New challenges, *Arch. Otolaryngol. Head Neck Surg.* 132 (2006) 686–689.
- [4] K.W. Liechty, Ex-utero intrapartum therapy, *Semin. Fetal Neonat. Med.* 15 (1) (2010) 34–39.
- [5] L.M. de Serres, K.C. Sie, M.A. Richardson, Lymphatic malformations of the head and neck. A proposal for staging, *Arch. Otolaryngol. Head Neck Surg.* 121 (1995) 577–582.
- [6] C. Wittekindt, O. Michel, M. Streppel, B. Roth, G. Quante, D. Beutner, et al., Lymphatic malformations of the head and neck: introduction of a disease score for children Cologne Disease Score (CDS), *Int. J. Pediatr. Otorhinolaryngol.* 70 (2006) 1205–1212.
- [7] S. Wiegand, B. Eivazi, A.P. Zimmermann, A.M. Sesterhenn, J.A. Werner, Evaluation of children with lymphatic malformations of the head and neck using the Cologne Disease Score, *Int. J. Pediatr. Otorhinolaryngol.* 73 (2009) 955–958.
- [8] S. Ogita, T. Tsuto, K. Nakamura, E. Deguchi, N. Iwai, OK-432 therapy in 64 patients with lymphangioma, *J. Pediatr. Surg.* 29 (1994) 784–785.
- [9] R. Rahbar, A. Vogel, L.B. Myers, L. Bulich, L. Wilkins-Haug, C.B. Benson, et al., Fetal surgery in Otolaryngology. A new Era in the diagnosis and management of fetal airway obstruction because of advances in prenatal imaging, *Arch. Otolaryngol. Head Neck Surg.* 131 (2005) 393–398.
- [10] S. Hirose, D.L. Farmer, H. Lee, K.K. Nobuhara, M.R. Harrison, The ex utero intrapartum treatment procedure: looking back at the EXIT, *J. Pediatr. Surg.* 39 (2004) 375–380.
- [11] M. Tanaka, S. Sato, H. Naito, H. Nakayama, Anaesthetic management of a neonate with prenatally diagnosed cervical tumour and upper airway obstruction, *Can. J. Anaesth.* 41 (1994) 236–240.
- [12] A.-S. Ducloy-Bouthors, B. Marciniak, P. Vaast, P. Fayoux, V. Houfflin-Debarge, A. Fily, et al., Anesthésie maternofoetale pour "ex utero intrapartum" traitement (EXIT) procedure: à propos de deux cas, *Ann. Fr. Anesth. Reanim.* 25 (2006) 638–643.
- [13] E.D. Skarsgard, U. Chitkara, E.J. Krane, E.T. Riley, L.P. Halamek, H.H. Dedo, The OOPS procedure (operation on placental support): in utero airway management of the fetus with prenatally diagnosed tracheal obstruction, *J. Pediatr. Surg.* 31 (1996) 826–828.
- [14] D.A. Preciado, M.J. Rutter, J.M. Greenberg, R. Bahado-Singh, D. Lambers, J.P. Willing, Intrapartum management of severe fetal airway obstruction, *J. Otolaryngol.* 33 (2004) 283–288.
- [15] K.W. Liechty, H.L. Hedrick, A.M. Hubbard, M.P. Johnson, R.D. Wilson, E.D. Ruchelli, et al., Severe pulmonary hypoplasia associated with giant cervical teratomas, *J. Pediatr. Surg.* 41 (2006) 230–233.
- [16] E. Leva, L. Pansini, G. Fava, L. Maestri, A. Pansini, G. Selvaggio, the role of surgeon in the case of a giant neck mass in the EXIT procedure, *J. Pediatr. Surg.* 40 (2005) 748–750.
- [17] M. Pellicer, F. Pumarola, J.L. Peiró, V.M. Ibanez, J.A.G. Vaquero, E. Carreras, et al., Procedimiento EXIT en el manejo de fetos con severo compromiso respiratorio. La perspectiva del otorrinolaringólogo pediátrico, *Acta Otorrinolaringol. Esp.* 58 (10) (2007) 487–490.
- [18] N. Johnson, P.S. Shah, P. Shannon, P. Campisi, R. Windrim, A challenging delivery by EXIT procedure of a fetus with a giant cervical teratoma, *J. Obstet. Gynaecol. Can.* 31 (3) (2009) 267–271.

- [19] D.A. Schwartz, H. Silver, S. Schulman, Maintenance of the placental circulation to evaluate and treat an infant with massive head and neck hemangioma, *J. Pediatr. Surg.* 28 (1993) 520–522.
- [20] B. Eivazi, M. Ardelean, W. Baumler, H.-P. Berlien, H. Cremer, R. Elluru, et al., Update on hemangiomas and vascular malformations of the head and neck, *Eur. Arch. Otorhinolaryngol.* 266 (2009) 187–197.
- [21] G.M. Chu, V. Yue, V. Abdullah, H.B. Chan, W.K. To, M.Y. Chan, et al., Ex-utero Intrapartum Treatment: a controlled approach to the management of anticipated airway problems in the newborn, *Hong Kong Med. J.* 12 (5) (2006) 381–384.
- [22] T.C. Auguste, J.A. Boswick, M.K. Loyd, A. Battista, The simulation of an ex utero intrapartum procedure to extracorporeal membrane oxygenation, *J. Pediatr. Surg.* 46 (2011) 395–398.
- [23] K.W. Liechty, T.M. Crombleholme, A.W. Flake, M.A. Morgan, C.D. Kurth, A.M. Hubbard, et al., Intrapartum airway management for giant fetal neck masses: The EXIT (Ex utero Intrapartum Treatment procedure), *Am. J. Obstet. Gynecol.* 177 (1997) 870–874.
- [24] S. Bouchard, M.P. Johnson, A.W. Flake, L.J. Howell, L.B. Myers, N.S. Adzick, et al., The EXIT procedure: experience and outcome in 31 cases, *J. Pediatr. Surg.* 37 (2002) 418–426.
- [25] A. Marvan, T.M. Crombleholme, The EXIT procedure: principles, pitfalls and progress, *Semin. Pediatr. Surg.* 15 (2006) 107–115.
- [26] M.C. Smith, M.B. Zimmerman, D.K. Burke, N.M. Bauman, Y. Sato, R.J.H. Smith, et al., Efficacy and safety of OK-432, *Laryngoscope* 119 (2009) 107–115.